Unusual Presentations of Pulmonary Sarcoidosis: Cases from the Medical University of South Carolina

Marc A. Judson, M.D.,[1] Brad Vincent, M.D.,[1] Terrill Huggins, M.D.,[1] Gerard A. Silvestri, M.D.,[1] and Steven A. Sahn, M.D.[1]

ABSTRACT

Sarcoidosis is a multisystem granulomatous disease that can affect any organ in the body, but most commonly the lung. Any part of the thorax may be affected by sarcoidosis, including the lung parenchyma, airways, and mediastinal and hilar lymph nodes. When the parenchyma is involved, sarcoidosis has a predilection for the bronchovascular bundles and subpleural locations.

On occasion, the presentation of pulmonary sarcoidosis may be atypical. Atypical presentations may result in a delay in diagnosis as well as unnecessary treatment or diagnostic testing. We discuss four patients with an unusual presentation of thoracic sarcoidosis seen at our Sarcoidosis Clinic.

KEYWORDS: Sarcoidosis, granuloma, diagnosis, emphysema, vasculitis, emphysema pulmonary nodule, pleural effusion

CASE 1 PRESENTATION

A 37-year-old Filipina presented with a 1 year history of intermittent fever, fatigue, night sweats, and weight loss of 60 pounds. She had a positive tuberculin skin test 10 years previously. Although she supposedly had only evidence of latent tuberculosis infection, she was treated with isoniazid and rifampin that was subsequently changed to ethambutol and rifampin because of an isoniazid allergy. She reported a history of histoplasmosis 15 years previously, while living near a chicken coop. She also had a history of "iritis" at age 28.

Her local physician prescribed antibiotics without improvement in her symptoms. A chest radiograph was "abnormal." Subsequently, a chest computed tomographic (CT) scan revealed a thick-walled cavitary lesion in the right lower lobe. Stains and cultures of expectorated sputum were negative for mycobacteria and fungi. Bronchoscopy with bronchial washings and transbronchial lung biopsy did not reveal a mycobacterial or fungal pathogen by stain or culture.

Because of a negative evaluation and continuing symptoms, she underwent a thoracoscopic resection of the cavitary lesion. The lesion demonstrated caseating granulomatous inflammation (Fig. 1A,B) with multinucleated giant cells (Fig. 1C). An elastin stain revealed that the granulomatous inflammation was perivascular (Fig. 1D). Stains and cultures for mycobacteria and fungi were negative.

The patient was empirically treated for tuberculosis and also given clarithromycin and cefixime

[1]Division of Pulmonary and Critical Care Medicine, Medical University of South Carolina, Charleston, South Carolina.

Address for correspondence and reprint requests: Marc A. Judson, M.D., Division of Pulmonary and Critical Care Medicine, CSB-812, 96 Jonathan Lucas St., Medical University of South Carolina, Charleston, SC 29425. E-mail: judsonma@musc.edu.

Sarcoidosis: Evolving Concepts and Controversies; Guest Editors, Marc A. Judson, M.D., Michael C. Iannuzzi, M.D.

Semin Respir Crit Care Med 2007;28:75–82. Copyright © 2007 by Thieme Medical Publishers, Inc., 333 Seventh Avenue, New York, NY 10001, USA. Tel: +1(212) 584-4662.
DOI 10.1055/s-2007-970334. ISSN 1069-3424.

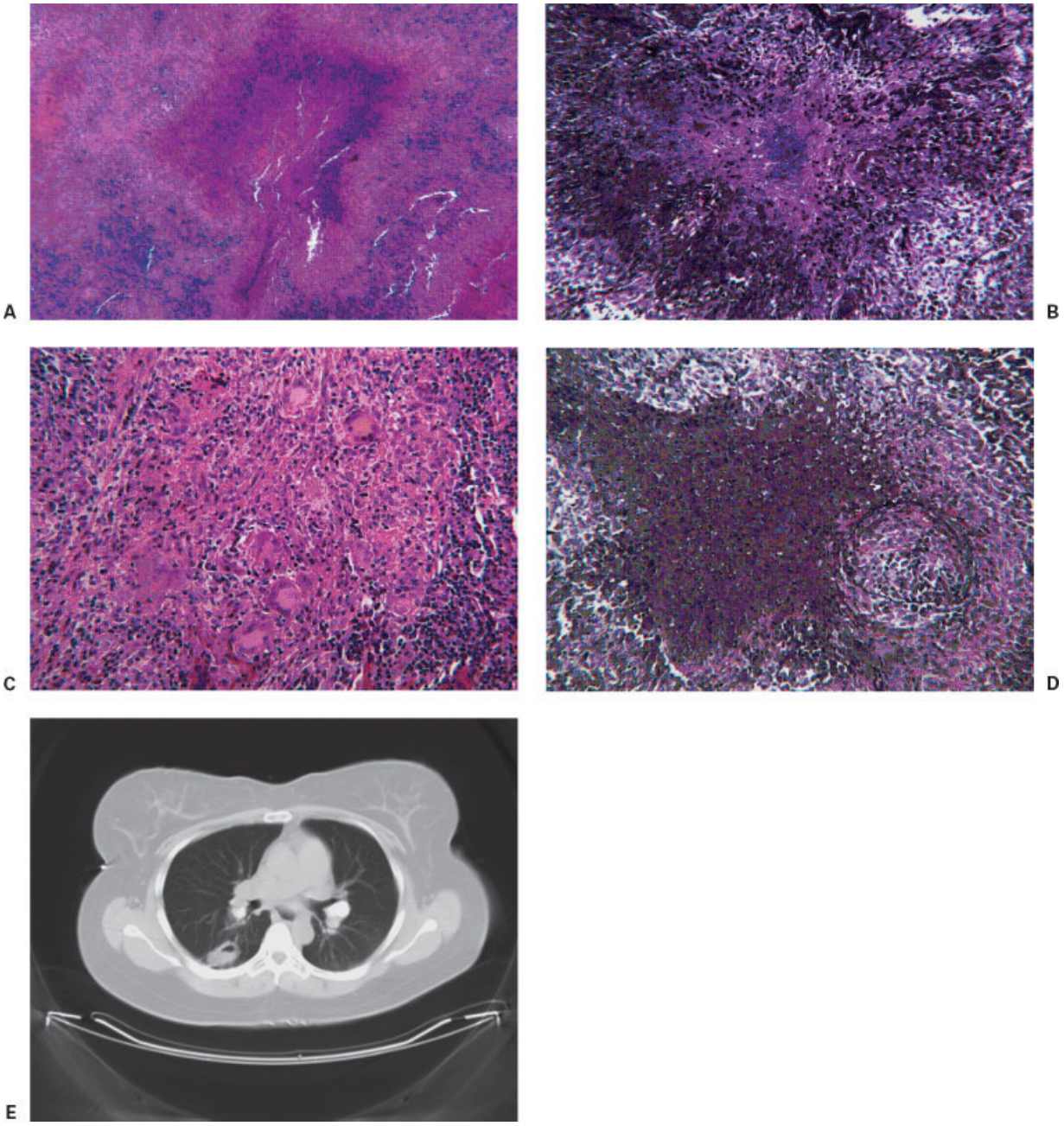

Figure 1 (A,B) Histology of the thoracoscopic lung biopsy demonstrates necrotizing granulomatous inflammation. (C) High-power examination of the thoracoscopic lung biopsy specimen reveals multinucleated giant cells within the granulomas. (D) An elastin stain of the thoracoscopic lung biopsy specimen shows a necrotizing granuloma that is perivascular, a hallmark of necrotizing sarcoid granulomatosis. (E) Chest computed tomographic slice revealing one of multiple parenchymal cavitary lesions.

because pertussis titers were supposedly elevated. After 3 months of this therapy, her symptoms had not improved and she was referred to the Sarcoidosis Clinic. Her physical examination was essentially normal except for a low-grade fever of 100.0°F. A repeat chest CT scan showed multiple new pulmonary lesions, some of which were cavitary (Fig. 1E). The previously obtained pathology specimens were reviewed. Antituberculous medications were discontinued as was clarithromycin and cefixime. The patient was begun on itraconazole 200 mg twice daily and prednisone 30 mg/day. A histoplasma complement fixation titer was negative. Her symptoms, which had been present for nearly 18 months, resolved within 1 week. Itraconazole was discontinued within 1 month, and prednisone was tapered to 10 mg/day over the next several months. The nodules continued to diminish on chest CT scan.

Diagnosis

Necrotizing sarcoid granulomatosis.

Discussion

Necrotizing sarcoid granulomatosis (NSG), first described by Liebow in 1973,[1] is characterized by sarcoid-like granulomata with vasculitis and necrosis. This initiated a debate as to whether the disease is a disorder of necrotizing angiitis with a sarcoid-like reaction or true sarcoidosis with necrosis of the granuloma around vessels.[2]

Patients with NSG are predominantly female and usually present within the third to seventh decade of life.[2,3] Patients typically present with pulmonary symptoms of cough, dyspnea, and chest pain.[2,3] However, extrapulmonary symptoms of visual problems, sicca syndrome, and skin rash are not rare and are clues to the diagnosis.

Radiographic findings in NSG include pulmonary infiltrates, solitary nodules, or multiple nodules.[2–5] The nodules and infiltrates are often cavitary.[2–5] The nodules have a predilection for perivascular and subpleural locations, and associated pleural effusions may be seen.[4,5] Hilar adenopathy is often identified on chest CT.[2]

The diagnosis of NSG must be distinguished from tuberculosis, fungal pneumonias, and other non-infective pulmonary angiitis and granulomatous disorders, such as Wegener's granulomatosis. A positive test for antineutrophilic cytoplasmic antibody (ANCA) with an elevated serum proteinase 3 strongly favors the diagnosis of Wegener's granulomatosis. Diagnostic features that would favor NSG include bilateral hilar adenopathy on chest radiograph/CT, extrapulmonary findings, such as eye or skin abnormalities, or extrapulmonary uptake on gallium-67 scanning.[3] Ultimately, a biopsy is required to make the diagnosis of NSG.[2] Although a definitive diagnosis usually requires a thoracoscopic or open-lung biopsy to demonstrate the perivascular nature of the granulomatous inflammation,[2] it is controversial whether the diagnosis could be made on clinical grounds from a smaller specimen obtained from transbronchial biopsy or endobronchial needle biopsy of a hilar lymph node. Necrotizing granulomas caused by tuberculosis and fungal diseases usually harbor a large number of organisms. Therefore, it is highly unlikely that such a biopsy specimen would fail to detect organisms by stain or culture. For these reasons, if a transbronchial or endobronchial needle lymph node biopsy reveals necrotizing granulomatous inflammation that does not demonstrate mycobacteria or fungi on staining, a case could be made to wait for the results of mycobacterial and fungal cultures. If the cultures are negative and the clinical picture is consistent with NSG, therapy can be initiated. In this instance, the patient must be closely monitored in the event that an infection has escaped detection.

The treatment of NSG is either surgical resection of the lesions or corticosteroids. The initial corticosteroid dose is 0.5 to 1.0 of daily prednisone equivalent.[2] Most patients respond to therapy, although relapses are common, including at extrapulmonary sites.[2]

CASE 2 PRESENTATION

A 33-year-old African American man presented with dyspnea and cough. He first noticed dyspnea on exertion 6 years earlier. His dyspnea, which initially had been minor, had been insidiously progressive to the point that he was short of breath on 15 feet ambulation at the time of presentation. He smoked one pack of cigarettes daily for the past 13 years. He had no history of tuberculosis and had negative tuberculin skin tests in the past. He had no history of significant bird exposure. He was empirically treated for 6 years for dyspnea that was thought to be related to chronic obstructive pulmonary disease. His therapy consisted of bronchodilators and intermittent short 3- to 5-day courses of oral corticosteroids. He had never been on oral corticosteroids for a period of weeks to months over the previous 6 years.

His physical examination was normal except for minimal hyperresonance to chest percussion. Pulmonary function tests revealed a severe obstructive ventilatory defect with forced vital capacity (FVC) 2.58 L (54% of predicted), forced expiratory volume in 1 second (FEV_1) 1.05 L (27% of predicted), and FEV_1:FVC ratio of 0.41. A chest radiograph revealed bullous emphysematous changes in both lungs (Fig. 2A). Bullous changes were confirmed on chest CT (Fig. 2B,C). In addition, the chest CT showed some subpleural parenchymal nodules (not shown) and thickening/infiltration along the bronchovascular bundles (Fig. 2D). A serum α-1-antitrypsin level was normal. The patient underwent bronchoscopy with transbronchial lung biopsy, which revealed the diagnosis.

Diagnosis

Pulmonary sarcoidosis presenting as bullous emphysema.

Discussion

Although 90% of bullous emphysema is attributable to cigarette smoking, other rare causes are known, including sarcoidosis.[6] Bullae from sarcoidosis are usually distinct from the localized cystic airspaces seen with fibrocystic sarcoidosis in that they are larger and are often the direct cause of pulmonary dysfunction.[6,7]

The cause of bullous formation in sarcoidosis is unknown. Three proposed mechanisms are (1) sarcoidosis involvement of bronchi and bronchioles causing peripheral air trapping and alveolar distention with rupture (ball-valve mechanism),[6,8,9] (2) retraction and

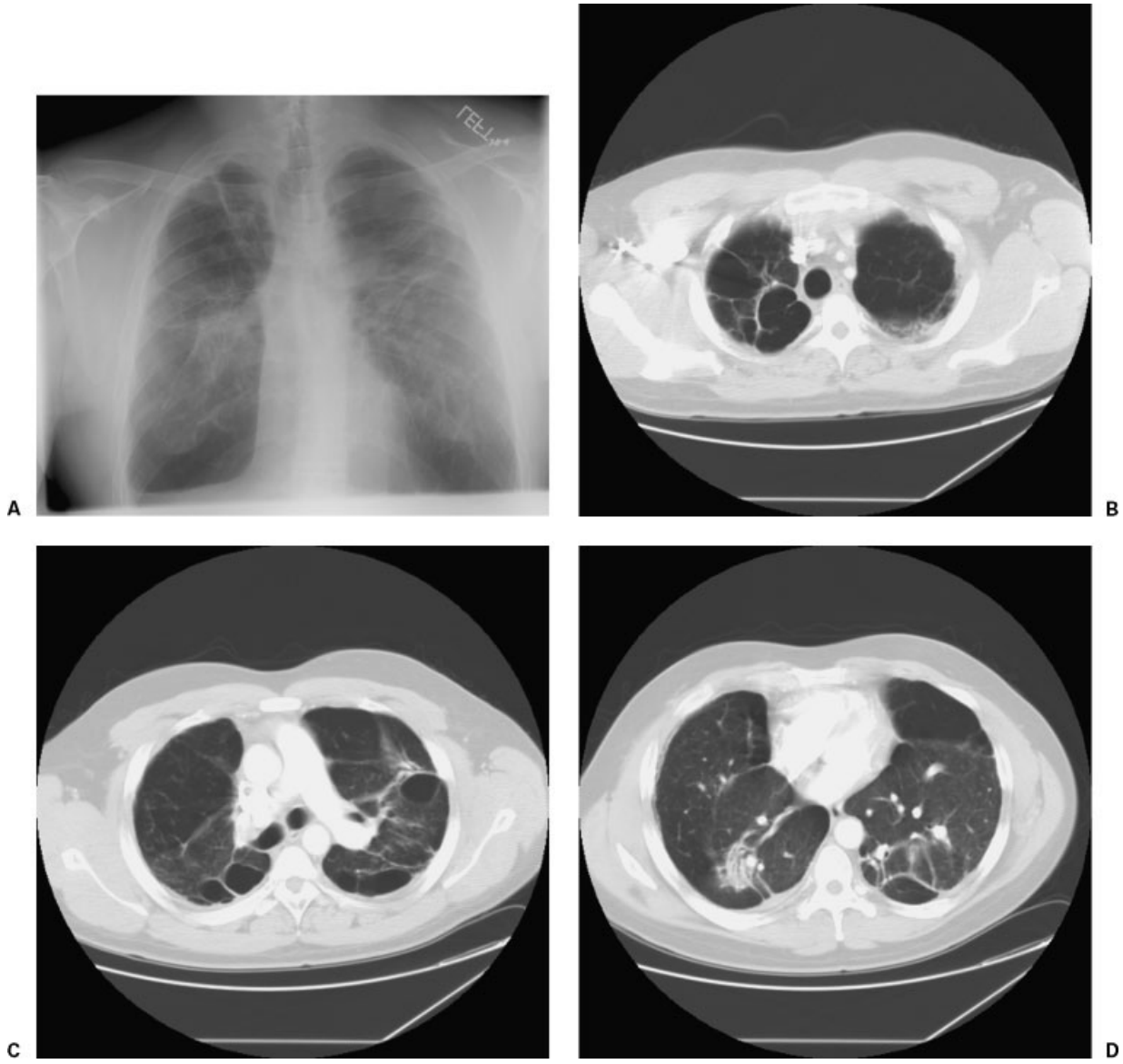

Figure 2 (A) Chest radiograph showing significant bullous lung disease. (B,C) Representative chest computed tomographic (CT) scan slices showing significant bullous lung disease. (D) Chest CT scan slice revealing bullous lung disease and right lower lobe thickening. This latter finding is suggestive of sarcoidosis, which has a predilection for the bronchovascular bundles.

collapse of surrounding diseased lung allowing overexpansion of less affected areas,[6] and (3) sarcoid alveolitis causing destruction of lung, with or without concomitant cigarette smoking.[6]

The diagnosis of bullous emphysema from sarcoidosis requires a lung biopsy, and transbronchial lung biopsy is almost always sufficient. Clues to the diagnosis include young age at presentation, limited smoking history, severe airflow obstruction, and CT findings of sarcoidosis, such as mediastinal adenopathy, parenchymal infiltrates/nodules, and a predilection for parenchymal disease along the bronchovascular bundles or in subpleural locations. Additional clues include signs or symptoms of extrapulmonary sarcoidosis, such as uveitis, skin lesions, and hypercalcemia.

Therapy includes corticosteroids, usually at an initial dose of 20 to 40 mg of daily prednisone equivalent.[10] However, therapy is often not beneficial because the pulmonary dysfunction may be permanent. Bullectomies have improved pulmonary function and symptoms.[6,11] Lung transplantation has been successfully performed for this disorder.[6,12]

CASE 3 PRESENTATION

A 70-year-old Caucasian woman was referred to pulmonary clinic for a lung nodule detected on an annual chest radiograph. She had no pulmonary symptoms. She had a 50 pack-year smoking history with cessation 10 years earlier. Her physical examination

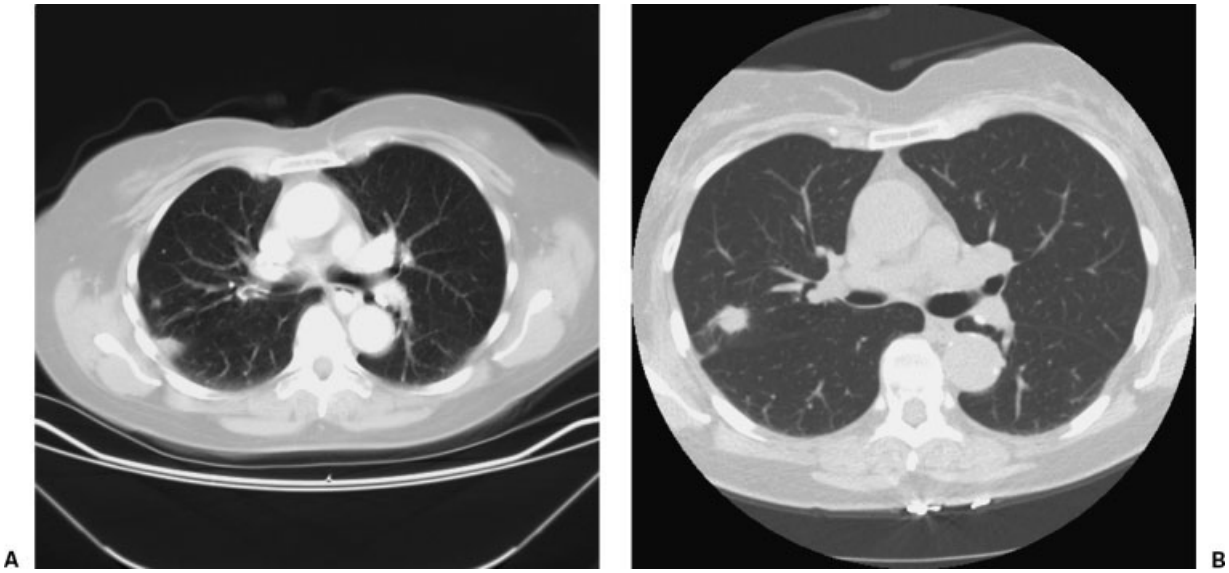

Figure 3 (A) Chest computed tomographic (CT) slice showing a subpleural right pulmonary nodule. A small pulmonary opacity is seen anterior to the nodule. (B) Chest CT slice 5 years after that in (A) showing a new solitary pulmonary nodule.

and laboratory data were unremarkable. CT of the thorax showed a soft-tissue density, 1.4 cm by 1.2 cm nodule in the right upper lobe abutting the major fissure as well as calcified lymph nodes in the left hilum (Fig. 3A). Given her previous smoking history and the high likelihood of malignancy, she underwent CT-guided transthoracic fine needle aspiration (TTNA) and core needle biopsy of the nodule. Pathological examination demonstrated noncaseating granulomas. Acid-fast, auramine-rhodamine, and Gomori methenamine silver stains were negative for microorganisms. A tuberculin purified protein derivative (PPD) skin test was negative. Radionuclide scintigraphy with gallium-67 showed increased uptake in the left hilar region corresponding to the lymphadenopathy found on the chest CT. A presumptive diagnosis of sarcoidosis was made. No treatment was given and the nodule resolved spontaneously without therapy. She remained asymptomatic for 5 years until a screening chest CT showed a new soft tissue density nodule measuring 1.5 cm by 1.5 cm in the right upper lobe (Fig. 3B), in a different location than the initial one. Although there was a concern that this nodule represented a lung malignancy, sarcoidosis was a consideration given her past history. For this reason she again underwent TTNA. Pathological examination showed fibrous tissue with mild chronic inflammation but no granulomas. She remains asymptomatic and has not received any form of treatment for her sarcoidosis in 5 years of follow-up.

Diagnosis

Sarcoidosis presenting as a solitary pulmonary nodule.

Discussion

The solitary pulmonary nodule (SPN) is defined as a single, round, intraparenchymal opacity, at least moderately well marginated and no greater than 3 cm in maximum diameter.[13] An SPN is a common reason for referral to a pulmonologist or thoracic surgeon. Approximately 150,000 SPNs are detected annually in the United States,[14] and this number is expected to increase as CT scanning becomes more frequent. Up to 40% of all surgically resected SPNs are malignant.[15,16] Attempts to predict the malignant potential of these lesions include a mathematical analysis of clinically obtained data. A numerical value representing probability of malignancy is assigned to nodule diameter, patient age, and smoking history (either current or former smokers) as well as the overall prevalence of lung malignancy in the population.[17,18] The values are then multiplied to give an odds ratio of malignancy (OR_m), and the probability of malignancy is calculated as the odds ratio of malignancy divided by the odds ratio of malignancy plus one: $(OR_m)/(OR_m + 1)$.[17] Applying this formula to our patient resulted in a probability of cancer of 88%.

The causes of the benign SPN includes infectious, inflammatory, congenital, and vascular diseases. Sarcoidosis is rare cause of an isolated SPN. Gotway and colleagues[19] described a patient who presented with an enlarging SPN that was ultimately determined to be sarcoidosis with a surgical wedge resection. They also reviewed the only nine previously reported cases in the medical literature of sarcoid presenting as an SPN. They argued that if a surgical approach was elected, benign disease should be considered and therefore an initial limited resection of the lesion with tissue examination of frozen sections should be performed.

Newer imaging modalities, such as 18-fluorodeoxyglucose-positron emission tomography (FDG-PET), have shown promise in helping to differentiate malignant from benign disease. Dewan and colleagues[20] showed that FDG-PET was superior to mathematical models in predicting malignancy of an SPN. However, FDG-PET is not clinically useful in differentiating sarcoidosis from malignant SPNs because sarcoidosis usually causes increased uptake on FDG-PET.[21] However, FDG-PET may still be useful in determining if the SPN is sarcoidosis because mediastinal or hilar lymph nodes also frequently show increased uptake. This may prompt the clinician to perform a flexible transbronchial needle aspiration (TBNA), with or without endobronchial ultrasound guidance (EBUS-TBNA).[21] Flexible TBNA can demonstrate mediastinal lymph node granulomas with high diagnostic accuracy.[22]

[^{18}F]-fluoro-α-methyltyrosine PET (FMT-PET) scanning may be useful to separate sarcoidosis from malignant nodules. Oriuchi and coworkers[23] compared the uptake of FMT-PET with FDG-PET in 10 patients with known sarcoidosis and 10 patients with lung malignancy and known nodal metastases. In all 20 patients, the mediastinal lymph nodes showed increased uptake on FDG-PET imaging with the sarcoid patients demonstrating high intensity uptake [standardized uptake value (SUV) >5]. With FMT-PET imaging, the patients with malignant lymph nodes all showed increased uptake, yet no sarcoid patient had this finding.

This case illustrates a rare presentation of sarcoidosis as an SPN with a high likelihood of malignancy based on mathematical models. FDG-PET imaging cannot reliably differentiate sarcoidosis from malignant SPNs. However, associated lymphadenopathy found with CT, gallium, or PET scanning may prompt a TBNA whereby the diagnosis of sarcoidosis can be established.

CASE 4 PRESENTATION

A 42-year-old woman with stage III sarcoidosis noted the insidious onset of increasing dyspnea with exertion and a worsening in her nonproductive cough. She denied any other change in symptomatology. Her chest radiograph at the time of presentation showed stable interstitial infiltrates and small bilateral pleural effusions (Fig. 4).

Pleural fluid analysis revealed a yellow serous fluid. The total nucleated cell count was 1650 cells/μL with 85% lymphocytes, 5% neutrophils, and 10% macrophages. The total protein was 3.7 g/dL with a pleural fluid:serum ratio of 0.58. The pleural fluid lactate dehydrogenase (LDH) was 95 IU/L with a pleural fluid/upper limits of normal serum LDH ratio of 0.40. Pleural fluid pH was 7.41 and glucose was 90 mg/dL. Pleural fluid triglyceride concentration was 25 mg/dL. Acid-fast bacilli and fungal smear and Gram stain were negative; all cultures were negative. Cytology showed no malignant cells.

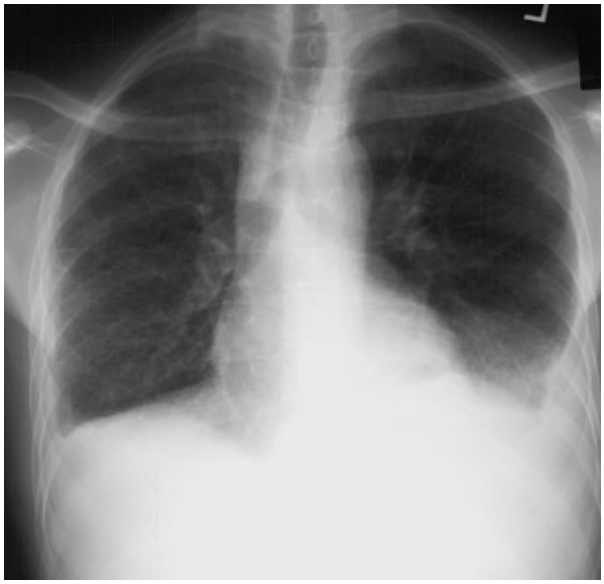

Figure 4 Chest radiograph demonstrating small bilateral pleural effusions.

The patient's prednisone dose was increased from 7.5 mg daily to 20 mg daily for the treatment of a possible pulmonary sarcoid exacerbation. Her symptoms improved over the next 2 weeks, and ultrasonography performed 4 weeks later showed complete resolution of the bilateral pleural effusions.

Diagnosis

Sarcoid pleural effusion characterized by a discordant exudate (by protein only) and a lymphocyte predominance ($>80\%$).

Discussion

Sarcoidosis commonly affects the lung, lymph nodes, skin, eyes, and liver. When sarcoidosis involves the pleura, it may manifest as pleural effusion, pneumothorax, pleural thickening, hydropneumothorax, trapped lung, hemothorax, or chylothorax.[24–28] Pleural effusion remains a rare manifestation of sarcoidosis in all published series.[29] Why pleural involvement is rare when parenchymal and nodal involvement is present in virtually all cases is not clear. Some authors suggest that a "protective pleural mechanism" exists inhibiting pleural fluid formation, whereas others opine that pleural involvement would be found more commonly if more sensitive methods were employed to detect pleural pathology.[29] Previous studies using chest radiographs alone have reported a prevalence ranging from 0.7 to 10%, with most literature supporting a prevalence of 1 to

2%.[30–34] A low prevalence was supported by a recent publication by Huggins and colleagues[29] who described the prevalence of pleural effusions defined by thoracic ultrasonography in 181 consecutive outpatients with sarcoidosis. In this series, the prevalence of pleural effusions was 2.8% (5/181); a pleural effusion caused by sarcoidosis was diagnosed in only 1.1% (2/181) of patients. An exacerbation of pulmonary sarcoidosis was not an independent risk factor for the development of a sarcoid pleural effusion.[29]

The mechanism of pleural effusion formation in sarcoidosis is presumably similar to other infiltrative diseases. Involvement of the pleura may lead to increased capillary permeability. Superior vena cava obstruction,[27] endobronchial sarcoidosis leading to bronchial stenosis and lobar atelecatsis,[28] trapped lung,[35] and lymphatic disruption with the development of chylothorax have been reported as causes of sarcoid-related pleural effusions.[26]

Szwarcberg and colleagues[36] published their findings in a series of 61 patients with sarcoidosis using thoracic CT scans. The authors noted that 25 (41%) of the 61 patients had "pleural involvement" detected on CT. Of the 25 patients with pleural involvement, 20 (80%) had pleural thickening and five (20%) patients had pleural effusions; the frequency of pleural effusions was 8.2% (five of 61). The cause of the pleural disease in this cohort of sarcoidosis patients was not determined.

Sarcoidosis-related pleural effusions occur slightly more commonly in the right hemithorax.[29] The reason for the right-sided predominance is unclear and is not related to organ involvement. Bilateral effusions have been reported in 22% of cases.[29]

Sarcoid-related pleural effusions have been described as both exudates and transudates. Most series, however, did not report the criteria used to classify these effusions. Numerous authors used pleural fluid protein and specific gravity alone to differentiate transudates from exudates. When either the protein or LDH criterion is used, the majority of sarcoid-related pleural effusions are exudative. Moreover, the transudates described in the literature were from a small series of eight patients reported by Wilen and colleagues.[33]

The appearance of the pleural fluid is most commonly serous. The typical pleural fluid analysis in sarcoid pleural effusions reveals a paucicellular, lymphocyte predominant (> 80%) exudate, with a pleural:serum protein ratio more consistently in the exudative range than the pleural fluid LDH criterion (pleural fluid LDH compared with the upper limits of normal serum LDH).[29] The discordance between pleural fluid protein and LDH ratios suggests that the pathogenesis of sarcoid-related pleural effusions is most consistent with increased capillary permeability with minimal pleural space inflammation. A definitive diagnosis of sarcoid pleural effusion relies on a pleural biopsy demonstrating nonnecrotizing granulomas, with the exclusion of granulomatous diseases of known etiology.

The majority of patients reported with a sarcoid pleural effusion have had stage II disease. It appears that with the progression of the parenchymal disease, the prevalence of pleural effusions decreases, whereas pleural thickening and pneumothorax increases.[24] Nevertheless, sarcoid-related pleural effusions can occur in all Scadding radiographic stages.

The management of sarcoid pleural effusions should be individualized with the knowledge that a majority of these effusions resolve spontaneously in 1 to 3 months.[37] However, there are reports of resolution at 2 weeks with steroid therapy and as long as 6 months with or without the administration of corticosteroids.[35,38] In the absence of symptoms, the pleural effusion usually resolves spontaneously. Systemic corticosteroids should be considered for the symptomatic patient and if the effusion is recurrent. Incomplete resolution of the pleural effusion with progression to chronic pleural thickening or a trapped lung has been reported. Decortication has been successful in relieving dyspnea in a patient who had an unexpandable lung from sarcoidosis.[35]

REFERENCES

1. Liebow AA. The J Burns Amberson Lecture: pulmonary angiitis and granulomatosis. Am Rev Respir Dis 1973;108: 1–18
2. Quaden C, Tillie-Leblond I, Delobbe A, et al. Necrotising sarcoid granulomatosis: functional, endoscopical, and radiographical evaluations. Eur Respir J 2005;26:778–785
3. Shirodaria CC, Nicholson AG, Hansell DM, et al. Necrotizing sarcoid granulomatosis with skin involvement. Histopathology 2003;43:91–91
4. Chittock DR, Joseph MG, Paterson NA, McFadden RG. Necrotizing sarcoid granulomatosis with pleural involvement: clinical and radiographic features. Chest 1994;106:672–676
5. Niimi H, Hartman TE, Muller NL. Necrotizing sarcoid granulomatosis: computed tomography and pathologic findings. J Comput Assist Tomogr 1995;19:920–923
6. Judson MA, Strange C. Bullous sarcoidosis: a report of 3 cases. Chest 1998;114:1474–1478
7. Miller A. Vanishing lung syndrome associated with pulmonary sarcoidosis. Br J Dis Chest 1981;75:209–214
8. Karden KA, Barthakur A. "Cavitary" lesions in sarcoidosis. Chest 1959;35:607–614
9. Zar HJ, Cole RP. Bullous emphysema occurring in pulmonary sarcoidosis. Respiration 1995;62:290–293
10. American Thoracic Society/European Respiratory Society. Statement on sarcoidosis. Joint Statement of the American Thoracic Society (ATS), the European Respiratory Society (RS) and the World Association of Sarcoidosis and Other Granulomatous Diseases (WASOG) adopted by the ATS Board of Directors and the ERS Executive Committee, February 1999. Am J Respir Crit Care Med 1999;160:736–755
11. Pena CM, Cosgrove DM, Kirby T, et al. Bullectomies for bullous sarcoidosis. Cleve Clin J Med 1993;60:157–160

12. Levine SM, Anzueto A, Peters JI, et al. Single lung transplantation in patients with systemic disease. Chest 1994;105:837–841
13. Hartman TE. Evaluation of the solitary pulmonary nodule. Radiol Clin North Am 2005;43:459–465
14. Leef JL, Klein JS. The solitary pulmonary nodule. Radiol Clin North Am 2002;40:123–143
15. Midthun DE, Swensen SJ, Jett JR. Approach to the solitary pulmonary nodule. Mayo Clin Proc 1993;68:378–385
16. Comstock GW, Vaughan RH, Montgomery G. Outcome of solitary pulmonary nodules discovered in an x-ray screening program. N Engl J Med 1956;254:1018–1022
17. Cummings SR, Lillington GA, Richard RJ. Estimating the probability of malignancy in solitary pulmonary nodules. Am Rev Respir Dis 1986;134:449–452
18. Cummings SR, Lillington GA, Richard RJ. Managing solitary pulmonary nodules: the choice of strategy is a "close call." Am Rev Respir Dis 1986;134:453–460
19. Gotway MB, Tchao NK, Leung JWT, Hanks DK, Thomas AN. Sarcoidosis presenting as an enlarging solitary pulmonary nodule. J Thorac Imaging 2001;16: 117–122
20. Dewan NA, Shehan CJ, Reeb SD, et al. Likelihood of malignancy in a solitary pulmonary nodule: comparison of Bayesian analysis and results of FDG-PET scan. Chest 1997; 112:416–423
21. Zhuang H, Yu JQ, Alavi A. Applications of fluorodeoxyglucose-PET imaging in the detection of infection and inflammation and other benign disorders. Radiol Clin North Am 2005;43:121–134
22. Trisolini R, Agli LL, Cancellieri A, et al. The value of flexible transbronchial needle aspiration in the diagnosis of stage I sarcoidosis. Chest 2003;124:2126–2130
23. Oriuchi N, Inoue T, Tomiyoshi K, et al. F-18-alpha-methyltyrosine (FMT) and F-18-fluorodeoxyglucose (FDG) PET in patients with sarcoidosis [abstract]. J Nucl Med 1999;40:196P
24. Soskel NT, Sharma OP. Pleural involvement in sarcoidosis: case presentation and detailed review of the literature. Curr Opin Pulm Med 2000;6:455–468
25. De Vuyst P, De Troyer A, Yernault JC. Bloody pleural effusion in a patient with sarcoidosis. Chest 1979;76:607–609
26. Aberg H, Bah M, Waters AW. Sarcoidosis complicated by chylothorax. Minn Med 1966;57:1065–1070
27. Gordonson J, Trachtenberg S, Sargent EN. Superior vena cava obstruction due to sarcoidosis. Chest 1973;63:292–293
28. Poe Rh. Middle-lobe atelectasis. NY State J Med 1978;78: 2895–2897
29. Huggins JT, Doelken P, Sahn SA, et al. Pleural effusions in a series of 181 outpatients with sarcoidosis. Chest 2006;129: 1599–1604
30. Chusid EL, Siltzbach LE. Sarcoidosis of the pleura. Ann Intern Med 1974;81:190–194
31. Sharma OP, Gordonson J. Pleural effusion in sarcoidosis: a report of six cases. Thorax 1975;30:95–101
32. Beekman JF, Simmert SM, Chun PK, et al. Spectrum of pleural involvement in sarcoidosis. Arch Intern Med 1976; 136:323–330
33. Wilen SB, Rabinowitz JG, Ulrich S, et al. Pleural involvement in sarcoidosis. Am J Med 1974;57:200–209
34. Tommasini A, Vittorio GD, Faccinetti F, et al. Pleural effusions in sarcoidosis: a case report. Sarcoidosis 1994;11: 138–140
35. Heidecker JT, Judson MA. Pleural effusion caused by a trapped lung. South Med J 2003;96:510–511
36. Szwarcberg JB, Glajchen N, Teirstein AS. Pleural involvement in chronic sarcoidosis detected by thoracic CT scanning. Sarcoidosis Vasc Diffuse Lung Dis 2005;22:58–62
37. Cohen M, Sahn SA. Resolution of pleural effusions. Chest 2001;119:1547–1562
38. Johnson NM, Martin NDT, McNicol MW. Sarcoidosis presenting with pleurisy and bilateral pleural effusions. Postgrad Med J 1980;56:266–267