




Contents lists available at ScienceDirect

## Pulmonary Pharmacology &amp; Therapeutics

journal homepage: [www.elsevier.com/locate/ypupt](http://www.elsevier.com/locate/ypupt)

# Iron laden macrophages in idiopathic pulmonary fibrosis: The telltale of occult alveolar hemorrhage?☆

Q3 Ermanno Puxeddu<sup>a</sup>, Alessia Comandini<sup>a</sup>, Francesco Cavalli<sup>b</sup>, Gabriella Pezzuto<sup>c</sup>,  
Claudio D'Ambrosio<sup>b</sup>, Lucia Senis<sup>c</sup>, Maurizio Paci<sup>d</sup>, Giacomo Curradi<sup>e</sup>, G.L. Sergiacomi<sup>a</sup>,  
Cesare Saltini<sup>a,b,c,\*</sup>

<sup>a</sup> Department of Biomedicine and Prevention, Tor Vergata University Hospital, Roma, Italy

<sup>b</sup> Postgraduate School in Pulmonary Medicine, Tor Vergata University Hospital, Roma, Italy

<sup>c</sup> Pulmonary Fibrosis Clinic, Division of Respiratory Diseases, Tor Vergata University Hospital, Roma, Italy

<sup>d</sup> Department of Chemical Science and Technology, University of Rome "Tor Vergata", Italy

<sup>e</sup> Doctorate School in Medical Sciences, University of Bologna, Bologna, Italy

## Q1 A R T I C L E I N F O

### Article history:

Received 24 September 2013

Received in revised form

14 November 2013

Accepted 11 December 2013

### Keywords:

Idiopathic pulmonary fibrosis

Bronchoalveolar lavage

Total iron

Hemosiderin and disease severity

## A B S T R A C T

**Rationale:** A number of observations suggest that iron accumulates in the lungs of patients with idiopathic pulmonary fibrosis (IPF) with vascular abnormalities, including pulmonary hypertension.

**Objectives:** The aim of this study was to determine the prevalence and intensity of accumulation of alveolar epithelial lining fluid (ELF) iron and of alveolar macrophage hemosiderin in IPF and its relationship with disease severity.

**Methods:** Forty seven IPF patients and 14 healthy controls were retrospectively evaluated for iron accumulation in the lower respiratory tract using total iron spectrophotometric measures and for hemosiderin accumulation using the Perls' stain with the Golde score.

**Measurements and main results:** Total iron levels in ELF were significantly increased in IPF patients compared to non-smoking controls ( $p < 0.05$ ); there were no differences with healthy smokers ( $p = 0.2$ ). Hemosiderin accumulation in alveolar macrophages was similar in never smoking and ever smoking IPF patients ( $p = 0.5$ ), was significantly higher in IPF patients than in both smoking and non-smoking healthy controls ( $p < 0.05$ , all comparisons) and was positively correlated with echocardiographic estimates of pulmonary artery systolic pressure ( $p < 0.05$ ) and with increasing disease severity scores ( $p < 0.05$ ).

**Conclusions:** The data show exaggerated accumulation of iron in IPF broncho-alveolar ELF and alveolar cells with no association with tobacco smoke, thus suggesting, occult pulmonary hemorrhage as a likely cause.

© 2013 Published by Elsevier Ltd.

## 1. Introduction

Idiopathic pulmonary fibrosis (IPF) is a form of chronic, progressive fibrosing interstitial pneumonia of unknown cause affecting older adults, limited to the lungs and characterized by the

histopathological pattern of usual interstitial pneumonia (UIP) [46]. Although no causal agent has been found so far, a number of potential risk factors have been identified, including environmental factors such as exposure to occupational dusts [16,17] and to tobacco smoke [3,20,30,54,56].

Tobacco smoke is known to promote iron accumulation in the lower respiratory tract [39,58] by carrying iron-rich particles [31] or humic-like siderophores capable of mobilizing iron from endogenous sources [13]. The macrophage response to excess iron is characterized by the induction of iron storage proteins [12] and the subsequent sequestration in the form of hemosiderin by hemosiderin-laden macrophages, or siderophages [41], to prevent iron-induced oxidative stress leading to inflammation and fibrosis [19,24,42]. Exaggerated numbers of iron-laden macrophages have been observed in pulmonary veno-occlusive disease, an uncommon form of pulmonary hypertension associated with exposure to

☆ This study was conducted with the financial support of an unrestricted grant from Boehringer-Ingelheim (Italy). A.C. was supported by a fellowship from "Associazione Italiana Malattie Interstiziali del Polmone" Roma, Italy) through a donation of A. Benassi, G.C. was supported by a fellowship from the Doctorate School in Medical Sciences, University of Bologna.

\* Corresponding author. University of Rome Tor Vergata, Department of Biomedicine and Prevention, Via Montpellier 1, 00133 Roma, Italy. Tel.: +39 (0)6 20902789.

E-mail addresses: [cesaresaltini@med.uniroma2.it](mailto:cesaresaltini@med.uniroma2.it), [saltini@med.uniroma2.it](mailto:saltini@med.uniroma2.it) (C. Saltini).

tobacco smoke [36] and, interestingly, in IPF patients in association with diffuse vascular abnormalities [6,21].

This study was designed to determine the prevalence and intensity of accumulation of iron in the bronchoalveolar spaces of the IPF lung, using a bronchoalveolar lavage sample bank. The study has limitations. Firstly, it is a retrospective study. Secondly, with regard to the study population, due to difficulties with recruiting respiratory samples of older healthy subjects, the control population was younger than the patient population. In addition, as most ever-smoking IPF patients were former smokers, a comparable control population of healthy controls who had stopped smoking for a similar length of time was unavailable. Thirdly, with regard to clinical evaluation, echocardiographic estimates of pulmonary arterial pressure, a measure burdened by inaccuracy in IPF [38], were used instead of invasive direct measures, as only four patients had undergone right heart catheterization in temporal proximity to BAL for the assessment of pulmonary hypertension. Finally, a prognostic score was used as a substitute of long term follow up.

## 2. Methods

### 2.1. Patient population

We analyzed bronchoalveolar lavage (BAL) samples from 14 healthy volunteers, evaluated for an interventional study protocol approved by the Independent Ethical Committee of the Tor Vergata University Hospital (Rome, Italy) (protocol number 123/08), and from 47 IPF patients who had been evaluated at the Respiratory Diseases Unit of the Tor Vergata University Hospital (Rome, Italy). Of the BAL samples obtained from IPF patients, the fraction not used for routine diagnostic tests was stored for research purposes after informed consent, with the approval of the Independent Ethical Committee of the Tor Vergata University Hospital.

The 14 healthy controls were 6 females and 8 males (average age  $49 \pm 9$  years): 7 were current cigarette smokers (pack-years  $25 \pm 13$ ) and 7 were never smokers. All had normal pulmonary function tests and no history of cardio-respiratory disease.

The IPF patient population was comprised of 15 females and 32 males (average age  $69 \pm 9$  years): 26 were ever-smokers (pack-years  $27 \pm 19$ ). Twenty-five of them had stopped smoking one to 40 ( $14.7 \pm 12.6$ ) years before evaluation. Average age at smoke cessation was  $56 \pm 12.3$  years. The diagnoses of UIP/IPF, based on the 2000 ATS/ERS consensus statement, were as revised according to 2011 international guidelines [46], based upon the identification of confident IPF by HRCT in 41 patients and confident UIP by histology in six patients.

### 2.2. Clinical evaluation

Pulmonary function testing, performed using a total body plethysmograph Jaeger Master Screen MS PFT Analyzer Unit (Jaeger, Würzburg, Germany), included forced vital capacity (FVC), forced expiratory volume in 1 s (FEV1), total lung capacity (TLC) and residual volume (RV) [27]. Carbon monoxide diffusion capacity

(DLCO) was measured using a Jaeger Master Screen MS PFT Analyzer Unit (Jaeger, Würzburg, Germany) [27]. Systolic pulmonary artery pressure (PAPs) was estimated by echocardiography in 43 out of 47 IPF patients within  $23 \pm 21$  days from bronchoscopy (Table 1). Values of estimated PAPs greater than 35 mmHg were considered indicative of pulmonary hypertension [18].

All control subjects had pulmonary function testing the day before bronchoscopy and BAL; the IPF patients had pulmonary function testing within  $32 \pm 32$  days from bronchoscopy showing a median FVC of 74.8% predicted (interquartile range 54.9–87.3) and a median DLCO of 43.4% predicted (24.9–59.3). Using the above data, disease severity was characterized as GAP index stage I through III, according to the survival prediction model recently described by Ley et al. [26].

At the time of evaluation 13 patients weren't receiving any medications, 3 were taking acetylsalicylic acid alone, and one n-acetyl cysteine alone. The other patients were under different combination of the above mentioned drugs with proton pump inhibitors, glucocorticoids, statins and anti-hypertensive drugs for a total of 28 patients under proton pump inhibitors therapy, 20 under acetylsalicylic acid, 19 glucocorticoids, 15 n-acetyl cysteine, 11 statins and anti-hypertensive drugs. Only one patient was under treatment with warfarin sodium in association with proton pump inhibitors, glucocorticoids and statins.

### 2.3. Broncho-alveolar lavage

BAL was performed under local anesthesia with a flexible fiberoptic bronchoscope Olympus BF 1T 180 (Olympus, Hamburg, Germany) as previously described [33,53].

Differential cell counts were done on May Grumwald Giemsa Quick Stain (Bio-Optica, Milan, Italy) stained slides ( $50 \times 10^3$  cells per slide, 5 min at 170 g on a Cytospin Shandon 4, Thermo Scientific, Waltham, MA, USA) (Table 1).

BAL fluid were separated from cells by centrifugation at 500 g for 5 min at 4 °C.

Results were normalized for epithelial lining fluid (ELF) using urea as marker of dilution [47].

### 2.4. Quantification of iron in ELF using ICP-OES

Total ferrous and ferric iron concentration in ELF was measured by inductively coupled plasma-optical emission spectrometry (ICP-OES), a method with a lower sensitivity limit of about 4 µg/l, using a Vista-MPX CCD simultaneous, Varian spectrophotometer (Mulgrave, Australia) as described by Rad and Co-workers [44].

ELF samples were acidified by addition of 15 µl HNO<sub>3</sub> 0.2% and loaded by an automatic sample charger SPS 3 Varian, and then were nebulized into an argon plasma, where all components were vaporized. Iron compounds were dissociated and excited, and the intensity of emitted radiation was measured at a wavelength of 234.35 nm. Total iron quantification was obtained by comparing the sample emission intensity with that of a 100 µg/L iron standard.

**Table 1**

BAL cell counts. Data are presented as median and 25th – 75th percentiles.

	n	10 <sup>6</sup> cells/ml ELF	% Viability	Differential cell count					
				% Macrophages	% Neutrophils	% Lymphocytes	% Eosinophils	% Monocytes	% Epithelial cells
Controls non smokers	7	7.3 (2.4–14.7)	98.3 (93.0–100)	79.7 (64.2–88.9)	4.7 (1.7–10.8)	8.2 (7.0–32.1)	0.3 (0.2–0.6)	0.5 (0.3–2.5)	3.3 (0.2–8.3)
Controls smokers	7	14.1 (7.9–33.0)	99.0 (93.5–100)	86.2 (84.3–87.2)	2.8 (1.2–3.8)	7.8 (4.8–10.1)	0.2 (0–2.5)	1.3 (1.2–4.6)	1.3 (0–1.4)
UIP non smokers	21	12.5 (7.6–22.0)	99.7 (96.4–100)	67.4 (58.2–78.3)	14.2 (4.8–24.4)	7.8 (3.7–12.7)	1.9 (0.9–5.9)	2.8 (1.6–4.1)	1.3 (0.9–3.0)
UIP smokers	26	10.5 (6.5–14.1)	98.7 (96.7–100)	72.8 (64.9–80.6)	17.7 (5.2–23.7)	4.9 (2.9–7.5)	1.6 (0.3–4.0)	2.8 (1.0–4.0)	1.6 (0.9–2.5)

Iron concentration was determined in triplicates and mean and standard deviation values were calculated.

### 2.5. Enumeration of iron-stained alveolar macrophages

The Perls' iron staining was performed to assess the numbers of hemosiderin-laden cells according to standard procedures using a commercial kit (Bio-Optica, Milan, Italy) as described by Golde et al. [14].

The Golde score was obtained by counting 200 macrophages and by grading each cell for the blue staining of the cytoplasm from 0 to 4, where 0 corresponds to no blue color, 1 to faint blue color, 2 to dense blue color in minor portion of cytoplasm or medium color intensity throughout cell, 3 to deep blue color in most of the cytoplasm, 4 to dark blue color throughout cytoplasm. A mean score for 100 cells was calculated, 0 being the minimum and 400 the maximum scores. The Golde score was independently calculated by two blinded observers.

### 2.6. Statistical methods

Clinical and laboratory data were analyzed using Graph Pad Prism 4.0 (Graph Pad Software Inc.). Demographic data are expressed as mean  $\pm$  standard deviation. Clinical and laboratory data are expressed as median and 25th – 75th percentiles are reported.

With regard to hemosiderin-laden alveolar macrophages, Perls'-positive cell counts and Golde scores of normal smokers and IPF patients were analyzed both as continuous and categorical values using the 95th percentile of Golde scores of the control population, including control smokers, as upper limit to discriminate scores as within or above normal limits. Comparisons between the study groups were done using with the nonparametric Mann–Whitney test and Chi-square trend test for frequency distribution analysis. For correlation analysis, the Spearman correlation was applied.

## 3. Results

### 3.1. Quantification of iron in ELF using ICP-OES

Total iron concentration in ELF was significantly increased in the lower respiratory tract of healthy smoking controls (median 5.1  $\mu$ g/ml, 25th and 75th percentiles 4.5 and 9.1, respectively) compared to healthy non-smokers (1.4  $\mu$ g/ml, 1.3–2.0) ( $p < 0.0023$ ) (Fig. 1).

ELF iron concentration of IPF-affected individuals (3.4  $\mu$ g/ml, 1.8–7.2) was significantly higher than that of never smoking healthy controls ( $p < 0.02$ ). When never-smoking (2.9  $\mu$ g/ml, 1.7–6.4) and ever-smoking (3.7  $\mu$ g/ml, 1.8–7.3) IPF patients were analyzed separately, there were no differences between the never- and the ever-smoking IPF affected ( $p = 0.74$ ), both had significantly higher levels of ELF iron than healthy non-smokers ( $p = 0.03$  and  $p = 0.02$ , respectively). Both IPF subgroups were no different from healthy current smokers ( $p = 0.1$ ,  $p = 0.2$ , respectively) (Fig. 1). When the relationship between tobacco smoke history and the accumulation of iron in IPF patients was analyzed, no correlation was found between ELF iron and either the number of cigarette smoked (in pack years), the number of years since smoke cessation or the age at smoke cessation (Spearman  $r = 0.04$ ,  $p = 0.8$ ,  $r = -0.20$ ,  $p = 0.3$ , and  $r = 0.06$ ,  $p = 0.8$ , respectively).

### 3.2. Assessment of hemosiderin accumulation in alveolar macrophages in BAL samples

Cell counts of BAL samples showed that IPF-affected individuals, as normal smoking controls, had a higher, albeit non significantly

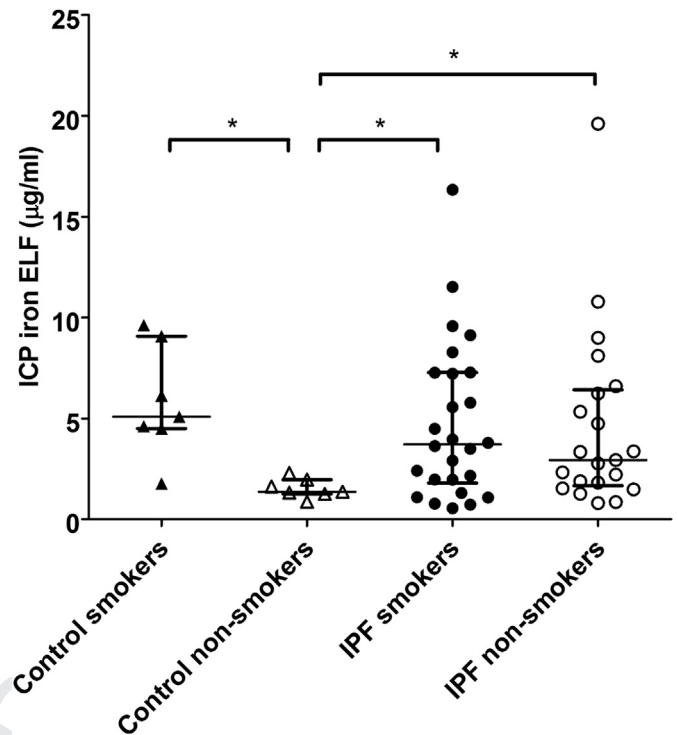


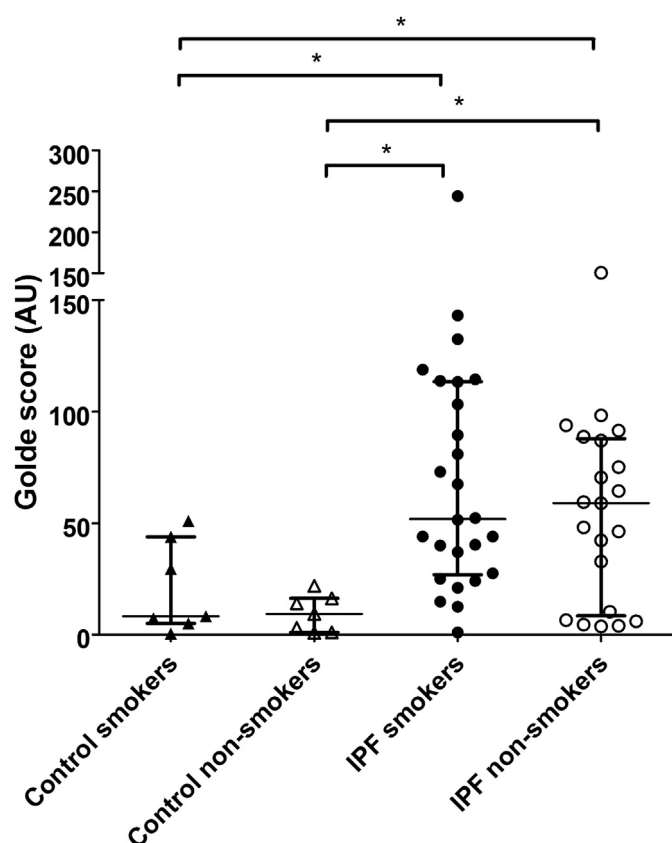
Fig. 1. Alveolar ELF iron concentration of IPF-affected individuals and healthy never smoker and current smoker controls. Data are reported as median and 25th and 75th percentiles are indicated. \* $p < 0.05$ .

( $p = 0.13$  and  $p = 0.22$ , respectively), number of recovered cells per ml of ELF as compared to non-smoking healthy controls (Table 1). IPF patients had a significantly higher percentage of polymorphonuclear leucocytes, as compared to both smoking and non-smoking controls ( $p = 0.0006$  and  $p = 0.003$ , respectively). Airway cell contamination was similar in the samples from the IPF-affected compared to non-smoking and smoking controls ( $p = 0.25$  and  $p = 0.24$ , respectively) (Table 1).

The number of iron-laden alveolar macrophages was significantly greater in IPF-affected individuals than in non-smoking and smoking healthy controls. Perls' stain-positive macrophages in the alveolar cell population were 5.0% (1.3%–12.8%) for non-smoking controls, 6.0% (5.3%–19.5%) in healthy smokers, 36.9% (5.8%–53.2%) in never smoking IPF-affected and 29.0% (20.8%–64.4%) in the ever smoking IPF-affected. Interestingly, the numbers of Perls'-positive cell percentages in ever smoking and never smoking IPF patients were strikingly similar ( $p = 0.43$ ).

Semiquantitative cytochemical assessment demonstrated a marked increase of macrophage hemosiderin accumulation both in never smoking [Golde score 51.5 (27.5–113.3)] and ever smoking IPF-affected individuals [Golde score 59.3 (7.4–88.3)] in comparison to both non-smoking [9.3 (2.0–15.1)] ( $p = 0.008$  and  $p = 0.0005$ ) and smoking [8.3 (6.1–36.6)] ( $p = 0.04$  and  $p = 0.01$ ) controls, respectively (Fig. 2). As for Perls'-positive cell counts, the differences in the Golde scores of alveolar macrophages between ever smoking and never smoking IPF patients was not statistically significant ( $p = 0.53$ ) (Fig. 2). Similarly to ELF iron, when the relationship between tobacco smoke history and hemosiderinic iron accumulation in IPF patients was analyzed, no correlation was found between the Golde scores and either the number of cigarettes smoked (in pack years), the number of years since smoke cessation or the age at smoke cessation (Spearman  $r = 0.25$ ,  $p = 0.24$ ,  $r = 0.06$ ,  $p = 0.7$  and  $r = -0.21$ ,  $p = 0.35$ , respectively).





**Fig. 2.** Cytochemical assessment of the frequency of iron-laden alveolar macrophages obtained by BAL from the lower respiratory tract of IPF-affected individuals and from healthy controls using semi-quantitative assessment of the Perls' stain with the Golde score. Data are reported as median and 25th and 75th percentiles are indicated. \* $p < 0.05$ .

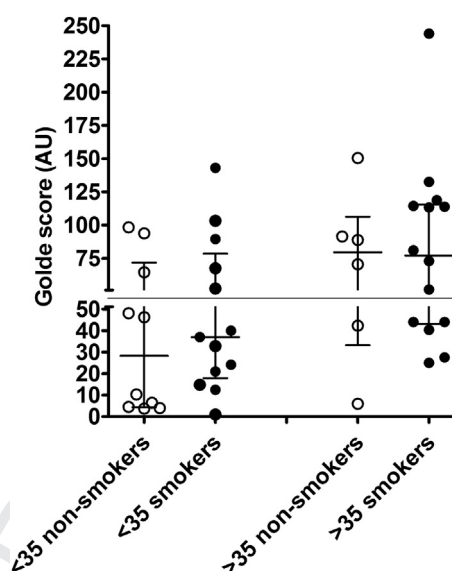
### 3.3. Interrelationship between semiquantitative measures of hemosiderin accumulation, cardiopulmonary function and disease severity

IPF patients with elevated pulmonary artery pressure [PAPs > 35 mm Hg], as assessed by echocardiographic estimates, showed significantly increased hemosiderin accumulation, as quantified by the Golde score, in comparison to those with normal pulmonary artery pressure values [Golde score 77 (42.7–114.3) and 37 (10.3–67.5) respectively; Mann Whitney  $p = 0.0089$ ], irrelevant of patient's smoking history (Fig. 3).

With regard to disease severity, correlation analysis of the Golde score with disease stage, as predicted by the GAP prognostic score, showed that Golde scores were abnormally elevated in 28% of GAP stage I patients ( $n = 18$ ), with a median score of 36.4 (5.6–55.3), in 53% of GAP stage II patients ( $n = 17$ ), with a median score of 70.5 (24.6–108.9) and in 92% of GAP stage III patients ( $n = 12$ ), with a median score of 81.9 (59.1–108.4) (Chi-square trend test  $p = 0.0027$ ) (Fig. 4).

## 4. Discussion

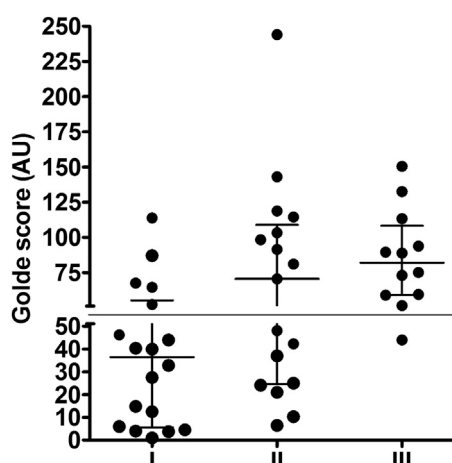
Tobacco smoke exposure is capable of driving iron accumulation in the epithelial lining fluid of the lung and ferritin accumulation within the alveolar macrophages [30] to an extent that is correlated with smoke history both in terms of cigarettes smoked per day and number of years of smoking [58]. In this context, and with the knowledge that tobacco smoke exposure has been identified as an



**Fig. 3.** Golde score in IPF patients categorized by presence of estimated abnormal systolic pulmonary pressure and smoking history. The break on the vertical axis represent the upper limit of normal Golde score values. Data are reported as median and 25th and 75th percentiles are indicated. \* $p < 0.05$ .

IPF risk factor, it is reasonable to foresee a direct relationship between hemosiderophages accumulation and tobacco smoke. However, with the limitation that most ever-smokers in the IPF population were in fact former smokers, the data show no difference between the non-smoking and the ever smoker IPF patients and no association with the smoking history in terms of numbers of cigarette smoked, years from smoke cessation and age of smoke cessation, indicating that iron accumulation in the bronchoalveolar spaces of the IPF lung is largely independent of tobacco smoke.

Studies of the time course of hemosiderophages accumulation in the lung, although limited, show that, in the experimental animal, the numbers of lung siderophages increase up to 60% one week after intra-tracheal red cell instillation, to decrease to less than 10% in one month [10]. Data on spontaneous hemorrhage are very limited but consistent with the animal data [55]. On the other hand, it has been shown that iron particles administered in vivo by inhalation are cleared from the lungs in four to eight months in



**Fig. 4.** Golde scores in IPF patients categorized by disease stage. The break on the vertical axis indicates the upper limit of normal (both smoking and non-smoking healthy controls) Golde score values. Data are reported as median and 25th and 75th percentiles are indicated. Chi-square trend test  $p = 0.0027$ .

normal subjects and that it takes twice as long in tobacco smokers and more than six times longer in IPF patients [34]. This suggests that patients with fibrotic disorders clear iron particle very slowly from the lower respiratory tract.

Studies of the health effects of tobacco smoke indicate that smoking cessation after the age of 35–45 years does not completely protect from tobacco smoke-associated mortality in later ages [8] thus suggesting that, as with cardiovascular disease, smoke exposure may cause early vascular abnormalities in the lung which may persist after smoke cessation and antedate pulmonary fibrosis [50]. Iron-laden macrophages are observed in a variety of conditions of pulmonary occult hemorrhage, including congestive heart failure and mitral valve regurgitation [57], idiopathic pulmonary hemosiderosis [52], diffuse alveolar damage [29] and in pulmonary veno-occlusive disease (PVOD), a tobacco smoke-associated form of pulmonary hypertension [36].

Since the early studies on vascular abnormalities in IPF carried out by M. Turner-Warwick [59], a number of investigations have emphasized the association of IPF with pulmonary hypertension [37] and with small vessel abnormalities such as increased alveolar septal capillary density (ASCD), increased microvessel density, pulmonary capillary hemangiomatosis (PCH) and PVOD [9,28,48], all abnormalities associated with accumulation of hemosiderin-laden macrophages [6,21,25,43].

From a diagnostic viewpoint, given the elevated risk of morbidity and mortality associated with lung biopsy in pulmonary hypertension, and in PVOD in particular, the assessment of iron stain-positive lung macrophages recovered by BAL has been recommended as a safe surrogate marker for PVOD [36], and further studies toward its use in IPF would be of merit.

On the other hand, the data are consistent with and support the evaluation of vasoactive drugs in IPF, antagonists of the endothelin receptors, including the A-B receptor antagonist Bosentan and the selective endothelin A receptor antagonist Ambrisentan. Neither showed efficacy in clinical trials of IPF patients without [22,23] or with pulmonary hypertension [45]. The latter study though showed increased respiratory adverse events, loss of pulmonary function, increased hospitalization and mortality, possibly related to the presence of vascular alterations such as PCH and PVOD, characterized, by a poor response to vasodilators [35]. A phase II study of the tyrosine kinase receptor inhibitor Nintedanib has been recently completed [49]. Nintedanib is endowed with triple inhibitory activity against vascular endothelial growth factor (VEGF), platelet-derived growth factor (PDGF) and fibroblast growth factor (FGF) receptors, and has shown potent angiostatic activity both in vitro and ex vivo studies [15]. This study showed reduction in the decline in lung function and in the frequency of acute IPF exacerbations. In the context of the above, it is enticing to speculate that inhibition of angiogenesis in IPF might effectively modify disease course by limiting the formation of aberrant capillaries in the not yet fibrotic lung, hence preventing disease progression.

On the other hand, iron accumulation in the lung of experimental animals has been associated with increased oxidative stress, leading to fibrotic changes [11]. In IPF patients, although iron accumulation in the lower respiratory tract was not taken into account, Cantin et al. showed exaggerated spontaneous production of oxygen radicals by alveolar macrophages [5], findings that were confirmed in subsequent studies [2]. Anti-oxidants have been shown to dampen lung oxidative stress both when aerosolized [4] and administered systemically [32], as shown by the Ifigenia trial, demonstrating the efficacy of systemic anti-oxidant treatment added onto standard immunosuppressive therapy [7]. Pirfenidone, an anti-fibrotic drug recently shown to decelerate functional deterioration in IPF patients [1,40], has been shown in animal models to be a potent anti-oxidant [51].

In conclusion, the observation described here strongly suggests that the cytochemical finding of iron-laden macrophages in BAL may be a useful marker of vascular damage, including PVOD, in IPF and be helpful in directing and assessing treatment. Furthermore, being iron accumulation a marker of risk of oxidative stress reactions, the observation warrants further research for more potent anti-oxidant for the treatment of IPF.

## Acknowledgments

The Authors would like to thank, P. Rogliani for invaluable help with patient evaluation and and M. Pallante for assistance with data management.

## References

- [1] Azuma A, Nukiwa T, Tsuboi E, Suga M, Abe S, Nakata K, et al. Double-blind, placebo-controlled trial of pirfenidone in patients with idiopathic pulmonary fibrosis. *Am J Respir Crit Care Med* 2005;171:1040–7.
- [2] Bargagli E, Olivieri C, Bennett D, Prasse A, Muller-Quernheim J, Rottoli P. Oxidative stress in the pathogenesis of diffuse lung diseases: a review. *Respir Med* 2009;103:1245–56.
- [3] Baumgartner KB, Samet JM, Stidley CA, Colby TV, Waldron JA. Cigarette smoking: a risk factor for idiopathic pulmonary fibrosis. *Am J Respir Crit Care Med* 1997;155:242–8.
- [4] Borok Z, Buhl R, Grimes GJ, Bokser AD, Hubbard RC, Holroyd KJ, et al. Effect of glutathione aerosol on oxidant-antioxidant imbalance in idiopathic pulmonary fibrosis. *Lancet* 1991;338:215–6.
- [5] Cantin AM, North SL, Fells GA, Hubbard RC, Crystal RG. Oxidant-mediated epithelial cell injury in idiopathic pulmonary fibrosis. *J Clin Invest* 1987;79:1665–73.
- [6] Colombat M, Mal H, Groussard O, Capron F, Thabut G, Jebrak G, et al. Pulmonary vascular lesions in end-stage idiopathic pulmonary fibrosis: histopathologic study on lung explant specimens and correlations with pulmonary hemodynamics. *Hum Pathol* 2007;38:60–5.
- [7] Demedts M, Behr J, Buhl R, Costabel U, Dekhuijzen R, Jansen HM, et al. IFIGENIA Study Group. High-dose acetylcysteine in idiopathic pulmonary fibrosis. *N Engl J Med* 2005;353:2229–42.
- [8] Doll R, Peto R, Boreham J, Sutherland I. Mortality in relation to smoking: 50 years' observations on male British doctors. *BMJ* 2004;328:1519.
- [9] Ebina M, Shimizukawa M, Shibata N, Kimura Y, Suzuki T, Endo M, et al. Heterogeneous increase in CD34-positive alveolar capillaries in idiopathic pulmonary fibrosis. *Am J Respir Crit Care Med* 2004;169:1203–8.
- [10] Epstein CE, Elidemir O, Colasurdo GN, Fan LL. Time course of hemosiderin production by alveolar macrophages in a murine model. *Chest* 2001;120:2013–20.
- [11] Ghio AJ, Jaskot RH, Hatch GE. Lung injury after silica instillation is associated with an accumulation of iron in rats. *Am J Physiol* 1994;267:L686–92.
- [12] Ghio AJ, Richards JH, Dittrich KL, Samet JM. Metal storage and transport proteins increase after exposure of the rat lung to an air pollution particle. *Toxicol Pathol* 1998;26:388–94.
- [13] Ghio AJ, Stonehuerner J, Quigley DR. Humic-like substances in cigarette smoke condensate and lung tissue of smokers. *Am J Physiol* 1994;266:L382–8.
- [14] Golde DW, Drew WL, Klein HZ, Finley TN, Cline MJ. Occult pulmonary haemorrhage in leukaemia. *Br Med J* 1975;2:166–8.
- [15] Hilberg F, Roth GJ, Krssak M, Kautschitsch S, Sommergruber W, Tontschgrunt U, et al. BIBF 1120: triple angiokinase inhibitor with sustained receptor blockade and good antitumor efficacy. *Cancer Res* 2008;68:4774–82.
- [16] Hubbard R, Cooper M, Antoniak M, Venn A, Khan S, Johnston I, et al. Risk of cryptogenic fibrosing alveolitis in metal workers. *Lancet* 2000;355:466–7.
- [17] Iwai K, Mori T, Yamada N, Yamaguchi M, Hosoda Y. Idiopathic pulmonary fibrosis. Epidemiologic approaches to occupational exposure. *Am J Respir Crit Care Med* 1994;150:670–5.
- [18] Joppa P, Petrasova D, Stancak B, Tkacova R. Systemic inflammation in patients with COPD and pulmonary hypertension. *Chest* 2006;130:326–33.
- [19] Kamp DW, Israbian VA, Yeldandi AV, Panos RJ, Graceffa P, Weitzman SA. Phytic acid, an iron chelator, attenuates pulmonary inflammation and fibrosis in rats after intratracheal instillation of asbestos. *Toxicol Pathol* 1995;23:689–95.
- [20] Kawabata Y, Hoshi E, Murai K, Ikeya T, Takahashi N, Saitou Y, et al. Smoking-related changes in the background lung of specimens resected for lung cancer: a semiquantitative study with correlation to postoperative course. *Histopathology* 2008;53:707–14.
- [21] Kim K-H, Maldonado F, Ryu JH, Eiken PW, Hartman TE, Bartholmai BJ, et al. Iron deposition and increased alveolar septal capillary density in nonfibrotic lung tissue are associated with pulmonary hypertension in idiopathic pulmonary fibrosis. *Respir Res* 2010a;11:37.
- [22] King Jr TE, Behr J, Brown KK, du Bois RM, Lancaster L, de Andrade JA, et al. BUILD-1: a randomized placebo-controlled trial of bosentan in idiopathic pulmonary fibrosis. *Am J Respir Crit Care Med* 2008;177:75–81.

- [23] King Jr TE, Brown KK, Raghu G, du Bois RM, Lynch DA, Martinez F, et al. BUILD-3: a randomized, controlled trial of bosentan in idiopathic pulmonary fibrosis. *Am J Respir Crit Care Med* 2011;184:92–9.
- [24] LaLonde C, Ikegami K, Demling R. Aerosolized deferoxamine prevents lung and systemic injury caused by smoke inhalation. *J Appl Physiol Bethesda Md* 1994;1985(77):2057–64.
- [25] Lantuéjoul S, Sheppard MN, Corrin B, Burke MM, Nicholson AG. Pulmonary veno-occlusive disease and pulmonary capillary hemangiomatosis: a clinicopathologic study of 35 cases. *Am J Surg Pathol* 2006;30:850–7.
- [26] Ley B, Ryerson CJ, Vittinghoff E, Ryu JH, Tomassetti S, Lee JS, et al. A multidimensional index and staging system for idiopathic pulmonary fibrosis. *Ann Intern Med* 2012;156:684–91.
- [27] Macintyre N, Crapo RO, Viegi G, Johnson DC, van der Grinten CPM, Brusasco V, et al. Standardisation of the single-breath determination of carbon monoxide uptake in the lung. *Eur Respir J Off J Eur Soc Clin Respir Physiol* 2005;26:720–35.
- [28] Magro CM, Waldman WJ, Knight DA, Allen JN, Nadasdy T, Frambach GE, et al. Idiopathic pulmonary fibrosis related to endothelial injury and anti-endothelial cell antibodies. *Hum Immunol* 2006;67:284–97.
- [29] Maldonado F, Parambil JG, Yi ES, Decker PA, Ryu JH. Haemosiderin-laden macrophages in the bronchoalveolar lavage fluid of patients with diffuse alveolar damage. *Eur Respir J Off J Eur Soc Clin Respir Physiol* 2009;33:1361–6.
- [30] McGowan SE, Henley SA. Iron and ferritin contents and distribution in human alveolar macrophages. *J Lab Clin Med* 1988;111:611–7.
- [31] McLaughlin RF, Tueller EE. Anatomic and histologic changes of early emphysema. *Chest* 1971;59:592–9.
- [32] Meyer A, Buhl R, Kampf S, Magnussen H. Intravenous N-acetylcysteine and lung glutathione of patients with pulmonary fibrosis and normals. *Am J Respir Crit Care Med* 1995;152:1055–60.
- [33] Meyer KC, Raghu G, Baughman RP, Brown KK, Costabel U, du Bois RM, et al. An official American Thoracic Society clinical practice guideline: the clinical utility of bronchoalveolar lavage cellular analysis in interstitial lung disease. *Am J Respir Crit Care Med* 2012;185:1004–14.
- [34] Möller W, Barth W, Kohlhäufel M, Häussinger K, Stahlhofen W, Heyder J. Human alveolar long-term clearance of ferromagnetic iron oxide microparticles in healthy and diseased subjects. *Exp Lung Res* 2001;27:547–68.
- [35] Montani D, Achouh L, Dorfmueller P, Le Pavec J, Sztrymf B, Tchérakian C, et al. Pulmonary veno-occlusive disease: clinical, functional, radiologic, and hemodynamic characteristics and outcome of 24 cases confirmed by histology. *Medicine (Baltimore)* 2008;87:220–33.
- [36] Montani D, Price LC, Dorfmueller P, Achouh L, Jaïs X, Yaïci A, et al. Pulmonary veno-occlusive disease. *Eur Respir J* 2009;33:189–200.
- [37] Nathan SD, Shlobin OA, Ahmad S, Koch J, Barnett SD, Ad N, et al. Serial development of pulmonary hypertension in patients with idiopathic pulmonary fibrosis. *Respir Int Rev Thorac Dis* 2008;76:288–94.
- [38] Nathan SD, Shlobin OA, Barnett SD, Sagar Rajeev, Belperio JA, Ross DJ, et al. Right ventricular systolic pressure by echocardiography as a predictor of pulmonary hypertension in idiopathic pulmonary fibrosis. *Respir Med* 2008;102:1305–10.
- [39] Nelson ME, O'Brien-Ladner AR, Wesselius IJ. Regional variation in iron and iron-binding proteins within the lungs of smokers. *Am J Respir Crit Care Med* 1996;153:1353–8.
- [40] Noble PW, Albera C, Bradford WZ, Costabel U, Glassberg MK, Kardatzke D, et al. Pirfenidone in patients with idiopathic pulmonary fibrosis (CAPACITY): two randomised trials. *Lancet* 2011;377:1760–9.
- [41] Olakanmi O, McGowan SE, Hayek MB, Britigan BE. Iron sequestration by macrophages decreases the potential for extracellular hydroxyl radical formation. *J Clin Invest* 1993;91:889–99.
- [42] Pinho RA, Silveira PCL, Silva LA, Luiz Streck E, Dal-Pizzol F, Moreira F, et al. N-acetylcysteine and deferoxamine reduce pulmonary oxidative stress and inflammation in rats after coal dust exposure. *Environ Res* 2005;99:355–60.
- [43] Rabiller A, Jaïs X, Hamid A, Resten A, Parent F, Haque R, et al. Occult alveolar haemorrhage in pulmonary veno-occlusive disease. *Eur Respir J* 2006;27:108–13.
- [44] Rad AM, Janic B, Iskander ASM, Soltanian-Zadeh H, Arbab AS. Measurement of quantity of iron in magnetically labeled cells: comparison among different UV/VIS spectrometric methods. *BioTechniques* 2007;43:627–8. 630, 632 passim.
- [45] Raghu G, Behr J, Brown KK, Egan JJ, Kawut SM, Flaherty KR, et al. ARTEMIS-IPF Investigators\*. Treatment of idiopathic pulmonary fibrosis with ambrisentan: a parallel, randomized trial. *Ann Intern Med* 2013;158:641–9.
- [46] Raghu G, Collard HR, Egan JJ, Martinez FJ, Behr J, Brown KK, et al. An official ATS/ERS/JRS/ALAT statement: idiopathic pulmonary fibrosis: evidence-based guidelines for diagnosis and management. *Am J Respir Crit Care Med* 2011;183:788–824.
- [47] Rennard SI, Basset G, Lecossier D, O'Donnell KM, Pinkston P, Martin PG, et al. Estimation of volume of epithelial lining fluid recovered by lavage using urea as marker of dilution. *J Appl Physiol Bethesda Md* 1986;1985(60):532–8.
- [48] Renzoni EA, Walsh DA, Salmon M, Wells AU, Sestini P, Nicholson AG, et al. Interstitial vascularity in fibrosing alveolitis. *Am J Respir Crit Care Med* 2003;167:438–43.
- [49] Richeldi L, Costabel U, Selman M, Kim DS, Hansell DM, Nicholson AG, et al. Efficacy of a tyrosine kinase inhibitor in idiopathic pulmonary fibrosis. *N Engl J Med* 2011;365:1079–87.
- [50] Robinson K, Conroy RM, Mulcahy R. When does the risk of acute coronary heart disease in ex-smokers fall to that in non-smokers? A retrospective study of patients admitted to hospital with a first episode of myocardial infarction or unstable angina. *Br Heart J* 1989;62:16–9.
- [51] Salazar-Montes A, Ruiz-Corro L, López-Reyes A, Castrejón-Gómez E, Armendariz-Borunda J. Potent antioxidant role of pirfenidone in experimental cirrhosis. *Eur J Pharmacol* 2008;595:69–77.
- [52] Salih ZN, Akhter A, Akhter J. Specificity and sensitivity of hemosiderin-laden macrophages in routine bronchoalveolar lavage in children. *Arch Pathol Lab Med* 2006;130:1684–6.
- [53] Saltini C, Hance AJ, Ferrans VJ, Basset F, Bitterman PB, Crystal RG. Accurate quantification of cells recovered by bronchoalveolar lavage. *Am Rev Respir Dis* 1984;130:650–8.
- [54] Samara KD, Margaritopoulos G, Wells AU, Siafakas NM, Antoniou KM. Smoking and pulmonary fibrosis: novel insights. *Pulm Med* 2011;2011:461439.
- [55] Sherman JM, Winnie G, Thomassen MJ, Abdul-Karim FW, Boat TF. Time course of hemosiderin production and clearance by human pulmonary macrophages. *Chest* 1984;86:409–11.
- [56] Steele MP, Speer MC, Loyd JE, Brown KK, Herron A, Shifer SH, et al. Clinical and pathologic features of familial interstitial pneumonia. *Am J Respir Crit Care Med* 2005;172:1146–52.
- [57] Taylor HE, Strong GF. Pulmonary hemosiderosis in mitral stenosis. *Ann Intern Med* 1955;42:26–35.
- [58] Thompson AB, Bohling T, Heires A, Linder J, Rennard SI. Lower respiratory tract iron burden is increased in association with cigarette smoking. *J Lab Clin Med* 1991;117:493–9.
- [59] Turner-Warwick M. Precapillary systemic-pulmonary anastomoses. *Thorax* 1963;18:225–37.