

# CHEST<sup>®</sup>

THE CARDIOPULMONARY  
AND CRITICAL CARE JOURNAL

FOR PULMONOLOGISTS, CARDIOLOGISTS, CARDIOTHORACIC SURGEONS,  
CRITICAL CARE PHYSICIANS, AND RELATED SPECIALISTS

## **Alveolar Hemorrhage in Systemic Lupus Erythematosus : Presentation and Management**

Alberto S. Santos-Ocampo, Brian F. Mandell and Barri J. Fessler

*Chest* 2000;118:1083-1090

DOI: 10.1378/chest.118.4.1083

**This information is current as of August 18, 2006**

The online version of this article, along with updated information and services, is located on the World Wide Web at:

<http://www.chestjournal.org/cgi/content/full/118/4/1083>

CHEST is the official journal of the American College of Chest Physicians. It has been published monthly since 1935. Copyright 2005 by the American College of Chest Physicians, 3300 Dundee Road, Northbrook IL 60062. All rights reserved. No part of this article or PDF may be reproduced or distributed without the prior written permission of the copyright holder. ISSN: 0012-3692.

A M E R I C A N C O L L E G E O F  
 C H E S T  
P H Y S I C I A N S

# Alveolar Hemorrhage in Systemic Lupus Erythematosus\*

## Presentation and Management

Alberto S. Santos-Ocampo, MD; Brian F. Mandell, MD, PhD; and Barri J. Fessler, MD

**Aim:** To describe our experience with alveolar hemorrhage (AH) in systemic lupus erythematosus (SLE).

**Methods:** Review of medical records and pertinent medical literature using MEDLINE and reference lists from retrieved publications.

**Patients:** Seven patients with SLE admitted with episodes of AH (n = 11).

**Results:** Six patients were female, and one was male. Mean age at the time of AH was 31.1 years. Mean duration of SLE was 4.5 years. AH occurred within 3 weeks of SLE onset in two patients. Recurrent AH was observed in four patients. Six patients were already receiving treatment for SLE at the time of AH. All patients presented with dyspnea and new pulmonary infiltrates. Hemoptysis occurred in only 54%. All patients had BAL within 48 h of presentation. Temperature  $\geq 39^{\circ}\text{C}$  ( $102.2^{\circ}\text{F}$ ) accompanied 82% of episodes. Glomerulonephritis was the most common nonpulmonary SLE manifestation (74%). Treatment with empiric IV antibiotics was initiated in 10 episodes. Initial treatment included high-dose corticosteroids (prednisone, 1 to 3 mg/kg/d [n = 2]; or IV methylprednisolone, 1 g/d [n = 9], with or without oral cyclophosphamide, 2 to 3 mg/kg/d [n = 7]). Plasmapheresis (three to four sessions) was added in five episodes for persistent AH. All patients survived.

**Conclusions:** AH may mimic pneumonia. Hemoptysis may not be evident. Infection must be aggressively excluded, especially since many patients with AH are already receiving immunosuppressive therapy. AH frequently recurs despite ongoing immunosuppression. Although high mortality rates have been reported with AH in SLE, we observed 100% survival.

(*CHEST* 2000; 118:1083–1090)

**Key words:** alveolar hemorrhage; pulmonary hemorrhage; systemic lupus erythematosus

**Abbreviations:** AH = alveolar hemorrhage; ALP = acute lupus pneumonitis; DLCO = diffusing capacity of the lung for carbon monoxide; SLE = systemic lupus erythematosus

Alveolar hemorrhage (AH) is a potentially catastrophic complication of systemic lupus erythematosus (SLE). Among the rheumatologic diseases, AH most frequently occurs in patients with SLE and the systemic vasculitides.<sup>1–3</sup> It is an uncommon complication, with frequency estimates ranging from < 2 to 5.4% in cohorts of lupus patients.<sup>4–12</sup> It accounts for 1.5

to 3.7% of hospital admissions due to SLE.<sup>6,9</sup> AH is frequently fatal, with reported mortality rates of 23 to 92%.<sup>4–12</sup> Only three previous case series of SLE-associated AH have described survival rates of  $\geq 50\%$ ,<sup>7,8,11</sup> with the highest being 75%.<sup>8</sup>

In this article, we summarize the course of seven consecutive patients admitted to the hospital between January 1993 and July 1998 for 11 episodes of SLE-associated AH. We compare our experience with reports from the medical literature.

Patients who were admitted to the Cleveland Clinic Foundation from January 1993 to July 1998 with *International Classification of Diseases, Ninth Revision* diagnoses of hemoptysis or pulmonary hemorrhage were identified for chart review for inclusion into this study. Patients needed to fulfill the American College of Rheumatology revised 1982 criteria for the diagnosis of SLE.

\*From the Department of Medicine (Dr. Santos-Ocampo), Makati Medical Center, Makati City, Philippines; the Department of Rheumatic and Immunologic Disease (Dr. Mandell), Cleveland Clinic Foundation, Cleveland, OH; and the Division of Rheumatology (Dr. Fessler), University of Alabama at Birmingham, Birmingham, AL.

Manuscript received December 3, 1999; revision accepted May 12, 2000.

Correspondence to: Brian F. Mandell, MD, PhD, Department of Rheumatic and Immunologic Disease, A50, Cleveland Clinic Foundation, 9500 Euclid Ave, Cleveland, OH 44195; e-mail: mandellb@ccf.org

## MATERIALS AND METHODS

We performed a retrospective review of the medical records of patients meeting the preliminary inclusion criteria. Cases of AH confirmed by demonstration of a bloody return on BAL with hemosiderin-containing macrophages were selected.

It was predefined that patients would be excluded if they had drug-induced lupus, coagulopathies (international normalized ratio > 3.5 s in patients receiving warfarin, severe chronic liver disease, end-stage renal disease receiving dialysis), pulmonary edema from cardiogenic or noncardiogenic causes, or bleeding pulmonary malignancies.

### *Definition of Terms and Data Collection*

Onset of AH was defined as the earliest date when pulmonary symptoms (acute or recent development of dyspnea, hemoptysis) correlated with objective clinical findings (chest radiographs demonstrating new pulmonary infiltrates or a drop in hemoglobin level of at least 0.5 g/dL).

Duration of AH was based on the time between onset of AH to the first of 2 consecutive days when the patient's hematocrit (obtained at least daily) remained stable without need of transfusion. Survival was defined as the resolution of all symptoms related to AH and discharge to home in stable condition.

Data tabulated included SLE disease characteristics prior to the episode of AH, pertinent symptoms and laboratory findings accompanying each episode, and details on treatment regimens.

### *Literature Review*

A MEDLINE search of English-language articles on SLE-associated AH was obtained using the search terms *pulmonary hemorrhage*, *alveolar hemorrhage*, and *systemic lupus erythematosus*. Reference lists from all articles were also reviewed.

## RESULTS

Between January 1993 and July 1998, seven patients with 11 episodes of pulmonary hemorrhage met criteria for inclusion. These 7 patients represented 1.0% (7 of 663) of patients with SLE admitted or referred to the Cleveland Clinic Foundation with a listed diagnosis of SLE. Eight of 11 episodes occurred in the spring (n = 4) and summer (n = 4). There was no statistically significant pattern of seasonal occurrence.

### *Patient Characteristics*

Patient demographics are summarized in Table 1. Six patients were female (five white and one African American), and one patient was male (white). The mean age at the time of AH was 31.1 years (range, 19 to 44 years). Mean duration of SLE was 4.5 years (range, 2 weeks to 19 years).

Several findings are noteworthy: (1) Recurrent AH was observed in four patients. Intervals between episodes were 2, 5, 9, and 28 weeks, respectively. (2) Ten of the 11 episodes occurred in patients already receiving treatment for manifestations of SLE. Pred-

nison (dose range, 3 to 60 mg/d) had been prescribed for other manifestations of SLE at the time of AH in nine episodes. Other treatments being received at the onset of AH included the following: cyclophosphamide (pulse IV monthly doses of 750 mg/m<sup>2</sup> in two episodes of AH, or an oral dose of 50 mg/d in one episode), azathioprine (50 to 200 mg/d) in two episodes, methotrexate (7.5 mg/wk) in one episode, and hydroxychloroquine (200 mg bid) in three episodes. (3) AH occurred in two patients within 1 month of onset of SLE (patients 3, 5). (4) The spectrum of SLE patient characteristics varied greatly. AH occurred in patients whose SLE was previously characterized as mild disease (arthralgias, alopecia, and discoid lupus), and patients who had a history of aggressive disease (nephritis). The risk of developing AH could not be predicted based on prior disease activity.

### *Clinical Presentation*

Dyspnea and new pulmonary infiltrates were present in all episodes. Oral temperature  $\geq 39^{\circ}\text{C}$  ( $102.2^{\circ}\text{F}$ ) was present in 82% of episodes, while hemoptysis was seen in only 54%. The high frequency of fever and absence of hemoptysis at the time of presentation made the initial distinction between AH and pulmonary infection difficult.

Table 2 illustrates the frequencies of extrapulmonary SLE disease manifestations in patients with AH. Milder manifestations of SLE, such as alopecia, malar rash, oral ulcers, and arthralgias, were less commonly noted during the episode of AH. Clinical nephritis, defined by the presence of cellular casts in the urine, was more commonly observed during the episodes of AH (64%), compared to the period prior to the first episode of AH (28%).

### *Laboratory and Radiographic Findings*

A drop in hemoglobin > 1.0 g/dL between clinical onset of AH and time of bronchoscopic confirmation occurred in 91% of episodes. Erythrocyte sedimentation rates or C-reactive protein levels from patients were normal in three of the eight episodes in which they were obtained.

The most common radiographic pattern in our series was bilateral alveolar-interstitial infiltrates (82%; 9 of 11 episodes). Unilateral densities, which could be easily mistaken for lobar pneumonia, were seen in the remaining two episodes (Fig 1). Pleural effusions were present in 27% of episodes.

Bronchoscopy with BAL was performed within 48 h of hospital admission. The percentage of neutrophils ranged from 30 to 91%, and the percentage of lymphocytes ranged from 0 to 8%. Monocytes and macrophages comprised 1 to 45% of the differential

**Table 1—Patient Characteristics in 11 Episodes of SLE-Associated AH\***

Patient	Episode	Age, † yr	Sex	Duration of SLE, mo	Outpatient SLE Therapy Prior to AH	SLE Manifestations Prior to AH
1	1	43	F	18	None	Malar rash, oral ulcers, arthralgias, lymphadenopathies, low C3, C4, pancytopenias, anti-dsDNA, anti-RNP, anti-Smith antibodies
2	2	27	F	12	Pred, 40 mg/d	Alopecia, cytopenias, arthralgias, prior CVA from APS, low C4, (+) speckled ANA (> 1:640)
	3	28		19	Pred, 40 mg/d AZA, 200 mg/d HCQ, 200 mg bid	Same
3	4	19	F	0.5	Pred, 100 mg every other d Pulse IV CYC	DPGN (WHO class IV), malar rash, oral ulcers, alopecia, serositis, low C3, C4, anti-dsDNA (+)
4	5	38	M	72	Pred, 60 mg/d	Malar rash, cutaneous vasculitis, arthralgias, profound weight loss, low C3, C4, pancytopenias, Anti-dsDNA (+)
	6	39		73	Pred, 60 mg/d AZA, 50 mg/d HCQ, 200 mg bid	Same
5	7	19	F	0.75	Pred, 60 mg/d Pulse IV CYC	DPGN (WHO class IV), malar rash, arthritis, profound weight loss, pancytopenias; low C3, C4, ANA (+), homogenous pattern
	8	19		1.25	Pred, 60 mg/d CYC, 50 mg/d	Same
6	9	35	F	120	Pred, 3 mg/d MTX, 7.5 mg/wk HCQ, 200 mg bid	Discoid lupus, alopecia, arthritis, low C3, C4, leukopenia, (+) speckled ANA (> 1:640)
	10	35		122	Pred, 60 mg/d	Same
7	11	44	F	228	HCQ, 200 mg bid	Arthralgias, low C3, C4, cytopenias, APS, (+) speckled ANA (> 1:640)

\*F = female; M = male; C = complement; APS = antiphospholipid syndrome; DPGN = diffuse proliferative glomerulonephritis; WHO = World Health Organization classification system for lupus glomerulonephritis; Pred = prednisone; CYC = cyclophosphamide; MTX = methotrexate; HCQ = hydroxychloroquine; AZA = azathioprine; CVA = cerebral vascular accident; ANA = antinuclear antibodies; anti-dsDNA = antibodies to double-stranded DNA; anti-RNP = antibodies to U1RNP protein antigens.

†Age at the time of episode.

cell count. Hemosiderin-laden or pigment-laden macrophages were seen in all fluids. Routine bacterial and fungal culture results were negative from all the initial blood, sputum, and BAL cultures. One patient (patient 4) had cytomegalovirus detected in his BAL fluid. This was believed to be viral colonization, and his condition improved despite not receiving any cytomegalovirus-specific therapy. Lung biopsies were not routinely done. In the two episodes in which transbronchial biopsy was performed, pathologic examination revealed pulmonary capillaritis with AH and hemosiderin-laden macrophages. No pulmonary vasculitis was observed.

#### Treatment and Outcomes

All seven patients in the current series survived their episodes of AH. One patient (patient 3) was unavailable for follow-up 1 month after her episode of AH. She was described as being free of pulmonary symptoms at her final outpatient visit. Follow-up ranged from 2 to 22 months following the last episode of AH in the remaining six patients.

Mechanical ventilation was needed during four episodes of AH. Doses of corticosteroids that were much higher than baseline were used to treat all episodes of AH. Most patients were already receiving significant doses of prednisone prior to onset of AH. IV pulses of methylprednisolone were provided in 9 of 11 episodes. These were administered in doses of 240 to 1,000 mg/d for a minimum of 3 days. Repeat pulses within 1 week of the first pulse were provided in two episodes (patients 1, 6) because of persistent AH.

Daily cytotoxic drug therapy (cyclophosphamide) was often started concurrently with steroids. In two episodes (patients 4, 6), cyclophosphamide administration was delayed because of marked leukopenia. The preferred dose of cyclophosphamide was 2 to 5 mg/kg/d (IV or oral), with subsequent dose adjustments made on the seventh through 14th days, based in part on leukocyte counts. Plasmapheresis was added in 5 of 11 episodes because of persistent AH, despite high-dose corticosteroid and cytotoxic therapy. The inclusion and timing of plasmapheresis was

**Table 2—Characteristics and Clinical Presentation of Patients with SLE-Associated AH (Current and Selected Case Series From 1985 to Present)\***

Variables	Current Series	Abud-Mendoza et al <sup>6</sup>	Myers and Katzenstein <sup>7</sup>	Schwab et al <sup>8</sup>	Zamora et al <sup>9</sup>	Barile et al <sup>10</sup>	Koh et al <sup>11</sup>	Liu et al <sup>12</sup>
Patient characteristics								
Patients, No.	7	12	4	8	15	34	10	13
% of SLE cohort	1	1.6	—	1.4	3.7	5.4	1.4	4
Male/female, No.	1/6	0/12	3/1	2/6	5/10	2/32	2/8	1/12
Mean age, yr	31.1	23	29	37.8	30.1	34.5	26.5	26
Range, yr	19–44	16–40	13–51	17–54	19–44	—	13–44	10–50
Mean duration of SLE, yr	4.5	2	—	2.3	2.5	14.1	1.8	1.9
Range, yr	2 wk–19 yr	0.1–5	—	0.1–7	0–8	—	0–5	4 wk–5 yr
(+) anti-dsDNA, %	43	25	75	87.5	—	88	50	61
Presenting signs and symptoms of AH, % of episodes								
Hemoptysis	50	25	75	100	42	58	30	84
New radiograph infiltrates	100	83	100	87	100	100	100	100
Alveolo-interstitial	80	83	100	—	100	—	100	—
Lobar	20	—	0	12	0	—	0	—
Bilateral	80	—	100	—	100	—	—	100
Unilateral	20	—	0	12	0	—	—	—
Pleural effusions	30	—	—	—	37	—	—	—
Anemia	90	100	—	75	94	91	100	100
Dyspnea	100	25	87	73	—	100	—	100
Fever	80	25	25	100	26	—	90	54
Chest pain	30	—	—	—	—	—	20	—
Extrapulmonary signs and symptoms accompanying AH, % of episodes								
Renal-nephritis	70	41	—	62	93	32	40	100
Hematologic								
Leukopenia	30	50	—	—	0	—	20	23
Thrombocytopenia	20	—	—	—	31	—	—	61
AIHA	—	—	—	—	—	—	—	—
Skin-mucositis	0	41	—	62	73	47	70	38
Arthralgias-arthritis	10	16	—	62	15	44	30	15
Neuropsychiatric lupus	10	58	—	37	47	14	20	61
Low complements	83	25	75	100	—	—	70	84

\*— = not stated; AIHA = autoimmune hemolytic anemia; see Table 1 for abbreviation.

highly variable and dependent on the intensive care staff and the consulting rheumatologist. The number of plasmapheresis sessions per episode ranged from three to four.

Treatment with broad-spectrum antibiotics was started empirically together with intensified corticosteroid therapy in 10 of 11 episodes while initial blood, sputum, and BAL cultures were pending. All results of cultures collected prior to starting antibiotic therapy were negative. Antibiotics therapy was withdrawn after 1 to 5 days if the patient was not receiving mechanical ventilation. In patients who were intubated, antibiotic therapy was continued for the duration of mechanical ventilation (range, 3 to 14 days).

The mean duration of AH was 7 days (range, 2 to 21 days). In cases in which chest radiographs were serially obtained, the mean duration from onset to radiographic resolution was 7.8 days (range, 5 to 11 days).

All patients were discharged from the hospital receiving high-dose corticosteroids (prednisone, 40 to 60 mg/d). Daily cyclophosphamide (seven episodes; range, 50 to 150 mg/d) or azathioprine (two episodes; range, 50 to 200 mg/d) was provided in nine episodes.

## DISCUSSION

Tables 2, 3 summarize the patient characteristics, clinical presentations, treatments, and outcomes from this series, compared with data from previously published reports. A central theme in the previously published literature is the high mortality rate seen with AH from SLE. Our observed patient survival of 100% is in marked contrast to most series, but reinforces the findings by Schwab et al,<sup>8</sup> that AH is a survivable complication of SLE.

Similar to most reports, most of our patients were

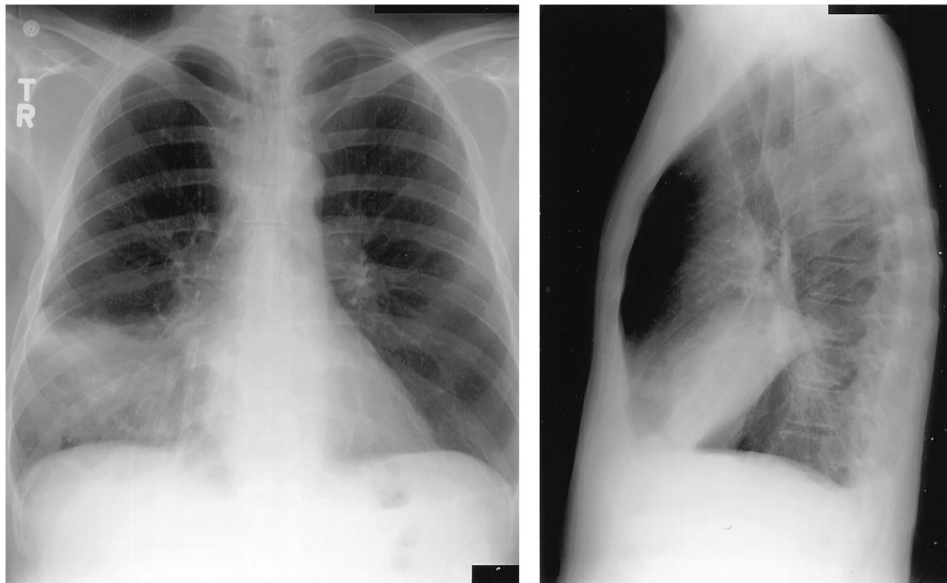


FIGURE 1. Posteroanterior and lateral chest radiograph from patient 4 demonstrating alveolar hemorrhage presenting as a right middle lobe consolidation.

young women with a wide variability in duration and severity of SLE prior to AH. While most patients have an established diagnosis of SLE, cases of AH as a presenting symptom or occurring very early in the evolution of SLE have been described elsewhere and in this series.<sup>2,4,13–15</sup>

The recurrent nature of AH was of concern, and this frequently occurred without warning. The occurrence of AH despite ongoing treatment with significant doses of immunosuppressive drugs must be noted.

Presentation of AH with the “classical triad” of hemoptysis, abrupt fall in hemoglobin level, and new pulmonary infiltrates described in earlier reports was

not uniformly seen in the current series, and confirms observations made by other authors (Table 2).<sup>6,9,14,16</sup> In the published literature, hemoptysis on presentation is reported with a frequency of 25 to 100%, compared to 54% in our series.<sup>6,16</sup> New pulmonary infiltrates (published frequency, 83 to 100%; 100% in the current series) accompanied by worsening or new anemia (published frequency, 75 to 100%; 100% in the current series) appear to be more sensitive clinical signs (Table 2).<sup>4–11</sup> Acute dyspnea, cough, rales, chest pain, tachypnea, and fever > 38°C (100.4°F) are frequently present, leading to diagnostic confusion with bacterial and opportunistic pulmonary infections.<sup>4,9,14,16,17</sup>

**Table 3—Therapies Used, Survival, and Outcomes of SLE-Associated AH (Current and Selected Case Series From 1985 to Present)\***

Variables	Current Series	Abud-Mendoza et al <sup>6</sup>	Myers et al <sup>7</sup>	Schwab et al <sup>8</sup>	Zamora et al <sup>9</sup>	Barile et al <sup>10</sup>	Koh et al <sup>11</sup>	Liu et al <sup>12</sup>
Acute treatment, % of episodes								
CS	100	83	100	100	78	100	100	100
CYC	70	8	25	62	68	5	80	15
AZA	0	16	0	0	26	0	0	—
PAP	40	—	25	12	36	5	40	—
VENT	30	—	75	50	68	59	80	77
ABX	90	—	—	75	—	94	100	—
Survival, %	100	8	50	75	46	38	60	23
Mean AH-free Follow-up, mo	7.8	—	—	20	30	2	22	—
Range, mo	1–22	—	—	0.5–48	1–108	0.1–8	3–108	—

\*CS = corticosteroids; PAP = plasmapheresis; VENT = mechanical ventilation; ABX = antibodies; see Table 1 for abbreviations.

Although many published series emphasize the simultaneous presence of multiple extrapulmonary manifestations of SLE,<sup>4–6,8–12,18</sup> our experience was different (Table 2). Milder manifestations (alopecia, rashes, arthritis, oral ulcers) may have been “masked” at the time of AH because of ongoing immunosuppressive therapy. The most frequent extrapulmonary manifestation accompanying AH in our series was nephritis, concordant with most published reports.<sup>4–12</sup> Serious manifestations such as nephritis accompanied AH despite antecedent therapy.

Serial hemoglobin levels and chest radiographs were helpful in diagnosing and documenting the evolution of AH.<sup>19</sup> In our experience, all patients with active AH had a drop in hemoglobin level that ranged from a drop of 1.1 g/dL to a maximal drop of 3.5 g/dL, accompanied by new pulmonary infiltrates.

Several radiographic patterns were seen, probably reflecting the location, extent, and duration of AH. Although classically described as a bilateral alveolar-interstitial filling pattern that is diffuse, bibasilar, or perihilar,<sup>2,4,5,7,13,14,20–34</sup> unilateral and lobar infiltrates have been reported (Table 2) and were observed in our series. None of these radiographic patterns are specific for AH.<sup>14,17</sup>

Since infection is a far more common cause of new pulmonary symptoms in patients with SLE, this must be aggressively excluded or empirically treated prior to intensifying immunosuppressive therapy for AH.<sup>14,35</sup> Treatment with broad-spectrum antibiotics was routinely started in our patients while initial culture results were pending. Early bronchoscopy with BAL provided a reliable means of demonstrating AH and collecting specimens for culture. Gross blood, hemosiderin-laden macrophages, absence of purulent sputum, and lack of an infectious organism by stain or culture of the BAL favor AH.<sup>8,36</sup> Although simultaneous pulmonary infection and lupus AH were not observed in our series, they may coexist. The hazards of withholding immunosuppression in AH or intensifying immunosuppression in the presence of a fulminant pulmonary infection are obvious.

Aside from pulmonary infections, other entities that may mimic the clinical presentation of AH in SLE include acute lupus pneumonitis (ALP), pulmonary embolism, uremic pneumonitis, bleeding from coagulopathies, and cardiogenic or noncardiogenic pulmonary edema. These topics have been reviewed elsewhere.<sup>9,10,14,16,17,26,30,35–39</sup>

The clinical utility of transbronchial biopsies was not determined in our small series. Pulmonary capillaritis with AH and hemosiderin-laden macrophages were seen in the two episodes (patients 2, 4) in which biopsies were done. One of these patients

(patient 2) was readmitted to the hospital 15 months after her last episode of AH with increasing dyspnea. Her course did not suggest AH or infection, and the BAL was nonbloody. Histopathologic findings on transbronchial biopsy specimens were consistent with ALP without AH. She was successfully treated by increasing her daily dose of prednisone. The presence of these two distinct pulmonary manifestations of SLE in the same patient at different times is intriguing. Can untreated ALP evolve into frank AH? ALP is responsive to high-dose steroids therapy,<sup>16,30,37</sup> whereas our experience has been that more intense immunosuppression with additional cytotoxic agents is needed to manage AH.

The finding of an elevated diffusing capacity of the lung for carbon monoxide (DLCO) has been used as an adjunctive test to diagnose AH.<sup>40</sup> The utility of DLCO was not assessed in our series. This technique may be helpful if the DLCO is measured within the first 48 h of AH, when extravasated RBCs are still present in the alveoli.<sup>18</sup> An increase in DLCO of 30% over baseline or a value of  $\geq 130\%$  predicted (in the absence of a baseline) is reportedly suggestive of AH.<sup>16,18,40–42</sup> In contrast, the DLCO in ALP is usually decreased.<sup>36</sup> Obtaining DLCO measurements, however, is not practical in the ICU setting at night or in the unstable, acutely ill patient.

Treatment regimens in our series varied between specific consultants. Corticosteroids were a mainstay of therapy, but additional immunosuppressive treatments and supportive ventilation were often required (Table 3). Antibiotic therapy was empirically started, since the initial clinical picture frequently resembled pneumonia. In general, IV methylprednisolone pulses were combined with cyclophosphamide, either simultaneously or after leukocyte counts in leukopenic patients improved. The necessity for such high doses of corticosteroids for AH in SLE remains to be proven, but IV methylprednisolone pulses have been used with success in other immune AH syndromes.<sup>42</sup> In contrast to the findings of Zamora et al,<sup>9</sup> daily oral cyclophosphamide and the requirement for mechanical ventilation did not adversely affect survival in our patients.

Plasmapheresis was added if the patients had an inadequate clinical response to high-dose corticosteroid and cyclophosphamide therapy. Although the hypothetical role of autoantibodies and the demonstration of tissue deposits of immune complexes by some investigators make this an attractive form of adjunctive therapy, proof of efficacy is unavailable.<sup>9,23</sup> Concerns with plasmapheresis include the theoretical risk of increased autoantibody synthesis as a “rebound phenomenon”<sup>43</sup> and line sepsis. The former may be minimized if a cytotoxic agent is used prior to initiating plasmapheresis. For this reason,

synchronization of cyclophosphamide before plasmapheresis has been suggested.<sup>8,23,24,33,42-44</sup> In our experience, plasmapheresis was added when patients continued to have AH despite receiving pulses of IV methylprednisolone and cyclophosphamide. We routinely provide plasmapheresis as part of initial therapy in cases of AH, in which the underlying diagnosis is not certain and anti-glomerular basement membrane disease is possible.

## CONCLUSION

AH is a serious manifestation of pulmonary SLE that may occur early or late in disease evolution. It is survivable, despite its frequently dramatic presentation. Extrapulmonary disease may be minimal and may be masked in patients who are already receiving immunosuppression for other symptoms of SLE. Predictors of patients at risk for this complication are unclear at this time. The capacity of AH to occur and recur despite ongoing immunosuppressive therapy is emphasized in this series. AH may present without hemoptysis. An aggressive diagnostic approach with prompt bronchoscopy to confirm the diagnosis and to help exclude infection is indicated, especially since timely intensification of immunosuppression is required and effective. Use of broad-spectrum antibiotics while awaiting initial culture results is prudent.

## REFERENCES

- 1 Muller NL, Miller RR. Diffuse pulmonary hemorrhage. *Radiol Clin North Am* 1991; 29:965-971
- 2 Primack SL, Miller RR, Muller NL. Diffuse pulmonary hemorrhage: clinical, pathologic, and imaging features. *AJR Am J Roentgenol* 1995; 164:295-300
- 3 Travis WD, Colby TV, Lombard C, et al. A clinicopathologic study of 34 cases of diffuse pulmonary hemorrhage with lung biopsy confirmation. *Am J Surg Pathol* 1990; 14:1112-1125
- 4 Eagen JW, Memoli VA, Roberts JL, et al. Pulmonary hemorrhage in systemic lupus erythematosus. *Medicine* 1978; 57:545-560
- 5 Mintz G, Galindo LF, Fernandez-Diaz J, et al. Acute massive pulmonary hemorrhage in systemic lupus erythematosus. *J Rheumatol* 1978; 5:39-50
- 6 Abud-Mendoza C, Diaz-Jouanan E, Alarcon-Segovia D. Fatal pulmonary hemorrhage in systemic lupus erythematosus: occurrence without hemoptysis. *J Rheumatol* 1985; 12:558-561
- 7 Myers JL, Katzenstein AL. Microangiitis in lupus-induced pulmonary hemorrhage. *Am J Clin Pathol* 1986; 85:552-556
- 8 Schwab EP, Schumacher HR, Freundlich B, et al. Pulmonary alveolar hemorrhage in systemic lupus erythematosus. *Semin Arthritis Rheum* 1993; 23:8-15
- 9 Zamora MR, Warner ML, Tuder R, et al. Diffuse alveolar hemorrhage and systemic lupus erythematosus: clinical presentation, histology, survival and outcome. *Medicine* 1997; 76:192-202
- 10 Barile LA, Jara LJ, Medina-Rodriguez F, et al. Pulmonary

- hemorrhage in systemic lupus erythematosus. *Lupus* 1997; 6:445-448
- 11 Koh WH, Thumboo J, Boey ML. Pulmonary hemorrhage in oriental patients with systemic lupus erythematosus. *Lupus* 1997; 6:713-716
- 12 Liu MF, Lee JH, Weng TH, et al. Clinical experience of 13 cases with severe pulmonary hemorrhage in systemic lupus erythematosus with active nephritis. *Scand J Rheumatol* 1998; 27:291-295
- 13 Wiedemann HP, Matthay RA. Pulmonary manifestations of the collagen vascular diseases. *Clin Chest Med* 1989; 10:677-722
- 14 Albelda SM, Geftter WB, Epstein DM, et al. Diffuse pulmonary hemorrhage: a review and classification. *Radiology* 1985; 154:289-297
- 15 Nadorra RL, Landing BH. Pulmonary lesions in childhood onset systemic lupus erythematosus: analysis of 26 cases and summary of literature. *Pediatr Pathol* 1987; 7:1-18
- 16 Harmon KR, Leatherman JW. Respiratory manifestations of connective tissue disease. *Semin Respir Infect* 1988; 3:258-273
- 17 Carette S, Macher AM, Nussbaum A, et al. Severe, acute pulmonary disease in patients with systemic lupus erythematosus: ten years of experience at the National Institutes of Health. *Semin Arthritis Rheum* 1984; 14:52-59
- 18 Dweik RA, Arroliga AC, Cash JM. Alveolar hemorrhage in patients with rheumatic disease. *Rheum Dis Clin North Am* 1997; 23:395-410
- 19 Leatherman JW. Immune alveolar hemorrhage. *Chest* 1987; 91:891-897
- 20 Onomura K, Nakata H, Tanaka Y, et al. Pulmonary hemorrhage in patients with systemic lupus erythematosus. *J Thorac Imaging* 1991; 6:57-61
- 21 Castaneda S, Herrero-Beaumont G, Valenzuela A, et al. Massive pulmonary hemorrhage: fatal complication of systemic lupus erythematosus [letter]. *J Rheumatol* 1985; 12:186-187
- 22 Churg A, Franklin W, Chan K, et al. Pulmonary hemorrhage and immune complex deposition in the lung. *Arch Pathol Lab Med* 1980; 104:388-391
- 23 Erickson RW, Franklin WA, Emlen W. Treatment of hemorrhagic lupus pneumonitis with plasmapheresis. *Semin Arthritis Rheum* 1994; 42:114-123
- 24 Fukuda M, Kamiyama Y, Kawahara K, et al. The favorable effect of cyclophosphamide pulse therapy in the treatment of massive pulmonary hemorrhage in systemic lupus erythematosus. *Eur J Pediatr* 1994; 153:167-170
- 25 Gould DB, Soriano RZ. Acute alveolar hemorrhage in lupus erythematosus [letter]. *Ann Intern Med* 1975; 83:836-866
- 26 Howe HS, Boey ML, Fong KY, et al. Pulmonary hemorrhage, pulmonary infarction, and the lupus anticoagulant. *Ann Rheum Dis* 1988; 47:869-872
- 27 Makina Y, Ogawa M, Ueda S, et al. CT appearance of diffuse alveolar hemorrhage in a patient with systemic lupus erythematosus [letter]. *Acta Radiol* 1993; 34:634-635
- 28 Hsu BY, Edwards DK, Trambert MA. Pulmonary hemorrhage complicating systemic lupus erythematosus: role of MR imaging in diagnosis. *AJR Am J Roentgenol* 1992; 158:519-520
- 29 Ichikawa Y, Shimizu H, Kobayashi I, et al. Recurrent lupus pneumonitis with pulmonary hemorrhage in systemic lupus erythematosus associated with chronic thyroiditis and antithyroid autoantibodies. *Clin Exp Rheumatol* 1989; 7:309-313
- 30 Pines A, Kaplinsky N, Olchovsky D, et al. Pleuro-pulmonary manifestations of systemic lupus erythematosus: clinical features of its subgroups; prognostic and therapeutic implications. *Chest* 1985; 88:129-135
- 31 Ramirez R, Glasier C, Kirks D, et al. Pulmonary hemorrhage associated with systemic lupus erythematosus in children. *Radiology* 1984; 152:409-412



- 32 Someren AO, Honig E, Gaffner E, et al. Massive asphyxiating pulmonary hemorrhage and glomerulonephritis in a 41-year-old woman. *South Med J* 1983; 76:775-781
- 33 Sureda A, Pascual J, Hernandez-Jodra M. Coincidental autoimmune hemolytic anemia and massive pulmonary hemorrhage in systemic lupus erythematosus [letter]. *J Rheumatol* 1990; 17:267-268
- 34 Marino CT, Pertschuk LP. Pulmonary hemorrhage in systemic lupus erythematosus. *Arch Intern Med* 1981; 141:201-203
- 35 Segal AM, Calabrese LH, Ahmad M, et al. The pulmonary manifestations of systemic lupus erythematosus. *Semin Arthritis Rheum* 1985; 14:202-224
- 36 Orens JB, Martinez FJ, Lynch JP. Pleuropulmonary manifestations of systemic lupus erythematosus. *Rheum Dis Clin North Am* 1994; 20:159-192
- 37 Haupt HM, Moore GW, Hutchins GM. The lung in systemic lupus erythematosus: analysis of the pathologic changes in 120 patients. *Am J Med* 1981; 71:791-798
- 38 Fishback N, Koss M. Pulmonary manifestations of systemic lupus erythematosus. In: Antonovych TT, ed. *Pathology of systemic lupus erythematosus*. Washington, DC: Armed Forces Institute of Pathology, Armed Forces Registry, 1995
- 39 Miller LR, Greenberg D, McLarty JW. Lupus lung. *Chest* 1985; 88:265-269
- 40 Ewan PW, Jones HA, Rhodes GG, et al. Detection of intrapulmonary hemorrhage with carbon monoxide uptake: application in Goodpasture's syndrome. *N Engl J Med* 1976; 295:1391-1396
- 41 Young KR. Pulmonary-renal syndromes. *Clin Chest Med* 1989; 10:655-675
- 42 Leatherman JW, Davies SF, Hoidal JR. Alveolar hemorrhage syndromes: diffuse microvascular lung hemorrhage in immune and idiopathic disorders. *Medicine* 1984; 63:343-361
- 43 Schroeder JO, Euler HH, Loffler H. Synchronization of plasmapheresis and pulse cyclophosphamide in severe systemic lupus erythematosus. *Ann Intern Med* 1987; 107:344-346
- 44 Millman RP, Cohen TB, Levinson AI, et al. Systemic lupus erythematosus complicated by acute pulmonary hemorrhage: recovery following plasmapheresis and cytotoxic therapy [letter]. *J Rheumatol* 1981; 8:1021-1023

## Alveolar Hemorrhage in Systemic Lupus Erythematosus : Presentation and Management

Alberto S. Santos-Ocampo, Brian F. Mandell and Barri J. Fessler

*Chest* 2000;118;1083-1090

DOI: 10.1378/chest.118.4.1083

**This information is current as of August 18, 2006**

<b>Updated Information &amp; Services</b>	Updated information and services, including high-resolution figures, can be found at: <a href="http://www.chestjournal.org/cgi/content/full/118/4/1083">http://www.chestjournal.org/cgi/content/full/118/4/1083</a>
<b>References</b>	This article cites 43 articles, 9 of which you can access for free at: <a href="http://www.chestjournal.org/cgi/content/full/118/4/1083#BIBL">http://www.chestjournal.org/cgi/content/full/118/4/1083#BIBL</a>
<b>Citations</b>	This article has been cited by 2 HighWire-hosted articles: <a href="http://www.chestjournal.org/cgi/content/full/118/4/1083#otherarticles">http://www.chestjournal.org/cgi/content/full/118/4/1083#otherarticles</a>
<b>Rapid Response</b>	2 rapid response(s) have been posted to this article, which you can access for free at: <a href="http://www.chestjournal.org/cgi/eletters/118/4/1083">http://www.chestjournal.org/cgi/eletters/118/4/1083</a>
<b>Permissions &amp; Licensing</b>	Information about reproducing this article in parts (figures, tables) or in its entirety can be found online at: <a href="http://www.chestjournal.org/misc/reprints.shtml">http://www.chestjournal.org/misc/reprints.shtml</a>
<b>Reprints</b>	Information about ordering reprints can be found online: <a href="http://www.chestjournal.org/misc/reprints.shtml">http://www.chestjournal.org/misc/reprints.shtml</a>
<b>Email alerting service</b>	Receive free email alerts when new articles cite this article sign up in the box at the top right corner of the online article.
<b>Images in PowerPoint format</b>	Figures that appear in CHEST articles can be downloaded for teaching purposes in PowerPoint slide format. See any online article figure for directions.

