CHEST®

Official publication of the American College of Chest Physicians

Pulmonary Infiltrates in the Non-HIV-Infected Immunocompromised Patient: Etiologies, Diagnostic Strategies, and Outcomes

Andrew F. Shorr, Gregory M. Susla and Naomi P. O'Grady

Chest 2004;125;260-271
DOI 10.1378/chest.125.1.260

The online version of this article, along with updated information and services can be found online on the World Wide Web at:
http://chestjournals.org/cgi/content/abstract/125/1/260

CHEST is the official journal of the American College of Chest Physicians. It has been published monthly since 1935. Copyright 2007 by the American College of Chest Physicians, 3300 Dundee Road, Northbrook IL 60062. All rights reserved. No part of this article or PDF may be reproduced or distributed without the prior written permission of the copyright holder (http://www.chestjournal.org/misc/reprints.shtml). ISSN: 0012-3692.

AMERICAN COLLEGE OF CHEST PHYSICIANS®

Downloaded from chestjournals.org on February 14, 2007
Copyright © 2004 by American College of Chest Physicians

Pulmonary Infiltrates in the Non-HIV-Infected Immunocompromised Patient*

Etiologies, Diagnostic Strategies, and Outcomes

Andrew F. Shorr, MD, MPH; Gregory M. Susla, PharmD; and Naomi P. O'Grady, MD

Pulmonary complications remain a major cause of both morbidity and mortality in immunocompromised patients. When such individuals present with radiographic infiltrates, the clinician faces a diagnostic challenge. The differential diagnosis in this setting is broad and includes both infectious and noninfectious processes. Rarely are the radiographic findings classic for one disease, and most potential etiologies have overlapping clinical and radiographic appearances. In recent years, several themes have emerged in the literature on this topic. First, an aggressive approach to identifying a specific etiology is necessary; as a corollary, diagnostic delay increases the risk for mortality. Second, the evaluation of these infiltrates nearly always entails bronchoscopy. Bronchoscopy allows identification of some etiologies with certainty, and often allows for the exclusion of infectious agents even if the procedure is otherwise unrevealing. Third, early use of CT scanning regularly demonstrates lesions missed by plain radiography. Despite these advances, initial therapeutic interventions include the use of broad-spectrum antibiotics and other anti-infectives in order to ensure that the patients is receiving appropriate therapy. With the results of invasive testing, these treatments are then narrowed. Frustratingly, outcomes for immunocompromised patients with infiltrates remain poor. ***(CHEST 2004; 125:260–271)***

Key words: bronchoscopy; complications; fungus; immunocompromised; infection; infiltrates; malignancy; outcomes; transplant

Abbreviations: CMV = cytomegalovirus; DAD = diffuse alveolar damage; DAH = diffuse alveolar hemorrhage; GVHD = graft-vs-host disease; HSCT = hematopoietic stem-cell transplantation; PTLD = posttransplant lymphoproliferative disease; RSV = respiratory syncytial virus; SLB = surgical lung biopsy; SOT = solid-organ transplant; TBB = transbronchial biopsy

The development of pulmonary infiltrates in immunosuppressed patients is a particularly ominous sign and remains a diagnostic challenge. Pulmonary complications are a frequent cause of morbidity and mortality in these patients. Mortality rates for bone marrow transplant recipients with pulmonary infiltrates and requiring mechanical ventilation approach 90%.[1] With the expanding use of both solid-organ transplant (SOT) and hematopoietic stem-cell transplantation (HSCT) coupled with increasingly aggressive chemotherapeutic regimens for malignancies, pulmonary and critical care physicians will find themselves more involved in the care of immunosuppressed patients. Particularly frustrating for those treating these patients is the fact that many are young and have undergone aggressive treatments in hopes of a cure. In order to improve outcomes, the clinician requires a comprehensive understanding of the differential diagnosis for pulmonary infiltrates in the immunosuppressed patient, the diagnostic approach to these cases, and newer treatment options. As the underlying cause for immunosuppression significantly affects the potential etiologies for pulmonary lesions, our discussion is limited to patients who are not infected with the HIV.

*From the Pulmonary and Critical Care Medicine Service, Walter Reed Army Medical Center, Washington, DC; and the Critical Care Medicine Department, Clinical Center, National Institutes of Health, Bethesda, MD.
The opinions expressed herein are not to be construed as official or as reflecting the policies of either the Department of the Army or the Department of Defense.
Manuscript received December 10, 2002; revision accepted April 10, 2003.
Reproduction of this article is prohibited without written permission from the American College of Chest Physicians (e-mail: permissions@chestnet.org).
Correspondence to: Andrew F. Shorr, MD, MPH, Pulmonary and Critical Care Medicine Service, Walter Reed Army Medical Center, 6900 Georgia Ave NW, Washington, DC 20307; e-mail: afshorr@dnamail.com

Differential Diagnosis

The differential diagnosis for pulmonary infiltrates in the immunosuppressed patient is broad and in-

Downloaded from chestjournals.org on February 14, 2007
Copyright © 2004 by American College of Chest Physicians

cludes both infectious and noninfectious etiologies. Table 1 lists potential etiologies for parenchymal lesions in these patients. The relative probability that any one explanation accounts for the infiltrates will be a function of the patient's underlying diagnosis, current immunosuppressive regimen, duration of immunosuppression, and prior therapies. For example, diffuse alveolar hemorrhage (DAH) rarely complicates SOT, while it is more common following therapy for acute leukemia or after HSCT. Similarly, graft-vs-host disease (GVHD), by definition, is only seen in allogeneic HSCT and not autologous HSCT. Infection with *Pseudomonas carinii*, however, may occur after SOT, HSCT, or chemotherapy for malignancy.

For HSCT and SOT, predictable temporal patterns exist that correlate with the risk for various infectious and noninfectious processes (Table 2). In the early posttransplant period (first month after procedure), bacterial pathogens predominate as do fungal diseases if there has been a prolonged period of neutropenia. Noninfectious problems that lead to infiltrates in this early posttransplant period include those related to the surgical procedure, fluid shifts, and drug toxicities. Idiopathic alveolar hemorrhage and pulmonary hemorrhage due to thrombocytopenia are also seen soon after transplant. One to 3 months following transplant, concerns about opportunistic pathogens such as *P carinii* arise. Interstitial pneumonia resulting from either cytomegalovirus (CMV) infection or the conditioning regimen are seen during this time frame. In the late posttransplant period (> 3 months) *P carinii* remains a concern but mycobacterial infections and Nocardial spp. now should be considered as potential causes for infiltrates. Additionally, CMV can result in a "late-onset" interstitial pneumonia. GVHD becomes an issue during this phase, as does rejection.[2]

Table 1—*Differential Diagnosis of Pulmonary Infiltrates in the Immunosuppressed Patient**

Infectious causes
Bacteria (*Pseudomonas aerugenosa*, *Staphylococcus aureus*)
Fungi (Aspergillus, Mucormycosis, Candida)
Viruses (CMV, VZV, HSV, RSV, parainfluenza, influenza)
P carinii
Mycobacteria (*Mycobacterium tuberculosis* and nontuberculous mycobacteria)
Noninfectious causes
Pulmonary edema
Progression of underlying disease
Radiation toxicity
Drug toxicity
DAH
Engraftment syndrome
Idiopathic pneumonia syndrome
Bronchiolitis obliterans organizing pneumonia
Secondary alveolar proteinosis
PTLD
Transfusion-related acute lung injury

*VZV = varicella zoster virus; HSV = herpes simplex virus.

Infectious Etiologies

Bacterial, fungal, viral, and mycobacterial pathogens may infect the lungs of immunosuppressed patients. In a prospective series[3] of 200 immunocompromised patients with infiltrates, infectious agents were recovered from more than three fourths of subjects. An earlier study[4] focusing solely on liver transplant recipients reported that 50% of infiltrates were infectious in origin. As a rule, these patients are at risk for infection with traditional nosocomial bacteria such as *P aeruginosa* and *S aureus*. Aerobic Gram-negative bacilli such as *Klebsiella pneumoniae* may also lead to pneumonia. Although often considered a community-acquired pathogen, Legionella may be responsible for hospital outbreaks of pneumonia. Nosocomial Legionella infection is similar to community-acquired infection with respect to clinical presentation and general radiographic appearance. Infections due to Legionella, however, are more often complicated by both cavitation and pleural effusion in immunosuppressed hosts compared to immunocompetent hosts.[5] Anaerobes rarely produce infiltrates in these patients.

Fungal pneumonias result in a wide spectrum of illness. Infection with aspergillus is the most common cause of fungal pneumonia in this group of patients. Aspergillus infection arises in 1 to 8% of patients undergoing various SOTs and HSCTs[6] (Table 3). A recent analysis,[7] however, indicates that the incidence of invasive Aspergillus is increasing. In a series from the Fred Hutchinson Cancer Center, invasive Aspergillus was seen in > 10% of allogeneic HSCT patients in 1998, while in 1990 this infection was diagnosed in only 4% of subjects.[7] Classically, patients complain of chest pain, dyspnea, and hemoptysis. Some patients initially have no symptoms. Jantunen et al[8] described a group of 22 patients with invasive Aspergillus; in their cohort, only 50% of subjects presented with respiratory symptoms and 32% were febrile.[8] The triad of chest pain, dyspnea, and hemoptysis, which may be seen with Aspergillus, also occurs with pulmonary embolism, which further complicates the clinical picture. The radiographic appearance of acute, invasive aspergillosis is varied and ranges from normal to dense alveolar consolidation. The chest radiograph may initially be normal in up to 10% of cases[6]; therefore, early use of CT scans is crucial in immunosuppressed patients with pulmonary symptoms. Because of its angioinvasive nature,

Downloaded from chestjournals.org on February 14, 2007
Copyright © 2004 by American College of Chest Physicians

Table 2—*Examples of Etiologies for Infiltrates in SOT and HSCT Patients Based on Time Course**

Time	Infectious Processes	Noninfectious Processes
> 1 mo after procedure	Bacterial pneumonia, invasive fungal infections	Acute lung injury, cardiogenic pulmonary edema, DAH, pulmonary bleeding due to thrombocytopenia, TRALI
1–3 mo after procedure	CMV, opportunistic infections	Drug toxicity, idiopathic pneumonia syndrome, drug toxicities
> 3 mo after procedure	Delayed CMV pneumonia, mycobacterial disease	BOOP, rejection

*BOOP = bronchiolitis obliterans organizing pneumonia; TRALI = transfusion-related acute lung injury.

Aspergillus can result in peripheral, wedge-shaped infiltrates. This appearance may again be confused for pulmonary embolism. Often as the patient's immune system recovers, lesions coalesce and cavitate. As the affected lung cavitates, an area of low attenuation may arise next to the lesion and is referred to as a "halo sign." The halo sign is neither sensitive nor specific for Aspergillus. First, many molds other than Aspergillus (*eg*, Fusarium) can cause a similar pattern on a CT scan. Second, the fact that the halo sign is a late finding coupled with the observation that Aspergillus causes such a wide spectrum of illness explains why the halo sign is absent in many cases. In one report[9] of definitive Aspergillus cases, the sensitivity was only 50%. Nodular infiltrates may be seen. Other pathogens that produce nodular infiltrates in immunocompromised subjects include nocardial infection, posttransplant lymphoproliferative disease (only SOT recipients), CMV pneumonitis, and *P carinii* pneumonia. Diagnosis of aspergillosis remains difficult. The pathology may be peripheral and may be inaccessible to BAL. The yield of bronchoscopy for aspergillosis in immunosuppressed patients is approximately 50%.[2,10,11] Because the disease is angioinvasive and patchy, transbronchial biopsy (TBB) is prone to sampling error. Thus, one should not withhold antifungal therapy if he/she has a high index of suspicion for Aspergillus and bronchoscopy is unrevealing. Newer investigational options that may aid in the diagnosis of acute, invasive aspergillosis include a polymerase chain reaction assay for Aspergillus DNA and an enzyme-linked immonosorbent assay test for galactomannan. The sensitivity of the galactomannan enzyme-linked immonosorbent assay system ranges from 80 to 90% and the specificity is > 95%.[12,13] Further studies are needed to validate these preliminary findings.

Other medically important fungi that should be considered in the diagnosis of pneumonia include the endemic mycoses (*Histoplasma capsulatum*, *Coccidioides immitus*, and *Blastomyces dermatitidis*), and emerging fungi such as trichosporon, fusarium, and zygomycetes. Although often isolated in respiratory secretions, particularly from patients previously receiving broad-spectrum antibiotics, Candida rarely causes pneumonia in patients other than lung transplant recipients. Candida pneumonia, for example, was identified in only 0.4% of autopsies at the M.D. Anderson Cancer Center.[14] Disseminated Candida, however, may seed the lungs resulting in either local or diffuse infiltrates. These may be miliary in appearance. Slowly enlarging nodules have also been described in Candidal lung infections. Because isolation from respiratory sections often represents colonization rather than infection, attributing the presence of pulmonary infiltrates in the immunocompromised to Candida is difficult. Demonstration of tissue invasion via TBB or surgical lung biopsy (SLB) would be required for definitive diagnosis. Readers should note that in lung transplant recipients, a positive donor tracheal culture for Candida is a likely marker for candidal infection after transplantation.[15]

Table 3—*Incidence and Impact of Aspergillosis in Transplantation**

Type of Transplant	Incidence of Invasive Aspergillosis, %	Mortality From Invasive Aspergillosis, %	Deaths After Transplantation Due to Invasive Aspergillosis, %
Bone marrow	6.4	92	10
Lung	8.4	55	9.3
Liver	1.7	87	16.9
Heart	6.2	78	15.4
Kidney	1.3	100	ND

*ND = not determined; Table modified from Paterson and Singh.[6]

Downloaded from chestjournals.org on February 14, 2007
Copyright © 2004 by American College of Chest Physicians

Several viruses are of concern in the immunosuppressed host: CMV, herpes virus, respiratory syncytial virus (RSV), influenza virus, parainfluenza virus, adenovirus, and varicella virus. Over the last 10 to 15 years, viruses have been increasingly recognized as important causes of serious respiratory illnesses in immunocompromised subjects. Respiratory viruses not only directly cause morbidity and mortality but also increase the chances for rejection in solid-organ recipients.[16,17] These viral infections may result from reactivation of a latent process or reflect newly acquired infection. As such, seasonal variation in their incidence is seen with RSV, influenza, and parainfluenza virus while the development of CMV is related to the patient's underlying immune status and prior CMV serostatus. RSV and influenzae are of particular concern during the fall and winter months.[16] Symptoms of viral pneumonias tend to be nonspecific; however, since some viruses have a predilection for the airways, they can produce bronchiolitis. Hence, patients may report wheezing. CMV is the most common viral pathogen responsible for pulmonary infection in non-HIV immunosuppressed patients.[16,17] Sternberg et al[18] identified CMV as the causative agent in one of four renal transplant patients with pneumonia, and Torres et al[4] found that 30% of pneumonias in liver transplant subjects were due to CMV. The burden of CMV disease is greater in HSCT. It has been responsible for up to 50% of cases of pneumonia in some large series.[17] This pattern is changing with the advent of aggressive screening and preemptive therapy. Three radiographic patterns have been reported in CMV pneumonia: lobar consolidation, focal parenchymal haziness, and bilateral reticulonodular infiltrates. CT findings include ground-glass opacification, bronchial wall thickening, reticular opacities, nodules and, occasionally, masses. CMV may be isolated in association with other pathogens. In such cases, it is often unclear whether CMV is causing the infiltrates in question or simply predisposing the patient to a second infection. Because of the burden of CMV, prophylactic strategies exist. In individuals undergoing HSCT who have positive CMV serologic findings, preemptive treatment with gancyclovir reduces the incidence of CMV pneumonia.[11] Unlike BAL and TBB for suspected Aspergillus, these procedures have a high yield for CMV.

The incidence of *P carinii* pneumonia has dramatically decreased with the widespread use of prophylaxis with trimethoprim-sulfamethoxazole; however, breakthrough cases do occur, and patients who are not adherent to the prophylactic regimen may present with a fulminate pneumonia that frequently correlates with adjustments in the immunosuppressive regimen (*eg*, tapering of corticosteroids). In a study from the Mayo Clinic, 90% of cases of *P carinii* infection in non-HIV infected patients developed in persons treated with corticosteroids within the 4 weeks of the diagnosis.[19] Fludarabine therapy for chronic lymphocytic leukemia has also been directly linked to the onset of *P carinii* pneumonia.[20] The symptoms, physical examination, and radiographic appearance of *P carinii* in non-HIV patients are comparable to those seen in HIV-positive individuals. Two radiographic patterns have been described: (1) fine, perihilar infiltrates; or (2) small, nodular infiltrates. These infiltrates tend to be bilateral. Bronchoscopy has an important role in the diagnosis of *P carinii* in the non-HIV immunosuppressed patient. The yield of BAL for *P carinii* with conventional stains, however, is approximately 80% in these patients compared to > 95% yield in individuals with HIV.[21] This discrepancy arises because fewer organisms are recovered from specimens from non-HIV subjects.[22] In turn, the lower organism burden decreases the value of BAL. Reflecting this difference, 1 to 5% of non-HIV patients require SLB for the diagnosis of *P carinii*. Collection of induced sputum represents a less invasive alternative for the diagnosis of *P carinii*, although unlike patients with HIV, the diagnostic yield of induced sputum for transplant patients is very low. *P carinii* tends to be more severe in subjects without HIV. Bronchoscopy studies[21,22] demonstrate fewer neutrophils in patients with HIV compared to non-HIV subjects; this suggests that there is greater inflammation in the lungs of the non-HIV persons.

The likelihood of mycobacterial infections varies based on the underlying reason for immunosuppression. Tuberculosis rarely complicates chemotherapy for acute leukemia or HSCT. The incidence of pulmonary mycobacterial infection was only 0.5% in a large series[23] of bone marrow transplant patients. For SOT recipients, however, the impact of mycobacterial infections is greater: up to 15% of such individuals from areas where tuberculosis is endemic acquire active, pulmonary infection.[24] The risk for tuberculosis seems highest in renal transplantation relative to heart, lung, liver, and pancreas transplants. Unlike other pulmonary infections (which can occur at any point after treatment with chemotherapeutics or immunosuppressive agents), tuberculosis arises late in the patient's course. A comprehensive review of published cases of tuberculosis in SOT recipients noted that the infection occurred a median of 9 months after transplantation.[24] Classically, in immunocompetent adults, pulmonary tuberculosis appears as either segmental or lobar alveolar consolidation. Hilar and mediastinal lymphadenopathy are common. In postprimary tuberculosis, the radiograph reveals parenchymal infiltrates in the posterior

Downloaded from chestjournals.org on February 14, 2007
Copyright © 2004 by American College of Chest Physicians

segments of the upper lobes and the superior segments of the lower lobes. In SOT subjects, only 40% of cases of pulmonary tuberculosis presents as focal infiltrates, while one fourth are miliary.[24] Nodular infiltrates have also been reported, particularly following nonrenal transplantation.[24] The presence or absence of mediastinal adenopathy is not a reliable sign for either including or excluding mycobacterial disease from the differential diagnosis since the incidence of atypical radiographic patterns in immunocompromised patients is high.[23,24]

Noninfectious Etiologies

Noninfectious etiologies for pulmonary infiltrates in the immunosuppressed host are as diverse as the potential microbiologic etiologies. Furthermore, noninfectious processes are responsible for between 25 to 50% of infiltrates in these patients.[3,4,25,26] As with infectious agents, presenting signs and symptoms range from minor dyspnea to rapidly progressive respiratory failure. The initial clinical appearance is rarely helpful in identifying a specific cause. Many noninfectious causes of pulmonary infiltrates in immunosuppressed subjects have a poor prognosis. Pulmonary injury in these patients may result from pulmonary edema, progression of underlying disease, drug and radiation toxicities, DAH, and miscellaneous conditions (*eg*, bronchiolitis obliterans, secondary pulmonary alveolar proteinosis). Conditions only reported in HSCT recipients include the idiopathic pneumonia syndrome and engraftment syndrome.

Patients undergoing organ transplant, chemotherapy, and HSCT receive significant volume loads. Aggressive hydration is required prior to chemotherapy for leukemia and is an integral part of the HSCT process. Liver transplant patients have significant intraoperative blood loss, and often have many times their blood volumes replaced. Alternatively, chemotherapy may predispose to pulmonary edema in that several agents (*eg*, anthracyclines) can results in cardiotoxicity. All of these factors increase capillary hydrostatic pressure. Concomitantly, other forms of indirect lung injury from drugs, radiation, or sepsis increase capillary permeability. Taken together, these two forces promote the development of pulmonary edema. Radiographs reveal vascular redistribution and diffuse infiltrates. Patients can decompensate quickly from pulmonary edema. A history of large fluid challenges coupled with changes in a patient's weight are suggestive of pulmonary edema. Often these patients are afebrile. The management of pulmonary edema in immunocompromised host is similar to the approach to pulmonary edema in other settings. As pulmonary edema responds to therapy while many other noninfectious causes of pulmonary infiltrates have a poor prognosis, clinicians need to be aggressive when assessing the fluid status of immunocompromised patients. Noncardiogenic pulmonary edema also may arise as result of drug toxicity. Specific agents of concern include high-dose cytarabine and interleukin-2.[27] Gemcitibine, an agent in the same class as cytarabine, has been reported to cause pulmonary edema rarely.[27]

In patients with an underlying malignancy, the initial manifestation of disease progression can occur in the thorax and present as a pulmonary infiltrates. For individuals with either lymphoma or solid tumors, the lesions may appear as discrete nodules with or without adenopathy.[25] These tumors and leukemic cells can obstruct lymphatic and vascular drainage. Such lymphangitic infiltrates may be either unilateral or bilateral but tend to be interstitial rather than alveolar. Leukemic infiltration has two forms. In the first type, circulating white cells occlude pulmonary vascular beds. The risk for this leukostasis syndrome is directly related to the circulating WBC count. Physicians should note that arterial blood gas results might be artificially low in this condition. Leukocytes metabolize the oxygen in the sample container before it can be measured. In the second form of leukemic infiltration, blast cells infiltrate the interstitium and alveolar spaces. These infiltrates may be unilateral and are occasionally associated with pleural effusions.[25,26] Bronchoscopy is important in suspected cases of disease progression, in that it helps to exclude alternative diagnoses such as infection. Tissue obtained from TBB may reveal the presence of tumor. Flow cytometry performed on BAL fluid can identify clonal cell populations and aid in the diagnosis of recurrent disease. Case reports suggest that in instances of suspected lymphangitic spread of cancer, blood withdrawn from a pulmonary artery catheter may contain malignant cells.[28] Such catheters should only be placed if clinically indicated. If already in the patient, though, one should consider sending such samples for cytologic analysis.

Posttransplant lymphoproliferative disease (PTLD) is seen in SOT subjects and HSCT patients. PTLD represents a range of entities varying from a polyclonal lymphocytic hyperplasia to a malignant monoclonal tumor.[29,30,31] The majority of PTLD cases are of B-cell origin. Occurring in 1 to 3% of individuals after transplantation, PTLD is more common in lung transplant recipients.[24–26] PTLD arises late after SOT (> 1 year), and is related both to the immunosuppressive regimen and infection with Epstein-Barr virus. PTLD occurs early following HSCT with a peak incidence in the first 6 months after the procedure.[32] PTLD rarely causes infiltrates; rather, it appears as pulmonary nodules that

Downloaded from chestjournals.org on February 14, 2007
Copyright © 2004 by American College of Chest Physicians

may be singular or multiple. Treatment for PTLD requires adjustments in immunosuppression. If this fails, other alternatives include monoclonal antibodies to B cells, acyclovir, and cytotoxic chemotherapy.

A host of agents are associated with pulmonary toxicity (Table 4). For some medications, the link between use and toxicity is well established and has been replicated in animal models (*eg*, bleomycin). For others, the cause-and-effect relationship is less clear. In such instances, the data suggesting potential toxicity are often indirect. Because immunosuppressed patients are complex and many factors may explain pulmonary injury, implicating a particular agent is difficult. Some medications, furthermore, may only indirectly cause pulmonary infiltrates because they potentiate the effects of other agents. Pathologically, common patterns of injury include diffuse alveolar damage (DAD), granulomatous reactions, and nonspecific pneumonitis.[33] DAD may be indistinguishable from the ARDS. Clinically, the diagnosis of drug toxicity rests on the following: (1) the temporal relationship between use of a particular agent and the subsequent development of symptoms, and (2) improvement in pulmonary function after withdrawal of the agent.[25,26] Exclusion of infection is also crucial. One limitation of this model of drug toxicity is that it ignores both delayed effects and interactions between specific medications within unique subgroups of patients. For example, previous bleomycin exposure increases the risk for developing ARDS if the subject later receives high-concentration supplemental oxygen. Similarly, antithymocyte globulin has been associated with ARDS in renal transplantation when used for acute rejection but not for induction of immunosuppression.[34] Physicians should be vigilant for previously undescribed pulmonary toxicities when new agents become available for clinical practice. Both pacilitaxel and fludarabine were not thought to have pulmonary toxicities.[35,36] With expanded use, investigators have since described pulmonary toxicity with each of these. Furthermore, when utilized in SOT, sirolimus, a potent immunosuppressive, has been implicated as a cause for interstitial pneumonitis.[37]

Table 4—*Drugs Associated With Pulmonary Toxicity*

Alkylating agents
Busulfan
Chlorambucil
Cyclophosphamide
Antimetabolites
Azathioprine
Cytosine arabinoside
Fludarabine
Gemcitibine
Methotrexate
Cytotoxic antibiotics
Bleomycin
Dactinomycin
Mitomycin
Nitrosoureas
BCNU (carmustine)
CCNU (lomustine)
Assorted agents
Antithymocyte globulin
Doxorubicin
Interleukin-2
Procarbazine
Sirolimus
Taxanes
Vinca alkaloids

Radiation therapy is often central to the treatment of patients with cancer and patients receiving HSCTs. Radiation to the chest results in the release of multiple proinflammatory cytokines and fibrotic mediators. Radiation exposure causes both an acute pneumonitis and a more chronic syndrome characterized by advanced pulmonary fibrosis.[25,26] Bronchoscopy studies[37,38] in asymptomatic patients treated with ionizing radiation reveal increased cytokine activity in the lung and the presence of lymphocytes. Evidence of active inflammation is not confined to the area of the radiation port and has been found in the contralateral lung. In patients who progress to a clinically evident radiation pneumonitis, the radiographic findings range from normal to mild perivascular haziness. Over time, these initial lesions may develop into alveolar infiltrates. Patients are often febrile and have a leukocytosis making radiation injury a clinical syndrome difficult to distinguish from infection. Unique to radiation injury, however, is the pattern present on the chest CT. Areas of injury may appear sharply bounded and not follow an anatomic border. Risk factors for radiation injury include total dose delivered, fractionation, preexisting lung disease, concurrent treatment with agents that sensitive the lung to radiation damage, and corticosteroid withdrawal during treatment. Although randomized trials are lacking, corticosteroids remain the mainstay of treatment (1 to 2 mg/kg/d of prednisone).[25,26]

The diagnosis of DAH requires evidence of alveolar injury and a progressively bloodier return from BAL (in multiple subsegmental bronchi).[39] An alternative diagnostic criteria is the presence hemosiderin-filled alveolar macrophages. If $\geq 20\%$ of the alveolar macrophages are hemosiderin laden, then DAH is present.[39] Irrespective of the diagnostic standard, the physician must exclude infection as a reason for pulmonary hemorrhage. Patients with DAH manifest symptoms and a clinical examination consistent with an infectious pneumonia. Radiographic imaging regularly reveals diffuse interstitial

Downloaded from chestjournals.org on February 14, 2007
Copyright © 2004 by American College of Chest Physicians

and alveolar infiltrates, predominantly in the middle and lower lung fields.[40] In a review of seven studies describing DAH, Afessa et al[39] estimated that DAH complicates approximately 5% of HSCTs. The incidence ranged from 2 to 14% in the reports they examined, and it occurred following both autologous and allogeneic HSCT. Factors associated with DAH include the conditioning regimen employed, prior total body irradiation, and increasing patient age. The development of DAH does not correlate with the degree of thrombocytopenia, and many patients do not report hemoptysis. The pathogenesis of DAH is unclear. DAH likely arises following an initial lung injury from either chemotherapy or irradiation that results in endothelial damage.[39,40] With marrow recovery, inflammation develops in the lung leading to cytokine release. Both endogenous and exogenous cytokines (*eg*, granulocyte-colony stimulating factor treatments) may propagate the inflammatory cascade. DAH generally occurs early in the post-HSCT period, and fever is common. Similar to the approach for radiation pneumonitis, treatment consists of high-dose corticosteroids. Reported dosages used have ranged from 500 mg to 2 g per day of IV methylprednisolone.[39,40] Nearly 8 of 10 patients with DAH die; however, long-term survivors of DAH may have normal pulmonary function.[39] Alveolar hemorrhage related to thrombocytopenia also occurs. This entity is distinct from DAH, in that there is no evidence of DAD or acute lung injury. In these cases, correction of the platelet helps to reduce the risk for further bleeding.

Engraftment syndrome, like DAH, is also seen early following HSCT. Engraftment syndrome is a form of diffuse capillary leak associated with lung injury and pulmonary edema. Unfortunately, there are no criteria that define engraftment syndrome. Earlier studies have all, however, reported pulmonary edema as a central feature.[41] Temporally coinciding with neutrophil engraftment after HSCT, this syndrome leads to diffuse pulmonary infiltrates similar to those seen in volume overload or ARDS. As with other noninfectious etiologies of pulmonary infiltrates, patients with engraftment syndrome frequently are febrile. During neutrophil recovery, levels of multiple proinflammatory cytokines increase. These cytokines (*eg*, tumor necrosis factor-α, interleukin-6, interleukin-8) promote neutrophil degranulation that, in turn, promote lung injury.[41] Unlike engraftment syndrome, the idiopathic pneumonia syndrome, arises later following HSCT. Generally only seen in allogeneic HSCT, the idiopathic pneumonia syndrome also represent a nonspecific form of lung injury, which radiographically appears as diffuse, multilobar infiltrates. The diagnosis of idiopathic pneumonia syndrome is one of exclusion, which requires the elimination of potential infectious agents as a cause for the patient's respiratory status. Patients may have mild symptoms, but most acquire hypoxemia and dyspnea. Patients with this syndrome may simultaneously have pulmonary hemorrhage. This association has led some to speculate that DAH and idiopathic pneumonia syndrome represent different manifestations of a common pathologic process.[39] Corticosteroids are recommended for the treatment of the idiopathic pneumonia syndrome. Even in patients treated with corticosteroids outcomes remain poor: > 70% of patients die.[25]

Diagnostic Approach

The initial approach to the immunosuppressed patient with pulmonary infiltrates begins with a careful history focusing on current and prior immunosuppressive regimens. The aim of this is to quantitate the extent of the subject's immune dysregulation. Additionally, treatment with certain medications, as noted above, may raise concern for drug-induced lung injury. The temporal relationship between the onset of the pulmonary infiltrates and the initiation of immunosuppression routinely alters the differential diagnosis. The development of pulmonary infiltrates soon after HSCT may suggest engraftment syndrome, while infiltrates occurring > 90 days after organ transplant could represent CMV infection. Travel and occupational history are also important, in that they offer clues as to the risk for certain fungal pathogens. Although rare in Western countries, *M tuberculosis* is another example of a late-onset infection. Recent hospital or local construction, for example, raises the possibility for pneumonia due to endemic soil fungi and Aspergillus.[42] Knowing if the subject has latent infections further aids in narrowing the differential diagnosis. A prior positive CMV antigen titer or a history of a positive skin test result for latent tuberculosis can prove helpful diagnostically. Conversely, the absence of a known exposure or risk factor for a particular pathogen does not exclude that organism from the list of diagnostic possibilities.

The specific use of certain prophylactic antibiotics also alters the probability that individual pathogens are responsible for the patient's clinical status. Trimethoprim-sulfamethoxazole has proven very effective in decreasing the risk for *P carinii* pneumonia. Prophylaxis with oral quinolones may select for infection with resistant strains of *Streptococcus viridans*. For example, at one cancer center, the incidence *of S viridans* bacteremia increased from 1/10,000 to 47/10,000 hospital admissions during the 1990s following greater reliance on quinolones for prophylaxis.[43] Broader employment of prophylactic anti-infective regimens has altered the pattern of

Downloaded from chestjournals.org on February 14, 2007
Copyright © 2004 by American College of Chest Physicians

infections in immunosuppressed patients in other ways as well. Fluconazole is regularly administered prophylactically to HSCT subjects and to many SOT patients. Some speculate that this policy accounts, in part, for the increasing incidence of invasive Aspergillus.[7,42] By preventing some candidal infections that would have resulted in mortality, individuals now survive longer and are thus exposed to the risk for Aspergillus infection that would not have been an issue if they had succumbed to another process earlier in the posttransplant period. In parallel with this trend has also been an increase in the burden of nonalbicans candida species. In other words, reliance on fluconazole has created selective pressure promoting the emergence of *Candida glabrata*, *Candida krusei*, and other nonalbicans candida. One recent review noted that in 90% of the *C krusei* infections at that institution, patients had received prophylaxis with fluconazole.[44] Along with increases in *S viridans* bacteremias, quinolones-based prophylactic strategies have been found to correlate with isolation of pathogens that were traditionally sensitive to this class but no longer are. For example, at the Memorial Sloan Kettering Cancer Center, 14% *Escherichia coli* are now resistant to ciprofloxacin while this organism was uniformly sensitive to quinolones prior to their expanded use for prophylaxis.[45] Similar patterns have been noted for other pathogens such as *P aeruginosa*.

Blood cultures should be done routinely, but are of limited value in confirming the etiology of pneumonia unless the pathogen has a high propensity for blood (*Streptococcus pneumoniae*) or the patient is neutropenic. Special culture media are required for the suspicion of atypical mycobacteria or nocardia. Other specimens should be obtained, depending on the clinical setting, such as skin biopsy, cerebrospinal fluid, serologies, and antigenemia. None of these noninvasive tests, however, should replace a direct pulmonary investigation.

Uniformly, immunosuppressed patients evaluated for pulmonary infiltrates report dyspnea. Chest pain and cough are also frequently noted. Each of these complaints is nonspecific. Objective testing reveals varying degrees of hypoxemia. The absence of a fever may suggest cardiogenic pulmonary edema but does not exclude other infectious or noninfectious etiologies; however, the presence of a fever may be related to the pulmonary lesions, the medications the patient is receiving (*eg*, amphotericin B), or an underlying malignancy. Patterns noted on chest radiographs and CT scans are more helpful. Table 5 outlines general patterns seen but should only serve as a general guide to clinicians. No one radiographic finding is pathognomonic for a specific process. Unilateral alveolar infiltrates may represent a bacterial pneumonia, an early fungal infection, or DAH.

Standard chest radiographs in immunosuppressed patients should be viewed as a screening test, and we encourage the early use of CT scans. In a study of 87 consecutive patients with febrile neutropenia, Heussel and colleagues[46] noted that in 50% of subjects, the CT scan revealed a pulmonary lesion not seen on the radiograph. A similar study in renal transplant recipients confirmed that the chest radiograph might initially be normal in immunosuppressed patients with pulmonary complaints, while a subsequent CT scan demonstrates multiple abnormalities.[47] In both of these reports, reliance on early CT scanning led to alterations in patient management.[47] A larger, follow-on study of febrile neutropenia, examining only patients with normal chest radiographs, underscored the value of chest CTs.[48] Of 112 subjects, the CT scan showed pneumonia in approximately 60%[48]; based on these findings, the investigators concluded that the sensitivity and specificity of CT scans were superior to the screening value of the standard chest radiograph. In addition to identifying pulmonary pathology that otherwise would be missed with plain radiographs, chest CTs helps guide invasive diagnostic procedures. A chest CT more easily allows one to

Table 5—*Radiographic Patterns and Etiologies of Infiltrates in the Immunosuppressed Patient**

Pattern of Infiltrate	Potential Etiologies	
	Infectious	Noninfectious
Focal infiltrate	Any type of organism	BOOP, DAH, disease progression, drug toxicity, GVHD, PAP, PTLD, radiation toxicity
Diffuse infiltrates	Legionella, mycobacterial (tuberculous and nontuberculous), *P carinii*, viruses	DAH, disease progression (particularly leukemic infiltrates or lymphangitic spread of tumor), drug toxicity, engraftment syndrome, GVHD, IPS, PAP, PTLD, radiation toxicity
Cavitary infiltrates and/or nodules	Bacteria, fungi, mycobacteria, *P carinii*, viruses (small nodules)	Disease progression, drug toxicity

*IPS = idiopathic pneumonia syndrome; PAP = pulmonary alveolar proteinosis; see Table 2 for expansion of other abbreviation.

Downloaded from chestjournals.org on February 14, 2007
Copyright © 2004 by American College of Chest Physicians

determine where specifically to perform BAL or TBB or where to target SLB.

Bronchoscopy remains a central tool in the evaluation of pulmonary infiltrates in the immunosuppressed host, although it is worth obtaining sputum for analysis prior to bronchoscopy. Sputum analysis is often low yield and may be difficult to interpret; however, a positive culture finding may be valuable if agents are isolated that normally do not inhabit the oropharynx (particularly mycobacteria, legionella, and certain fungi). Many conditions, moreover, can only be diagnosed by bronchoscopy. For example, BAL and TBB have a high yield for the diagnosis of both CMV and *P carinii* infection. Empiric therapy for either of these conditions based purely on clinical criteria would be unacceptable given the toxicities associated with the potential treatment options. Additionally, although many noninfectious processes remain diagnoses of exclusion some, such as DAH, can easily be identified with bronchoscopy. Finally, for most noninfectious conditions, corticosteroids are used. These may exacerbate an undiagnosed pulmonary infection. Thus, the clinician must aggressively attempt to exclude infection prior to administration of corticosteroids.

The sensitivity of BAL varies based on the population studied. In SOT patients, the sensitivity of BAL for CMV has been noted to range from 22 to 61%.[49,50] In immunosuppressed cancer patients and HSCT recipients, the sensitivity of BAL for CMV is higher (85 to 95%). Irrespective of the cause of immunosuppression, BAL is much less sensitive for fungal infections. As noted earlier, the yield of BAL is approximately 50% for Aspergillus.[6,10] Conversely, BAL is a sensitive tool for the diagnosis of *P carinii*. In SOT patients, BAL is diagnostic in 85 to 90% of cases; in HSCT and persons with hematologic malignancies, BAL leads to diagnosis in 82 to 100% of infections.[49,50]

The standard for diagnosing pulmonary infection is bronchoscopic sampling with lavage. The yield of protected brush sampling and TBB in the same procedure may be additive, but increases the likelihood of complications. Lavage is safe, minimally invasive, reproducible, and often leads to a quick diagnosis. In the largest study of bronchoscopy in immunocompromised subjects with pulmonary infiltrates, Rano and colleagues[51] noted that three variables independently predicted mortality: increasing severity of illness, need for mechanical ventilation, and delay in diagnosis. That severity of illness and use of mechanical ventilation are associated with poor outcome is not surprising. Their most significant finding was the implication that delays in diagnosis increased the risk for death. In subjects in whom there was a delay of > 5 days in identification of the cause of the pulmonary infiltrates, the risk for death increased by more than threefold. In this study, the delay was not a surrogate marker for severity of illness. One might suspect that those who eventually died were simply too ill to tolerate bronchoscopy. This, however, was not the case. Diagnostic delay also has implication for the importance of initial therapy. Multiple researchers have demonstrated that initially inappropriate antibiotic selections adversely affect outcomes.[52] When the list of potential etiologies is so broad, as is the case in the immunocompromised patient with pulmonary infiltrates, ensuring appropriate initial therapy is difficult. It therefore becomes necessary to rapidly eliminate certain possibilities so as to tailor the treatment plan to the needs of the individual patient. In Figure 1, we present our approach to pulmonary infiltrates in the immunocompromised subject.

What is the role for SLB in immunocompromised patients who acquire pulmonary infiltrates? If the clinician hopes to achieve diagnostic certainty, SLB is considered the "gold standard." Unlike bronchoscopy, SLB results in tissue specimens large enough to facilitate comprehensive pathologic and microbiological evaluation. Many immunosuppressed patients, however, are at increased risk for complications following SLB. Given the poor prognosis for immunosuppressed individuals with undiagnosed infiltrates, one also needs to consider if SLB will yield a diagnosis amenable to intervention. In other words, how will the results of SLB alter management? Prior reports detailing the influence of SLB on outcomes in these subjects have mainly consisted of small, retrospective case series. On average, in fewer than half of patients sent for SLB, the results lead to alterations in treatment. In a review of 67 persons with hematologic malignancy undergoing SLB, White et al[53] reported that the procedure prompted changes in therapy in 57% of patients; however, in the patients who were either neutropenic or receiving mechanical ventilation, the yield was lower. These investigators concluded that in this specific subgroup of patients, SLB remained a "high-risk, low-yield" procedure. In lung transplant recipients, Weill and colleagues[54] observed similar results; in only 29% of all patients undergoing SLB did the procedure result in a change in therapy. These patients, unlike those with hematologic malignancies, had relatively few complications. In short, the decision to pursue SLB must be individualized and include an assessment of both the likelihood that SLB will alter therapy and the probability that the patient will tolerate the surgery.

Downloaded from chestjournals.org on February 14, 2007
Copyright © 2004 by American College of Chest Physicians

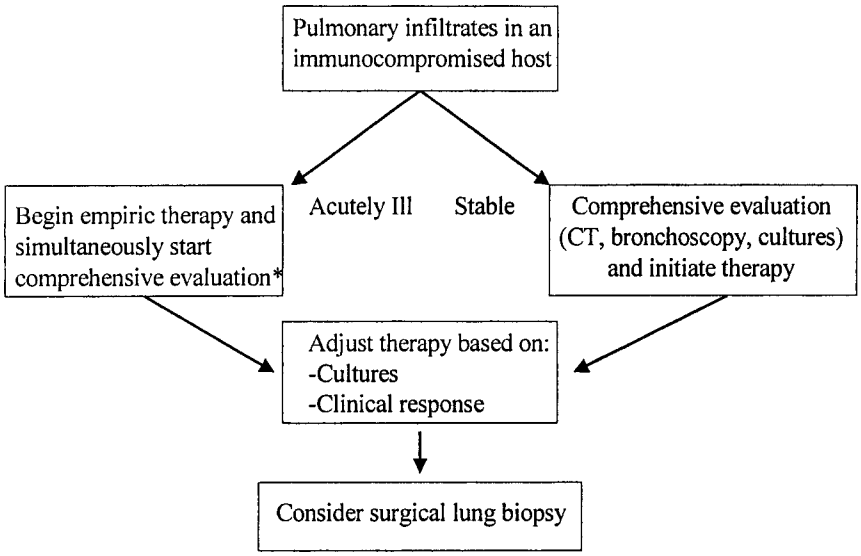

FIGURE 1. Approach to immunocompromised patient with pulmonary infiltrates. *Empiric therapy should include coverage for bacterial pathogens and encompass Gram-negative and Gram-positive organisms. Added therapy for *P carinii*, fungus, and viruses should be considered depending on the patient's severity of illness, underlying immune status, and prophylaxis used.

OUTCOMES

The evolution of pulmonary infiltrates in an immunocompromised patient is a worrisome sign. Each of the possible etiologies for pulmonary injury in these individuals is associated with a significant risk for mortality. In a review of 50 liver transplant recipients with pulmonary infiltrates, Torres et al[4] noted a 32% mortality rate. Duran and coworkers[55] noted a similar mortality from pulmonary complications following liver transplant. Although diagnostic delay independently increased the risk for death in immunosuppressed hosts with pulmonary infiltrates, the mortality rate for the entire cohort examined by Rano and colleagues[4] was 39%. Pulmonary complications after HSCT confer an even worse prognosis. For HSCT patients requiring mechanical ventilation, multiple studies document that mortality rates are consistently > 80%.[1]

Improving on these outcomes requires a multifaceted approach. First, as noted above, early identification of the cause for the pulmonary lesions increases the likelihood of survival. With early diagnosis, appropriate therapies can be instituted and potentially toxic treatments discontinued. Second, careful attention to the antibiogram of an institution can help clinicians tailor initial antibiotic therapies so they are more likely to cover resistant pathogens. Ibrahim et al[56] demonstrated that inappropriate antibiotic selections increased the risk for mortality related to bacteremia nearly sevenfold. The organisms most often not covered by the antibiotics given included methicillin-resistant *S aureus*, vancomycin-resistant enterococci, and Candida. Immunosuppressed patients, because of their underlying diseases and the medications they receive, are at higher risk for infection with such organisms. As such, they may be more prone to initially receive inappropriate antibiotic treatment. Finally, reliance on noninvasive ventilation rather than traditional mechanical ventilation may offer a survival advantage to immunosuppressed individuals with respiratory failure. Antonelli et al[57] randomized patients who acquired respiratory failure after SOT to either treatment with noninvasive ventilation or standard treatment with supplemental oxygen. The use of noninvasive ventilation was able to stave off the need for endotracheal intubation. Seven of 10 patients receiving supplemental oxygen alone later required endotracheal intubation, as compared to 20% of those supported with noninvasive ventilation ($p = 0.002$).[57] Use of noninvasive ventilation failed to alter hospital mortality rates; however, the trial[57] was not adequately powered to address this issue. Hilbert et al[58] conducted a similar trial and randomized 52 immunosuppressed patients with pulmonary infiltrates and early respiratory failure to either noninvasive support or standard treatment. Patients who were hemodynamically unstable or had another immediate reason for endotracheal intubation were excluded. The study included a wide variety of patients, with one third having undergone HSCT and 15% were post-SOT.[58] The researchers had predefined criteria for endotracheal intubation. Patients in the noninvasive ventilation study arm expe-

Downloaded from chestjournals.org on February 14, 2007
Copyright © 2004 by American College of Chest Physicians

rienced greater improvements in oxygenation and were less likely to require endotracheal intubation. These variations translated into significant differences in both ICU and hospital mortality rates: persons receiving noninvasive ventilation were 40% less likely to die than individuals in the control arm.[57]

Conclusion

Pulmonary infiltrates remain a vexing problem in the care of the immunosuppressed patient. Such infiltrates occur commonly following chemotherapy, HSCT, and SOT. With the increasing use of these treatment modalities and the growing potency of immunosuppressive regimens, physicians will more frequently be asked to evaluate and to care for these individuals. The differential diagnosis of pulmonary lesions in this setting is broad. It is important to search for both infectious and noninfectious etiologies. Frustratingly, many of the processes that result in pulmonary infiltrates present in similar fashions with nonspecific syndromes comprised of infiltrates, dyspnea, and hypoxemia. No one pattern of symptoms or radiographic findings conclusively excludes a diagnostic possibility. In addition to early broad-spectrum antibiotic coverage, early bronchoscopy remains crucial to the management of immunocompromised subjects.

References

1 Shorr AF, Moores LK, Edenfield WJ, et al. Mechanical ventilation in hematopoietic stem cell transplantation: can we effectively predict outcomes? Chest 1999; 116:1012–1018
2 White P. Evaluation of pulmonary infiltrates in critically ill patients with cancer and marrow transplant. Crit Care Clin 2001; 17:647–670
3 Rano A, Agusti C, Jimenez P, et al. Pulmonary infiltrates in non-HIV immunocompromised patients: a diagnostic approach using noninvasive and bronchoscopic procedures. Thorax 2001; 56:379–387
4 Torres A, Ewing S, Insausti J, et al. Etiology and microbial patterns of pulmonary infiltrates in patients with orthotopic liver transplantation. Chest 2000; 117:494–502
5 Knirsch CA, Jakon K, Schoonmaker MS, et al. An outbreak of Legionella pneumonia in transplant patients: evaluation, molecular epidemiology, and control. Am J Med 2000; 108:290–295
6 Paterson DL, Singh N. Invasive Aspergillosis in transplant recipients. Medicine 1999; 78:123–138
7 Marr KA, Carter RA, Crippa F, et al. Epidemiology and outcome of mould infections in hematopoietic stem cell transplant recipients. Clin Infect Dis 2002; 34:909–917
8 Jantunen E, Ruutu P, Niskanen L, et al. Incidence and risk factors for invasive fungal infections in allogeneic BMT recipients. Bone Marrow Transplant 1997; 19:801–808
9 Caillot D, Couaillier JF, Bernard A, et al. Increasing volume and changing characteristics of invasive pulmonary aspergillosis on sequential thoracic computed tomography scans in patients with neutropenia. J Clin Oncol 2001; 19:253–259
10 Patterson TF, Kirkpatrick WR, White M, et al. Invasive Aspergillosis: disease spectrum, treatment practices, and outcomes. Medicine 2000; 79:250–260
11 Wingard JR. Opportunistic infections after blood and marrow transplantation. Transpl Infect Dis 1999; 1:3–20
12 Maartens J, Vehaegen J, Lagrow K, et al. Screening for circulating galactomannan as a noninvasive diagnostic tool for invasive Aspergillosis in prolonged neutropenic patients and stem cell transplantation recipients: a prospective validation. Blood 2001; 97:1604–1610
13 Herbrecht R, Letscher-Bru V, Oprea C, et al. Aspergillus galactomannan detection in the diagnosis of invasive aspergillosis in cancer patients. J Clin Oncol 2002; 20:1898–1906
14 Haron E, Vartivarian S, Anaissie E, et al. Primary Candida pneumonia: experience at a large cancer center and review of the literature. Medicine 1993; 72:137–142
15 Hamacher J, Spiliopoulous A, Kurt AM, et al. Pre-emptive therapy with azoles in lung transplant patients: Geneva Lung Transplantation Group. Eur Respir J 1999; 13:180–186
16 Wendt CH. Community respiratory viruses: organ transplant recipients. Am J Med 1997; 102:31–36
17 Goodrich J. A comparison of cytomegalovirus and community respiratory viruses in immunocompromised patients. Am J Med 1997; 102:37–41
18 Sternberg RI, Baugman RP, Dohn MN, et al. Utility of bronchoalveolar lavage in assessing pneumonia in immunosuppressed renal transplant recipients. Am J Med 1993; 95:358–364
19 Yale SH, Limper AH. Pneumocystis carinii pneumonia in patients without acquired immunodeficiency syndrome: associated illness and prior corticosteroid therapy. Mayo Clin Proc 1996; 71:5–13
20 Byrd JC, Hargis JB, Kester KE, et al. Opportunistic pulmonary infections with fludarabine in previously treated patients with low-grade lymphoid malignancies: a role for *Pneumocystis carinii* pneumonia prophylaxis. Am J Hematol 1995; 49:135–142
21 Thomas CF, Limper AH. Pneumocystis pneumonia: clinical presentation and diagnosis in patients with and without acquired immune deficiency syndrome. Semin Respir Infect 1998; 13:289–295
22 Limper AH, Offord KP, Smith TF, et al. *Pneumocystis carinii* pneumonia: differences in lung parasite number and inflammation in patients with and without AIDS. Am Rev Respir Dis 1989; 140:1204–1209
23 Roy V, Weisdorf D. Mycobacterial infections following bone marrow transplantation: a 20 year retrospective review. Bone Marrow Transplant 1997; 19:467–470
24 Singh N, Paterson DL. Mycobacterium tuberculosis infection in solid-organ transplant recipients: impact and implications for management. Clin Infect Dis 1998; 27:1266–1277
25 Crawford SW. Noninfectious lung disease in the immunocompromised host. Respiration 1999; 66:385–395
26 Kurshid I, Anderson LC. Noninfectious pulmonary complications after bone marrow transplantation. Postgrad Med J 2002; 78:257–262
27 Briasoulis E, Pavlidis N. Noncardiogenic pulmonary edema: an unusual and serious complication of anticancer therapy. Oncologist 2001; 6:153–161
28 Masson RG, Kirkorian J, Lukl P, et al. Pulmonary microvascular cytology in the diagnosis of lymphangitic carcinomatosis. N Engl J Med 1989; 321:71–76
29 Savage P, Waxman J. Post-transplantation lymphoproliferative disease. QJM 1997; 90:497–503
30 Preiksaitis JK. Epstein-Barr virus infection and malignancy in solid organ transplant recipients: strategies for prevention and

Downloaded from chestjournals.org on February 14, 2007
Copyright © 2004 by American College of Chest Physicians

treatment. Transpl Infect Dis 2001; 3:56–59
31 Tanner JE, Alfieri C. The Epstein-Barr virus and post-transplant lymphoproliferative disease: interplay of immunosuppression, EBV, and the immune system in disease pathogenesis. Transpl Infect Dis 2001; 3:60–69
32 Curtis RE, Travis LB, Rowlings PA, et al. Risk of lymphoproliferative disorders after bone marrow transplantation: a multi-institutional study. Blood 1999; 94:2208–2216
33 Rossi SE, Erasmus JJ, McAdams HP, et al. Pulmonary drug toxicity: radiologic and pathologic manifestations. Radiographics 2000; 20:1245–1259
34 Shorr AF, Abbott KC, Agadoa LY. Acute respiratory distress syndrome following renal transplantation: epidemiology, risk factors, and outcomes. Crit Care Med 2003; 31:1325–1330
35 Dimopoulou I, Galani H, Dafni U, et al. A prospective study of pulmonary function in patients treated with paclitaxel and carboplatin. Cancer 2002; 94:452–458
36 Helman DL, Byrd JC, Ales NC, et al. Fludarabine-related pulmonary toxicity: a distinct clinical entity in chronic lymphoproliferative syndromes. Chest 2002; 122:785–790
37 Morelon E, Stern M, Israel-Beit D, et al. Characteristics of sirolimus-associated interstitial pneumonitis in renal transplant patients. Transplantation 2001; 72:787–790
38 Arbetter KR, Prakash UB, Tazelaar HD, et al. Radiation-induced pneumonitis in the "nonirradiated" lung. Mayo Clin Proc 1999; 74:27–36
39 Afessa B, Tefferi A, Litzow MR, et al. Diffuse alveolar hemorrhage in hematopoietic stem cell transplant recipients. Am J Respir Crit Care Med 2002; 166:641–745
40 DeLassence A, Fleury-Fieth J, Escudier E, et al. Alveolar hemorrhage: diagnostic criteria and results in 194 immunocompromised hosts. Am J Respir Crit Care Med 1995; 151:157–163
41 Spitzer TR. Engraftment syndrome following hematopoietic stem cell transplantation. Bone Marrow Transplant 2001; 27:893–898
42 Marr KA, Patterson T, Denning D. Aspergillosis: pathogenesis, clinical manifestations, and therapy. Infect Dis Clin North Am 2002; 16:875–894
43 Elting LS, Bodey GP, Keefe BH. Septicemia and shock syndrome due to viridans streptococci: a case-control study of predisposing factors. Clin Infect Dis 1992; 14:1201–1207
44 Abbas J, Bodey GP, Hanna HA, et al. *Candida krusei* fungemia: an escalating serious infection in immunocompromised patients. Arch Intern Med 2000; 160:2659–2664
45 Sepkowitz KA. Antibiotic prophylaxis in patients receiving hematopoietic stem cell transplant. Bone Marrow Transplant 2002; 29:367–371
46 Heussel CP, Kauczor HU, Heussel G, et al. Early detection of pneumonia in febrile neutropenic patients: use of thin-section CT. AJR Am J Roentgenol 1997; 169:1347–1353
47 Gulati M, Kaur R, Jha V, et al. High-resolution CT in renal transplant patients with suspected pulmonary infections. Acta Radiol 2000; 41:237–241
48 Heussel CP, Kauczor HU, Heussel GE, et al. Pneumonia in febrile neutropenic patients and in bone marrow and blood stem-cell transplant recipients: use of high-resolution computed tomography. J Clin Oncol 1999; 17:796–805
49 Nusair S, Kramer MR. The role of fibre-optic bronchoscopy in solid organ, transplant patients with pulmonary infections. Respir Med 1999; 93:621–629
50 Murray PV, O'Brien ME, Padhani AR, et al. Use of first line bronchoalveolar lavage in the immunosuppressed oncology patient. Bone Marrow Transplant 2001; 27:967–971
51 Rano A, Agusti C, Banito N, et al. Prognostic factors of non-HIV immunocompromised patients with pulmonary infiltrates. Chest 2002; 122:253–261
52 Iregui M, Ward S, Sherman G, et al. Clinical importance of delays in the initiation of appropriate antibiotic treatment for ventilator-associated pneumonia. Chest 2002; 122:262–268
53 White DA, Wong PW, Downey R. The utility of open lung biopsy in patients with hematologic malignancies. Am J Respir Crit Care Med 2002; 161:723–729
54 Weill D, McGriffin DC, Zorn GL, et al. The utility of open lung biopsy following lung transplantation. J Heart Lung Transplant 2000; 19:852–857
55 Duran FG, Piqueras B, Romero M, et al. Pulmonary complications following orthotopic liver transplant. Transpl Int 1998; 11(Suppl 1):S255–S259
56 Ibrahim EH, Sherman G, Ward S, et al. The influence of inadequate antimicrobial treatment of bloodstream infections on patient outcomes in the ICU setting. Chest 2000; 118: 146–155
57 Antonelli M, Conti G, Maurizio B, et al. Noninvasive ventilation for treatment of acute respiratory failure in patients undergoing solid organ transplantation: a randomized trial. JAMA 2000; 283:235–241
58 Hilbert G, Gruson D, Varges F, et al. Noninvasive ventilation in immunosuppressed patients with pulmonary infiltrates, fever, and acute respiratory failure. N Engl J Med 2001; 344:481–487

Downloaded from chestjournals.org on February 14, 2007
Copyright © 2004 by American College of Chest Physicians

Pulmonary Infiltrates in the Non-HIV-Infected Immunocompromised Patient: Etiologies, Diagnostic Strategies, and Outcomes

Andrew F. Shorr, Gregory M. Susla and Naomi P. O'Grady

Chest 2004;125;260-271
DOI 10.1378/chest.125.1.260

This information is current as of February 14, 2007

Updated Information & Services	Updated information and services, including high-resolution figures, can be found at: http://chestjournals.org/cgi/content/full/125/1/260
References	This article cites 57 articles, 24 of which you can access for free at: http://chestjournals.org/cgi/content/full/125/1/260#BIBL
Rapid Response	1 rapid response(s) have been posted to this article, which you can access for free at: http://chestjournals.org/cgi/eletters/125/1/260
Permissions & Licensing	Information about reproducing this article in parts (figures, tables) or in its entirety can be found online at: http://chestjournals.org/misc/reprints.shtml
Reprints	Information about ordering reprints can be found online: http://chestjournals.org/misc/reprints.shtml
Email alerting service	Receive free email alerts when new articles cite this article sign up in the box at the top right corner of the online article.
Images in PowerPoint format	Figures that appear in CHEST articles can be downloaded for teaching purposes in PowerPoint slide format. See any online article figure for directions.

AMERICAN COLLEGE OF CHEST PHYSICIANS®

Downloaded from chestjournals.org on February 14, 2007
Copyright © 2004 by American College of Chest Physicians