

Critical care considerations of hematopoietic stem cell transplantation

Ayman O. Soubani, MD

Objective: To review the available clinical data on the critical care complications of hematopoietic stem cell transplantation (HSCT).

Data Source: The MEDLINE database and references from the identified articles related to the critical care in HSCT.

Conclusion: HSCT is an important treatment for a variety of malignant and nonmalignant conditions. The procedure is, however, limited by significant complications that may involve every organ of the body. Up to 40% of HSCT recipients are admitted to the intensive care unit as a result of severe complications related to the transplantation. The outcome of those critically ill patients

has been traditionally poor. However, recent advances in the transplantation procedure, diagnostic studies, antimicrobial prophylaxis and therapy, and intensive care unit care have improved the outcome of these patients. The increasing number of HSCTs performed annually, the unique complications that develop in these patients, and the improvement in the intensive care unit outcome make knowledge about the critical care aspect of HSCT an essential part of the current practice of critical care medicine. (Crit Care Med 2006; 34[Suppl.]:S251–S267)

KEY WORDS: hematopoietic stem cell transplantation; complications; critical care; outcome

Hematopoietic stem cell transplantation (HSCT) is an important treatment for a variety of malignant and nonmalignant conditions. During the last few decades, there has been significant progress in the procedure and care of patients after transplantation. Annually, there are >30,000 cases of autologous HSCT and 15,000 cases of allogeneic HSCT performed worldwide (1). Hematopoietic stem cells may be obtained from bone marrow, peripheral blood, or umbilical cord blood. Depending on the source of these stem cells, HSCT is classified as autologous if the cells are taken from an individual patient and stored for reinfusion after high-dose chemotherapy, and it is classified as allogeneic if the stem cells are donated from another individual (who may or may not be related). In the case of allogeneic HSCT, the conditioning regimen before transplantation may be myeloablative, in which supralethal doses of chemotherapy and irradiation are given, leading to significant toxicity and immu-

nosuppression. More recently, nonmyeloablative regimens have been used to minimize the toxicity related to the conditioning regimen and allow for immunologically mediated killing of tumor cells (graft vs. tumor effect) (2–4).

Despite of the advances in HSCT, the procedure remains limited by the high rate of severe complications that are generally related to toxicity of conditioning regimen, immunosuppression, and graft-vs.-host disease (GVHD). These complications are commonly associated with critical illness and require admission or transfer to the intensive care unit (ICU). The range of transfer to the ICU is between 11% and 40% of all HSCT recipients (5, 6). More than 60% of these patients require mechanical ventilation, which is associated with very high mortality (6).

There is a wide spectrum of complications seen in critically ill HSCT recipients (Table 1). These complications usually develop in the first 100 days after HSCT and are associated with a high mortality rate (6). Moreover, severe complications in critically ill HSCT recipients tend to follow a predictable timeline that helps in the diagnostic and therapeutic approaches (Fig. 1). This article focuses on the complications in critically ill HSCT recipients, reviewing the risk factors, diagnostic studies, outcomes, and suggested approaches to management.

Pulmonary Complications

Acute respiratory failure is the most common reason for care in the ICU after HSCT (7, 8). In a recent study of HSCT recipients admitted to the ICU, acute respiratory failure was the reason for transfer in 48% of patients (6). Of patients with acute respiratory failure, 60–85% require mechanical ventilation (5–23). The prognosis of those patients who develop acute respiratory failure after HSCT, especially those who are intubated, is very poor, with a mortality rate approaching 100%. However, recent studies show an improvement in the outcome of these patients (Table 2). In addition to developing acute respiratory failure as a result of many of the complications mentioned in this article, the following pulmonary problems are unique causes of acute respiratory failure after HSCT.

Engraftment Syndrome. Engraftment syndrome develops within 96 hrs of engraftment (neutrophils, ≥ 500 cells/cm³) (24). The syndrome is reported in 7–35% of HSCT recipients (25–29). Engraftment syndrome is described following autologous HSCT; however, it is also seen in patients following allogeneic transplantation and is characterized by fever, erythematous rash, diarrhea, renal impairment, and diffuse pulmonary infiltrates (noncardiogenic pulmonary edema due to capillary leak) (25, 26, 30). In the most

From the Division of Pulmonary, Critical Care, and Sleep Medicine, Wayne State University School of Medicine, Detroit, MI.

The author has not disclosed any potential conflicts of interest.

Copyright © 2006 by the Society of Critical Care Medicine and Lippincott Williams & Wilkins

DOI: 10.1097/01.CCM.0000231886.80470.B6

Table 1. Major critical care complications after allogeneic and autologous hematopoietic stem cell transplantation (HSCT)

Complication	Allogeneic HSCT	Autologous HSCT
Pulmonary		
Engraftment syndrome	+	++
DAH	++	++
IPS	++	+
BOOP	+	±
BO	++	±
Severe infections		
Bacteria	+++	++
CMV	++	+
RSV	+	±
HZV	+	±
<i>Candida</i>	++	++
<i>Aspergillus</i>	+++	+
PCP	+	±
Cardiac		
Congestive heart failure	+++	++
Pericardial effusion	+	+
Endocarditis	+	+
Arrhythmias	++	++
Gastrointestinal		
GVHD of intestine	++	±
Pseudoobstruction	++	+
Acute pancreatitis	+	+
Enteritis	+++	+
GI bleeding	++	+
Hepatic		
VOD	++	++
Acute GVHD of the liver	++	±
Viral hepatitis	+	±
Renal		
Tumor lysis syndrome	+	±
DMSO-induced nephropathy	±	+
Hemorrhagic cystitis	++	+
HUS	++	+
Cyclosporine A nephropathy	++	±
Hyponatremia	++	+
Neurologic		
CVA	+	±
CNS infections	+	±
Metabolic encephalopathy	++	+
Chronic GVHD	+	±
Hematologic		
TTP	++	+

DAH, diffuse alveolar hemorrhage; IPS, idiopathic pneumonia syndrome; BOOP, bronchiolitis obliterans organizing pneumonia; BO, bronchiolitis obliterans; CMV, cytomegalovirus; RSV, respiratory syncytial virus; HZV, herpes zoster virus; PCP, *Pneumocystis carinii* pneumonia; GVHD, graft-vs.-host disease; GI, gastrointestinal; VOD, veno-occlusive disease; DMSO, dimethyl sulfoxide; HUS, hemolytic uremic syndrome; CVA, cerebrovascular accident; CNS, central nervous system; TTP, thrombotic thrombocytopenic purpura. +++, common; ++, less common; +, rare; ±, extremely rare.

severe cases, it may lead to profound hemodynamic collapse and multiple organ system failure (MOSF) (24). The syndrome coincides with neutrophil recovery and is postulated to be due to the release of cytokines by these neutrophils (31, 32). The use of granulocyte colony-stimulating factor may increase the prevalence of the syndrome (33). Treatment is supportive, some of these patients require mechanical ventilation, and granulocyte colony-stimulating factor should be discontinued. Prompt use of systemic

corticosteroids has been shown to decrease the duration and complications related to this syndrome (24, 25, 28). Mortality secondary to engraftment syndrome is around 25% (33).

Diffuse Alveolar Hemorrhage. Diffuse alveolar hemorrhage (DAH) is one of the most important noninfectious pulmonary complications following HSCT, leading to acute respiratory failure. DAH is reported with an average frequency of 5% following HSCT (range, 2–14% in different reports) (34–39). DAH is slightly more

common following autologous rather than allogeneic HSCT (34–37, 40–46). Furthermore, DAH is estimated to constitute 40% of all causes of acute respiratory failure admitted to the ICU (20, 39, 47). In a recent study, 85% of patients with DAH were admitted to the ICU, and 77% of those required mechanical ventilation (48). The main risk factors for DAH are intensive chemotherapy before HSCT, total body irradiation, older age, white blood cell count recovery, and renal insufficiency (41, 42, 49). Pathogenesis of DAH is injury of the endothelial cells of small blood vessels and thrombotic microangiopathy due to high-dose chemotherapy (39). In addition, there is an element of alveolitis that may be related to acute GVHD (50). Cytokines such as interleukin-12 and tumor necrosis factor- α are believed to mediate the pathologic changes seen in DAH (39, 50). These findings correlated with marrow recovery and influx of neutrophils to the lungs (34). DAH usually develops in the first 30 days (mostly in the first 11–19 days); however, it may develop later on following HSCT (39, 42, 48, 51). The syndrome is characterized by progressive dyspnea, cough, fever, and hypoxemia. Hemoptysis is rare. The chest radiograph shows bilateral interstitial and alveolar infiltrates that tend to be perihilar and in lower lobes (38). These radiologic findings may precede by an average of 3 days the clinical presentation (38). High-resolution computerized tomography of the chest shows bilateral ground glass infiltrates (42, 52). Although many of these patients have thrombocytopenia and coagulopathy, there is no correlation between these factors and the development of DAH (42). Bronchoalveolar lavage (BAL) is the best tool to diagnose DAH. The most common finding early in the course of DAH is a progressively bloodier BAL fluid return, and later, the only finding may be hemosiderin-laden macrophages (39, 42). However, the absence of either finding does not exclude the diagnosis of DAH. The following criteria are suggested to define this syndrome: 1) evidence of widespread alveolar injury manifested by multilobar pulmonary infiltrate, symptoms and signs of pneumonia, and abnormal pulmonary physiology with increased alveolar to arterial oxygen gradient and restrictive ventilatory defect; 2) absence of infection that may be associated with similar presentation; and 3) BAL showing progressively bloodier return from three separate subsegmental bronchi or the

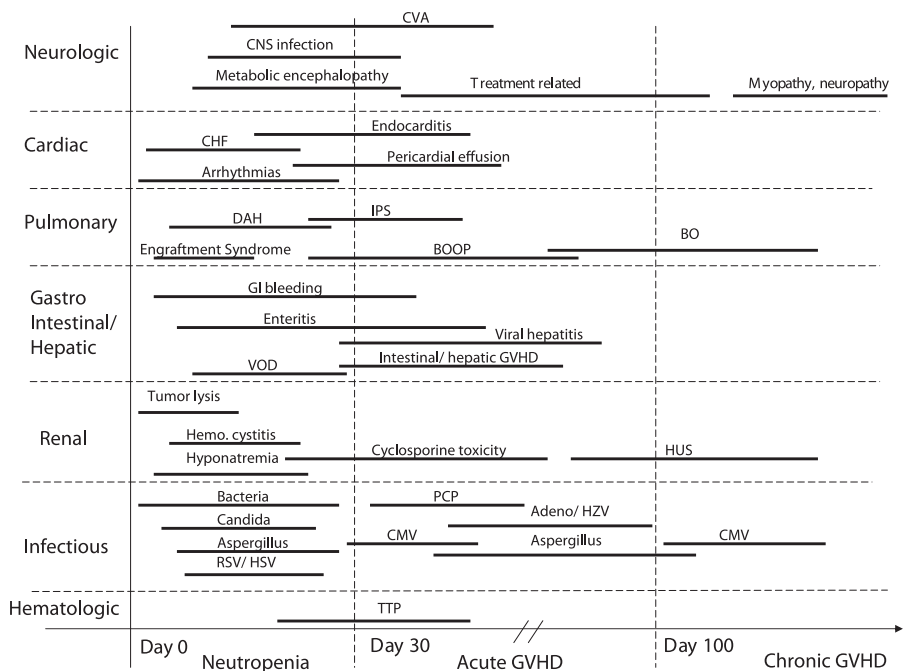


Figure 1. Temporal relationship between hematopoietic stem cell transplantation and critical care complications. CVA, cerebrovascular accident; CNS, central nervous system; CHF, congestive heart failure; IPS, idiopathic pneumonia syndrome; DAH, diffuse alveolar hemorrhage; BO, bronchiolitis obliterans; BOOP, bronchiolitis obliterans organizing pneumonia; GI, gastrointestinal; GVHD, graft-vs.-host disease; VOD, veno-occlusive disease; HUS, hemolytic uremic syndrome; PCP, *Pneumocystis carinii* pneumonia; HZV, herpes zoster virus; CMV, cytomegalovirus; RSV/HSV, respiratory syncytial virus/herpes simplex virus; TTP, thrombotic thrombocytopenic purpura.

presence of $\geq 20\%$ hemosiderin-laden macrophages or the presence of blood in $\geq 30\%$ of the alveolar surfaces of lung tissue (39). The treatment of DAH is supportive. Patients are commonly treated by high-dose systemic corticosteroids, although there are no prospective randomized studies to confirm the benefit of this treatment in HSCT recipients. In retrospective studies, high-dose methylprednisolone (125–250 mg every 6 hrs for 4–5 days and then tapered over 2–4 wks) was associated with a better outcome compared with low-dose (<30 mg/day) or no corticosteroids groups (34, 39, 48). The prognosis of DAH is poor, with a mortality rate of 72% (range, 64–100%) (48). Only 15% die due to progressive respiratory failure; however, the most common causes of death are MOSF and sepsis (48). In a recent analysis of patients with DAH, the mortality rate was less (48%), and the prognosis was better in patients with autologous HSCT and early onset of DAH (<1 month) (48).

Idiopathic Pneumonia Syndrome. Idiopathic pneumonia syndrome (IPS) is a syndrome of diffuse lung injury that develops following HSCT in which an infec-

Table 2. Survival of adult bone marrow transplant recipients admitted to medical intensive care units (MICUs): Literature review

First Author (Reference No.)	Year	No. of Patients (% on MV)	ICU Survival, % (% on MV)	Hospital Survival, % (% on MV)	Long-Term Survival, % ^a	Predictors of Outcome
Crawford (9)	1988	232 (100)	27	NR	7	Age
Torrecilla (10)	1988	25	6	NR	NR	MV for >7 days, MOSF > 3, septic shock, neutropenia, GVHD, LOS in MICU >10 days
Denardo (11)	1989	50 (88)	NR	18 (9)	NR	MV for >4 days, LOS in MICU
Martin (12)	1990	24 (100)	NR	2 (8)	NR	NR
Dees (13)	1990	8 (100)	0 (0)	NR	NR	NR
Afessa (5)	1992	35 (77)	NR	23 (7)	NR	MV, MOSF
Crawford (14)	1992	348 (100)	NR	15 (4)	10 (3)	NR
Paz (15)	1993	36 (75)	33 (4)	NR	NR	MV, APACHE II
Faber-Langendoen (16)	1993	191 (100)	9	NR	3	MV, age >40 yrs, BMT to ICU <90 days
Jackson (17)	1998	116 (79)	23	17	14	Year of BMT, hemodynamic support, bilirubin
Price (18)	1998	115 (42)	45 (19)	NR	NR	MV, allogeneic, infection, GI bleeding, longer time from BMT to MICU
Ewig (8)	1998	52	10	NR	NR	MV, BMT to MICU <90 days
Shorr (19)	1999	17 (100)	NR	18	NR	APACHE II
Kress (7)	1999	44 (45)	39 (45)	NR	NR	MV, allogeneic
Huaranga (20)	2000	60 (100)	18	NR	5	MV, BMT to MICU, GVHD, underlying disease
Staudinger (21)	2000	38 (79)	22	NR	5	MV, septic shock
Khassawneh (22)	2002	78 (100)	NR	26	17	Hepatic, renal failure, lung injury, and pressors
Scott (23)	2002	50 (100)	28	18	12	MOSF, APACHE II
Afessa (253)	2003	112 (63)	67 (26)	54	NR	APACHE III, allogeneic
Soubani (6)	2004	85 (60)	61 (37)	41 (20)	28	MV, MOSF >2, serum lactate level

MV, mechanical ventilation; ICU, intensive care unit; NR, not reported; MOSF, multiple-organ system failure; GVHD, graft vs. host disease; LOS, length of stay; APACHE II, Acute Physiology and Chronic Health Evaluation II; BMT, bone marrow transplantation; GI, gastrointestinal.

^aLong-term survival is more than 6 months after admission to MICU.

tious etiology is not identified. The syndrome is reported in 10% of patients (range, 3–15%) following allogeneic and autologous HSCT and is slightly more common in the former (49, 53–56). It is usually diagnosed in the first 2 months following transplantation, with median onset ranging in different studies from 21 to 65 days (57–60). The main risk factors for IPS are older age, malignancy other than leukemia, lower performance status before transplantation, positive donor cytomegalovirus (CMV) serology, high-dose chemotherapy, total body irradiation, high-grade acute GVHD, and the presence of MOSF (53, 57, 61, 62). The prevalence of IPS is lower in HSCT patients who received nonmyeloablative conditioning regimen (62). A special National Institutes of Health workshop suggested specific diagnostic criteria for IPS, which are (63): 1) evidence of widespread alveolar injury including symptoms and signs of pneumonia, multilobar infiltrates, and evidence of abnormal lung physiology (widening of alveolar–arterial gradient) and 2) absence of active lower respiratory tract infection after appropriate evaluation, including BAL negative for known pathogens. Transbronchial biopsy and surgical lung biopsy are not recommended in most cases. A repeat BAL in 2–14 days is advisable to confirm the absence of infection. The pathogenesis of IPS is not clear. It is probably related to high-dose chemotherapy, as suggested by its occurrence in autologous HSCT (64). The association between IPS and acute GVHD in allogeneic HSCT, on the other hand, suggests that an immune lung injury caused by donor T cells may play a role in the pathogenesis of IPS (56, 63, 65–68). In addition, the nitric oxide pathway may be significant in the lung injury associated with IPS. This is suggested by increased exhaled nitric oxide in autologous HSCT recipients with evidence of IPS (64). The treatment of IPS is supportive. High-dose corticosteroids are commonly used, although their efficacy has not been clearly established (58, 60, 69). Mortality is high, and is estimated to be 74% (range, 60–85%) (49, 62). The majority of these patients die of infectious complications and MOSF. Acute respiratory failure requiring mechanical ventilation was associated with the worst outcome (62).

Bronchiolitis Obliterans Organizing Pneumonia. Bronchiolitis obliterans organizing pneumonia is another late cause of acute lung injury following HSCT. It is

primarily seen in allogeneic HSCT recipients, and the prevalence is reported to be 1.4% (49). The syndrome is believed to be related to GVHD and is characterized histologically by the presence of intraluminal granulation consisting of fibroblasts in the small airways, alveolar ducts, and the alveoli. There is also interstitial infiltration by lymphocytes and macrophages. Bronchiolitis obliterans organizing pneumonia usually develops 1–3 months after HSCT (70–73). Patients usually present with dyspnea, dry cough, and fever. They are commonly hypoxemic and may develop acute respiratory failure requiring mechanical ventilation. The condition is usually misdiagnosed as pneumonia; however, cultures are negative. High-resolution computerized tomography of the chest shows patchy consolidation with ground glass attenuation (52, 74). The diagnosis is confirmed by surgical lung biopsy. Transbronchial biopsy may provide the diagnosis in a small number of patients (75). Establishing the diagnosis is essential because these patients have a good response to long-term systemic corticosteroid therapy (75). The overall case fatality in patients with bronchiolitis obliterans organizing pneumonia following HSCT is 21% (49, 70–73). Bronchiolitis obliterans organizing pneumonia is different from bronchiolitis obliterans, which is an inflammatory disease of the small airways that develops later in the course of allogeneic HSCT (76). It leads to progressive obstructive airway disease with no parenchymal involvement (77). Bronchiolitis obliterans gradually worsens over months to years and patients eventually die of respiratory failure. The treatment of bronchiolitis obliterans is difficult, and these patients do not respond well to systemic corticosteroids (78–81). Chronic therapy with macrolides may slow the progression of this disease (82, 83).

Severe Infections

Severe infections are a major complication following HSCT. They are estimated to be the cause for admission or transfer to the ICU in 23% of patients (6). Furthermore, severe infections are a significant problem in critically ill HSCT recipients, especially those who are on broad-spectrum antibiotics, with indwelling catheters, or who are mechanically ventilated. HSCT recipients are at risk for bacterial and candidal infections; however, they are also prone to a variety of

opportunistic infections such as invasive pulmonary aspergillosis (IPA), CMV, and *Pneumocystis carinii* pneumonia. The main factors that predispose HSCT recipients to these infections are impaired humoral and cellular immunity, neutropenia, breakdown in cutaneous and mucosal barriers, and immunosuppressive therapy.

Bacterial Infections. Bacterial infections remain the main cause of severe infectious complications following HSCT. They may lead to transfer to the ICU or commonly develop while the patient is in the ICU for the treatment of other conditions. The main risk factors for bacterial infections following HSCT are neutropenia, mucositis or skin breakdown, gastrointestinal problems associated with acute GVHD, and intravenous catheters (84). Severe bacterial infections in the ICU usually present as pneumonia, bacteremia, or septic shock. Surveillance blood cultures may be necessary to detect occult blood stream bacterial infections in HSCT recipients, especially those who are receiving systemic corticosteroids (85). Gram-negative pathogens such as *Pseudomonas* and *Klebsiella* should be given important consideration during the neutropenic phase. However, Gram-positive organisms such as methicillin-resistant *Staphylococcus aureus*, *Streptococcus viridans*, and enterococci are being increasingly identified as the main cause of severe bacterial infections following HSCT (86, 87). The increased prevalence of Gram-positive infections is probably related to shortened neutropenic phase, prophylactic agents such as quinolones, invasive procedures and catheterizations, and selective decontamination of the gastrointestinal tract that selectively protect against Gram-negative bacterial infections.

Viral Infections. Viral infections are common following HSCT and may occasionally result in critical illness. These viruses include CMV, herpes zoster virus, respiratory syncytial virus, human herpes simplex virus 6, and adenovirus (88, 89). The most serious complication of these viral infections is pneumonitis with acute respiratory failure; however, they may lead to other organ dysfunctions such as hepatitis, encephalitis, and bone marrow suppression (90). CMV is the most important viral infection following HSCT, and pneumonitis is the most severe manifestation of this infection. The patients at highest risk for CMV infection are those CMV-seronegative recipients receiving

hematopoietic stem cells from seropositive donors. Other risk factors include older age, transplantation for hematologic malignancy, total body irradiation, antithymocyte globulins, neutropenia, GVHD, and CMV seroconversion (89, 91–93). Before routine prophylaxis, the prevalence of CMV disease was 20–35%, with mortality reaching 100% (94, 95). Recently, the prevalence of CMV disease decreased significantly because of two important interventions. The first is routine prophylaxis against CMV using ganciclovir in high-risk patients in the first 100 days following HSCT (95). The second is preemptive treatment of patients with subclinical viremia detected by surveillance pp65 antigenemia or polymerase chain reaction assay (94, 96–98). Currently, CMV pneumonia in the first 100 days occurs in 6% of patients; however, the prevalence beyond the first 100 days increased from 4% to 15%, with the highest risk for late CMV pneumonia being the presence of chronic GVHD (89). CMV pneumonia usually presents a median of 7 wks after transplantation, with nonproductive cough, dyspnea, fever, and hypoxemia that quickly progresses to acute respiratory failure (89). High-resolution computerized tomography of the chest is the best diagnostic radiologic study and usually shows diffuse interstitial nodules and ground glass infiltrates (99). The diagnosis is established by demonstrating viral inclusion bodies in lung tissue biopsy (91). Other studies that are suggestive of CMV pneumonia are positive CMV culture and positive direct fluorescence assay or polymerase chain reaction on BAL fluid (91). Serum pp65 antigen assay is routinely available, and the test may be the first indication of CMV pneumonia (97). Treatment of CMV pneumonia using ganciclovir and immunoglobulins, especially when started early in the course of the illness, resulted in significant improvement in survival. Uncontrolled trials show survival rates of 50–70% compared with the historical 0–15% (53, 100, 101). However, it is important to note that ganciclovir treatment is associated with significant side effects, including neutropenia, nephrotoxicity, seizures, and retinal detachment. Foscarnet is an alternative that may also lead to acute renal failure. Respiratory syncytial virus pneumonia is another severe viral infection following HSCT. It usually develops in the first month following transplantation and has seasonal variation. The infection presents

with upper respiratory tract symptoms that progress to lower respiratory symptoms. The diagnosis is made by detecting the virus by nasal wash or BAL fluid culture (102). Once pneumonia develops, mortality is very high and approaches 80% (102, 103). Uncontrolled trials suggest that the combination of aerosolized ribavirin and intravenous immunoglobulins decrease mortality, especially if started before the onset of acute respiratory failure (104, 105). Herpes zoster virus infection following HSCT is rare but may lead to a disseminated disease with pneumonia, hepatitis, skin rash, encephalitis, and disseminated intravascular coagulation (106, 107). High-dose acyclovir is the treatment of choice (108). Human herpes simplex virus 6 is another severe viral infection following HSCT and may cause pneumonitis, marrow suppression, and encephalitis. Treatment is by ganciclovir or foscarnet (89, 91).

Fungal Infections. Fungal infections are increasingly identified in critically ill HSCT recipients. *Candida* species is the most commonly isolated fungal infection in this patient population. The prevalence of invasive candidal infection is estimated to be 1.3–10%, with mortality reaching 50% (109–112). Routine prophylaxis against *Candida* using fluconazole during the neutropenic phase has significantly decreased the prevalence of severe *Candida* infection in HSCT recipients (112). Candidemia is the most common serious manifestation of this infection; however, other internal organs may be affected, including hepatic and splenic infections (110). Primary candidal pneumonia is extremely rare. The main risk factors for serious candidal infections in HSCT recipients are advanced age, unmatched donor, neutropenia, acute GVHD, underlying disease, corticosteroid therapy, and duration of candidemia (112–114). Other risk factors for candidal infections are related to critical illness, including immunosuppressive therapy, neutropenia, multiple broad-spectrum antibiotics, total parenteral nutrition, and indwelling catheters. *Candida albicans* is the main species isolated; however, more resistant species are being increasingly isolated, including *Candida glabrata*, *Candida krusei*, and *Candida parapsilosis* (115). The treatment of candidemia and deep infection is primarily fluconazole; however, if there is evidence of endophthalmitis or resistant organisms, then caspofungin is the treatment of choice (116). Lipid for-

mulation amphotericin B is another effective agent (117).

Aspergillus is a leading cause of severe fungal infection following HSCT. The prevalence of IPA has been rising and currently ranges between 2% and 26% (118–122). The mortality rate of IPA is very high (74–92%) (62, 120, 123). Early diagnosis and effective antifungal therapy has resulted in a decrease in the mortality associated with the infection (124). The onset of IPA has a bimodal distribution, with an early peak during the neutropenic phase and a late phase during the treatment of chronic GVHD (125). The prevalence of IPA during the first peak is declining due to improvement in transplantation techniques and the use of granulocyte colony-stimulating factor that shorten the duration of neutropenia (122). On the other hand, the prevalence in the second phase is rising with more aggressive therapy for chronic GVHD (120, 122). The lung is the primary site of *Aspergillus* infection, leading to severe pneumonia with vascular invasion, necrosis, and hemorrhage. IPA disseminates to other organs, especially the brain, kidney, liver, and skin. In the lungs, the presentation is nonspecific, and fever may be absent. Pleuritic chest pain and hemoptysis, though nonspecific, should alert physicians to the possibility of IPA. Radiologically, IPA findings are nonspecific, including single or multiple nodules that may cavitate or focal or diffuse infiltrates (99). High-resolution computerized tomography of the chest should be performed early in the evaluation of patients suspected of having IPA. The routine early use of high-resolution computerized tomography in these patients has been shown to lead to earlier diagnosis and improved outcome (124). Two radiologic signs that are highly suggestive, but not pathognomonic, of IPA on high-resolution computerized tomography of the chest are the Halo sign and air-crescent sign. These signs are demonstrated in 33–60% of patients with proven IPA (99). Sputum cultures and BAL are positive in 45–62% of patients with IPA (126). Isolation of *Aspergillus* species from sputum or BAL fluid has a high predictive value of 82% for IPA in this patient population (127), although these tests are negative in 70% of patients with proven IPA (128). Consequently, a positive sputum or BAL for *Aspergillus* should warrant therapy in the appropriate clinical and radiologic circumstances, whereas a negative study does not rule

out IPA, and either further studies or empirical therapy should be considered. Surgical lung biopsy, either by video assisted thoracoscopy or thoracotomy, is the best diagnostic study available to confirm the diagnosis of IPA and is relatively well tolerated. Recent studies, which included HSCT recipients, showed that IPA is the most common diagnosis obtained by surgical lung biopsy and that the complications rate is <13% (129). Noninvasive methods to diagnose IPA have been recently introduced. These methods detect galactomannan, which is a component of the *Aspergillus* cell membrane, by either enzyme-linked immunosorbent assay or polymerase chain reaction from serum or BAL fluid. The serum enzyme-linked immunosorbent assay for galactomannan is clinically available and has sensitivity of 98%; however, the specificity is <90% (122, 130, 131). Studies indicate that a positive test may precede the radiologic features of IPA in 68% of patients and a definite diagnosis of IPA by 17 days (132–134). However, given the low specificity of the test, the manufacturers of the assay recommend more than one positive sample to indicate a true positive test (110). Further studies are necessary to define the role of galactomannan antigen in the diagnosis of IPA. Therapy of IPA has been difficult, with low response rate and significant side effects. Recent advances in antifungal therapy introduced several new agents that are highly effective and well tolerated. Currently, the treatment of choice for patients with IPA is voriconazole, and in the case of breakthrough therapy, caspofungin is an alternative (133, 135). The partial and complete response rate using these agents reaches 53% (135). Another effective agent is lipid formulation amphotericin B (117). In the case of voriconazole, it is essential to monitor liver function tests and the many drug interactions that may occur. The use of combination therapy in the management of severe, refractory IPA is currently under evaluation. Surgical treatment has a limited role in the management of patients with IPA and should only be considered in localized disease not responding to medical therapy or in cases of massive hemoptysis (136, 137). There is no effective prophylactic therapy against IPA. Measures that decrease the risk of IPA in HSCT recipients include the use of HEPA filters, laminar air flow systems, and avoidance of admission to areas of the hospital where there is construction

(138). Several antifungal agents have been considered for prophylaxis; however, there are no studies that show consistent effectiveness.

P. carinii Pneumonia. *P. carinii* pneumonia (PCP) is rarely seen following HSCT due to the effective prophylaxis using trimethoprim-sulfamethoxazole (139). Currently, the prevalence of PCP in HSCT recipients is negligible (140). However, in 5% of patients, trimethoprim-sulfamethoxazole is not well tolerated, and PCP should be considered in HSCT patients presenting with severe pneumonia who are not receiving this treatment or who are receiving other less effective prophylactic agents (141). The main risk factors for PCP in this patient population are treatment with corticosteroids or immunosuppressive therapy. The clinical presentation of PCP in HSCT recipients is more severe and fulminant than in human immunodeficiency virus patients; however, response to therapy is good if instituted early. BAL is the procedure of choice for the diagnosis of PCP, with positive yield in >90% of cases (142).

Cardiac Complications

Cardiac complications following HSCT are reported to vary from 2% to 28% and are the cause of transfer to the ICU in 19% of patients (6, 143–145). The main cardiac complications seen in this patient population are congestive heart failure, pericardial effusion, and arrhythmias.

Congestive Heart Failure. Congestive heart failure leading to pulmonary edema is the main cardiac complication following HSCT that is encountered in the ICU setting. The presence of preexisting cardiac dysfunction, even if subclinical, is a significant risk factor for congestive heart failure following HSCT. Ejection fraction before transplantation that is <50% has been correlated with increased risk for cardiogenic pulmonary edema following HSCT (146, 147). Other factors that lead to congestive heart failure posttransplantation include fluid overload associated with the infusion of chemotherapy, the presence of acute renal failure, veno-occlusive disease, severe sepsis, and anemia. High-dose chemotherapy used in the preparation for HSCT, such as cyclophosphamide, cytosine arabinoside, paclitaxel, etoposide, and cisplatin, may be associated with significant cardiac toxicity and congestive heart failure (144, 148). Another potential cause of acute cardiac toxicity following HSCT is the

infusion of dimethyl sulfoxide, cryopreserved marrow that may lead to congestive heart failure, bradyarrhythmias, or even cardiac arrest (149). One study suggested that a pretransplantation electrocardiogram showing QTc-interval prolongation was predictive of acute heart failure following HSCT (147). There is no convincing evidence that total body irradiation increases the prevalence of cardiac toxicity following HSCT (150). In the case of cyclophosphamide, the cardiac toxicity is dose dependent—cardiac complications are rare for doses of <120 mg/kg (151). The cardiac complications develop 5–16 days after infusion, with depressed left ventricular function, diastolic dysfunction, electrocardiographic changes, and pericardial effusion (151, 152). Histologic evidence suggests that the cardiac toxicity due to high-dose cyclophosphamide is through direct toxicity of the agent to the endothelial cells of the coronary vessels leading to myocardial necrosis (153). Although most of the cardiac changes are reversible, mortality due to cardiac toxicity associated with high-dose cyclophosphamide following HSCT is <2% (145, 154, 155). The management of congestive heart failure following HSCT is similar to that of other patients; however, the main challenge is to differentiate between cardiogenic pulmonary edema and other causes of pulmonary edema that may have a similar presentation or may co-exist with congestive heart failure. Electrocardiography and echocardiography are usually helpful diagnostic tests; however, right heart catheterization may also be necessary. Fluid restriction, diuresis, and angiotensin converting enzyme inhibitors are the mainstay of treatment. Correction of electrolyte disturbances and hypoxemia is helpful. Inotropic agents, such as dobutamine, are sometime necessary.

Pericardial Effusion. Pericardial effusion following HSCT is rare and is usually related to cyclophosphamide toxicity, viral syndrome, chronic GVHD, or renal failure (156). Rarely may it be due to bacterial infection (157) (mainly *S. aureus*) or aspergillosis (158, 159). Echocardiography is the best study to diagnose and evaluate the clinical significance of pericardial effusion. When the pericardial effusion is associated with hemodynamic compromise, it should be drained by subxiphoid pericardiectomy that allows direct visualization, hemostasis, and obtaining a biopsy. In emergency situations, percutaneous pericardiocentesis could be done;

however, it may be associated with bleeding complications, especially in the presence of thrombocytopenia.

Endocarditis. Endocarditis is infrequently reported following HSCT. In the largest review of endocarditis in HSCT recipients, the prevalence was 1.3% (157). The clinical presentation of endocarditis following HSCT could be subtle, and only 25% of the cases are diagnosed *ante mortem* (157). The main risk factors for endocarditis were indwelling central venous catheters, disruption of skin and mucosal barriers by high-dose chemotherapy and GVHD, and the administration of immunosuppressive therapy (157). Left-sided cardiac valves, especially mitral valve, are most commonly involved by endocarditis. The usual organisms isolated are Gram-positive bacteria, including *S. aureus* and *S. viridans*; however, there is a high prevalence of fungal endocarditis, including *Aspergillus* and *Candida* species (157, 160, 161). In one third of patients, no organisms are isolated, consistent with the diagnosis of nonbacterial thrombotic endocarditis (162, 163). The presence of endocarditis in HSCT recipients is associated with very high mortality, despite aggressive antimicrobial therapy (157). However, this increased mortality is usually related to co-morbid illnesses rather than the endocarditis itself.

Cardiac Arrhythmias. Cardiac arrhythmias are occasionally seen in critically ill HSCT recipients. They are most commonly associated with electrolyte abnormalities, hypoxemia, sepsis, MOSF, and use of vasopressor agents. Bradyarrhythmias have been described with infusion of hematopoietic stem cells cryopreserved with dimethyl sulfoxide (149). Supraventricular tachyarrhythmias are reported in 4.1% of HSCT recipients and are more frequent following autologous transplantation (164). The main risk factors for these arrhythmias are older age, underlying diagnosis of non-Hodgkins lymphoma, and the presence of preexisting cardiac condition (144, 164, 165). The most common supraventricular arrhythmias are atrial fibrillation or flutter. These types of arrhythmias commonly develop in the first month following transplantation (median, 6 days) and usually convert to sinus rhythm within 3 days of their onset (164). The presence of supraventricular tachyarrhythmias following HSCT is associated with prolonged hospitalization and increased mortality (164). The management of ar-

rhythmias in HSCT recipients is similar to any other patient population. Special attention should be given to correcting the factors that may trigger or exacerbate the arrhythmias. Amiodarone and diltiazem are the most commonly used medications to control supraventricular tachyarrhythmias. Cardioversion may be necessary in hemodynamically unstable patients.

Gastrointestinal Complications

Gastrointestinal (GI) problems are common following HSCT. They are frequently encountered in patients during their ICU stay. Severe GI complications present themselves as abdominal pain, diarrhea, or GI bleeding. In addition to the common causes of acute abdominal pain in critically ill patients such as peptic ulcer disease, pancreatitis, and acute cholecystitis, other conditions that are unique to HSCT recipients should be considered, including chemotherapy-related abdominal pain, GVHD of the intestines, intestinal pseudoobstruction, intestinal perforation, intestinal infections, and hemorrhagic enteritis. It is essential that clinicians taking care of HSCT recipients are aware of the above conditions that may lead to abdominal pain so that they can manage them appropriately and avoid unnecessary surgical interventions that are associated with significant mortality and morbidity.

GHVD of the Intestine. GHVD of the intestine is associated with abdominal pain, nausea, vomiting, diarrhea, and bleeding. The abdominal pain may be associated with peritoneal signs (166–168). Commonly, there are other manifestations of acute GVHD such as hepatitis and skin rash. A computerized tomographic scan of the abdomen will show bowel wall edema. Endoscopic biopsy is diagnostic; however, it is rarely necessary unless there are no other features of the disease. GVHD of the intestine usually responds well to intensification of the immunosuppressive therapy (166, 168).

Intestinal Pseudoobstruction. Intestinal pseudoobstruction is a common cause of abdominal pain following HSCT and is frequently seen during the course of these patients in the ICU. Pathogenesis include GVHD, sepsis, narcotics, electrolyte disturbances, and chemotherapeutic agents. Treatment is supportive and is directed toward treating the underlying cause. Neostigmine may be useful in the treatment of those patients with

persistent pseudoobstruction (169, 170). Intestinal perforation, on the other hand, is rarely encountered in these patients. The main causes of intestinal perforation following HSCT are CMV ulcers, corticosteroids therapy, and GVHD (166). The management of this condition is similar to that of nontransplant patients.

Acute Pancreatitis. Acute pancreatitis is reported to occur in 20% of HSCT recipients at autopsy (171); however, clinically significant disease is rare, and the prevalence is 3.5% (171). The main causes of acute pancreatitis following HSCT are medication use (trimethoprim-sulfamethoxazole, corticosteroids, cyclosporine A), infections (CMV and adenovirus), GVHD, and biliary sludge (171–173). The management of severe pancreatitis is supportive and treating the underlying problem.

Enteritis. Enteritis is another significant GI problem following HSCT, with reported prevalence of 43% after allogeneic HSCT (174–176). It is usually mild and self-limiting; however, in a small percentage of patients, it may be severe, leading to dehydration, with hypotension and acute renal failure. The main causes of enteritis following HSCT are GVHD, bacterial infection, the most common of which is *Clostridia difficile* enteritis, and viral infections such as rotavirus, adenovirus, CMV, herpes simplex virus, and herpes zoster virus (174, 177, 178). Typhilitis is a rare but severe clostridial infection that involves the cecum and ascending colon. It is mainly seen during the neutropenic phase following HSCT (177). The management of severe enteritis following HSCT includes supportive measures and treatment of the underlying pathogenesis. In the case of severe diarrhea, patients may respond to octreotide, a somatostatin analog, which inhibits the secretory hormones (179). Anti-diarrhea agents should be avoided because they may precipitate pseudoobstruction. Enteritis due to rotavirus responds to oral immunoglobulins (180). Prognosis of enteritis following HSCT is generally favorable (174).

Gastrointestinal Bleeding. GI bleeding following HSCT has been reported in 7–18% of those patients (181–183). A unique feature of GI bleeding in this patient population is that it tends to be diffuse mucosal bleeding that may involve the small intestine. It is also worsened by thrombocytopenia. The most common cause of GI bleeding in allogeneic HSCT recipients is GVHD (up to

60%) (37). Other common causes of severe GI bleeding include mucosal injury due to chemoradiotherapy, viral infections such as adenovirus, and CMV that lead to deep mucosal ulcers and necrosis, which may be associated with severe bleeding. Peptic ulcer disease is a rare cause of upper GI bleeding early post HSCT (6–10% of all cases) (37). GI bleeding is an indicator of poor outcome in critically ill HSCT recipients, although it is rarely the cause of death (18, 181). Management of severe GI bleeding following HSCT is similar to that in other patient populations. However, endoscopic procedures are of limited value in cases of diffuse mucosal bleeding. Surgery should be restricted to those with focal bleeding sites that do not respond to transfusion of blood products and endoscopic procedures (184). The outcome of patients who undergo surgical intervention for GI bleeding is generally poor (178). Effective preventive measures against GI bleeding include the routine use of antiemetic agents, H₂ blockers or proton pump inhibitors, adequate platelets transfusion, and control of GVHD.

Hepatic Complications

Liver failure is another significant problem in critically ill HSCT recipients and is usually related to sepsis and MOSF. However, other conditions may lead to severe liver disease following HSCT, including veno-occlusive disease, acute GVHD, viral hepatitis, and medications.

Veno-occlusive Disease. Veno-occlusive disease (VOD) is reported in 20–50% of patients following HSCT (185–188). VOD arises from thrombosis of small central hepatic venules due to endothelial cell damage by high-dose chemotherapy. VOD usually develops in the first 21 days following HSCT, and the earliest signs of the syndrome are weight gain and tender hepatomegaly, followed by jaundice. A decrease in bilirubin level is an early indicator of recovery (187, 189). Protein C and antithrombin III are reduced in patients with moderate to severe VOD and usually decrease before the clinical onset of VOD (190). The clinical course of VOD varies from mild, self-limiting liver dysfunction to a rapidly fatal disease associated with MOSF, including acute renal failure and acute respiratory failure requiring mechanical ventilation (187). The acute respiratory failure is commonly due to fluid overload or aspiration. The main risk factors for VOD are patient

age, elevation of transaminases before HSCT, the intensity of conditioning regimen, and prolonged fever (187). VOD frequency is similar in autologous compared with allogeneic HSCT (185, 187). The diagnosis of VOD is based on the clinical picture (the onset of hyperbilirubinemia, hepatomegaly, and weight gain or ascites in the first 30 days following HSCT). Doppler ultrasound of the hepatic blood vessels shows reversal or diminished portal blood flow (189). Percutaneous liver biopsy carries a high risk of bleeding. Hepatic vein catheterization with measurement of the hepatic venous pressure gradient (>10 mm Hg) and transvenous liver biopsy confirms the diagnosis of VOD but is rarely performed in clinical practice (191, 192). The management of VOD is supportive and is directed toward sodium and fluid restriction, diuresis, paracentesis in cases of tense ascites, and avoiding infection and hepatotoxic medications. Thrombolytic treatment is associated with a 30% response rate, but case fatality approaches 10% (193). Heparin and antithrombin III have been used with variable results (194). Oral ursodeoxycholic acid (urso-diol) is useful in lowering bilirubin levels and may prevent further hepatic injury caused by free radicals generated by bile acids (195, 196). VOD is fatal in 25–50% of patients (186–188, 196).

Other causes of liver dysfunction following HSCT include acute GVHD, although fulminant liver failure is rare (189). Viral hepatitis due to adenovirus, herpes simplex virus, and herpes zoster virus may lead to severe hepatitis with a rapid increase in liver enzymes (167, 197). Acyclovir is effective in the treatment of these infections. CMV infection commonly leads to hepatitis, although rarely severe. Hepatitis B and C may progress, leading to liver failure when immunosuppressive therapy for GVHD is tapered (198, 199). Fungal infection involving the liver is rare and is usually part of a multiple system infection. The most common fungal species that involve the liver are *Candida* and *Aspergillus* (200). Many medications used following HSCT contribute to liver disease, although they are rarely the cause of severe liver disease. These medications include cyclosporine A, fluconazole, voriconazole, antithymocyte globulins, interleukin-2, and total parenteral nutrition. Avoiding hepatotoxic drugs, monitoring drug levels, and adjusting doses are essential to the

proper management of HSCT recipients, especially if they have liver disease.

Renal Complications

Acute renal failure is a common and serious problem complicating HSCT. The reported prevalence of acute renal failure following HSCT varies between 9% and 53% (201–204). The presence of acute renal failure significantly affects the mortality of HSCT recipients (204, 205). Between 5% and 33% of these patients require renal replacement therapy (201, 206, 207). Mortality in those requiring hemodialysis is high, with ranges between 84% and 100% (6, 205, 206).

Acute renal failure following HSCT most commonly develops in the setting of MOSF secondary to sepsis or other causes (which could happen anytime following transplantation) (201, 202). There are, however, specific pathogeneses of acute renal failure that are unique to HSCT. These conditions tend to occur in a predictable timeline (Fig. 1). Acute renal failure in the first week following HSCT is generally related to tumor lysis syndrome or infusion of marrow cells. In the first month following transplantation, acute renal failure is commonly associated with VOD. Acute renal failure after the first month of transplantation may be related to hemolytic uremic syndrome, hemorrhagic cystitis, or cyclosporine A toxicity.

Tumor Lysis Syndrome. Tumor lysis syndrome is due to the breakdown of tumor cells following radiochemotherapy. The syndrome is rarely seen following HSCT because the underlying malignancy is usually in remission or partial relapse at the time of transplantation, so the burden of tumor cells is rarely high. In addition, patients routinely receive effective prophylaxis against this syndrome. When tumor lysis syndrome develops, it usually occurs in the first few days following chemotherapy and is characterized by hyperuricemia, hyperkalemia, hyperphosphatemia, hypocalcemia, and oliguric renal failure. This syndrome is usually reversible by adequate intravenous hydration and alkalinization of the urine. Allopurinol, hydration, alkalinization of urine, and oral phosphate binding antacids 1–2 days before chemotherapy are effective in preventing this syndrome.

Infusion of Stem Cells. Infusion of stem cells may result in acute renal failure due to hemolysis, which leads to hemoglobinuria and proximal acute tubular necrosis. The infusion of hematopoietic

stem cells cryopreserved with dimethyl sulfoxide probably contributes to intravascular hemolysis (149, 208). Factors that increase the risk of acute renal failure in this situation are hypovolemia and acidosis (208). Adequate hydration and alkalinization of the urine with adequate urine output protects against this complication.

Hemorrhagic Cystitis. Hemorrhagic cystitis is another cause of acute renal failure in the first 2 wks following HSCT and results in obstructive uropathy due to blood clots that obstruct the ureters or urethra. Hemorrhagic cystitis develops in 25% of allogeneic HSCT recipients (209). The condition is precipitated by cyclophosphamide metabolites, busulfan, or irradiation. Hemorrhagic cystitis may also develop later (median, 40–80 days) following HSCT secondary to BK virus, adenovirus, or CMV infections (210–214). Hemorrhagic cystitis is prevented by intravenous hydration, diuresis, irrigation of the urinary bladder, and the use of mesna.

Veno-occlusive Disease. VOD is the most common cause of acute renal failure in the first 10–21 days following HSCT (203). VOD is associated with a hepatorenal syndrome characterized by sodium retention, weight gain, and edema and ascites. This is followed by azotemia. The renal impairment in this syndrome is due to renal vasoconstriction secondary to a variety of mediators released by the damaged hepatic endothelial cells. These mediators include endothelin, thromboxane A₂, leukotrienes, platelet activating factor, and adenosine (186, 215). The main risk factors for acute renal failure in patients with VOD are mismatched graft, age of >25 yrs, high baseline creatinine, sepsis, and the use of amphotericin B (186, 187, 215, 216). Fifty percent of patients require renal replacement therapy, which is associated with poor prognosis (207, 217). The degree of hyperbilirubinemia is a predictor for the need for hemodialysis. Pentoxifylline (tumor necrosis factor- α antagonist) has been used to prevent acute renal failure in patients with VOD; however, subsequent trials failed to show benefit from this treatment (218).

Drug Nephrotoxicity. Drug nephrotoxicity is an important cause of acute renal failure and should be considered anytime following HSCT. Cyclosporine A causes intense afferent arteriolar vasoconstriction and nephrotoxicity, which is associated with hyperkalemia, metabolic

acidosis, hyperuricemia, and hypomagnesemia (219). Other drugs that lead to acute renal failure following HSCT include cytotoxic agents such as nitrosurea, methotrexate, and cyclophosphamide; antibiotics such as amphotericin B, acyclovir, foscarnet, and aminoglycosides; and immunosuppressive agents such as tacrolimus (219). The combination of any of the above agents significantly increases the risk of acute renal failure. Preventing acute renal failure due to drugs involves minimizing the use of these agents, careful monitoring of drug levels, and maintaining adequate hydration and electrolytes balance.

Electrolytes Abnormalities. Electrolytes abnormalities are common following HSCT. These include hyponatremia, hypokalemia, and hypomagnesemia, and are related to intravenous fluids, diarrhea, total parenteral nutrition, renal insufficiency, and drugs such as diuretics, cyclophosphamide, amphotericin B, and cyclosporine A. Severe hyponatremia (serum Na, <125mEq/L) is reported in 19% of HSCT recipients a median of 19 days following transplantation (220). The most common causes of severe hyponatremia are syndrome of inappropriate antidiuretic hormone, infections, diarrhea, GVHD, VOD, acute renal failure, and the effect of medications and intravenous fluids (220).

Neurologic Complications

The prevalence of clinically significant neurologic problems following HSCT is estimated to range between 11% and 18%, and these are generally more common following allogeneic transplantation (221, 222). Based on an autopsy study, neurologic complications were the cause of death in 17% of HSCT recipients (223). The risk factors for neurologic complications are high-dose chemotherapy, immunosuppressive therapy, GVHD, and thrombocytopenia (221–225). Neurologic complications of HSCT are important causes of critical illness in this patient population, and they account for 6% of all admissions or transfers to the ICU (6).

Cerebrovascular Accident. Cerebrovascular accident (CVA) develops in approximately 3% of HSCT recipients and is slightly more common following allogeneic HSCT (5% vs. 1.2% in autologous HSCT) (225). CVA develops a median of 28 days following HSCT (225). The main causes of CVA are, in order, intracranial bleeding (predominately intracerebral

and subarachnoid hemorrhage secondary to thrombocytopenia), cerebral infarction related to infection (predominantly due to aspergillosis), and noninfectious infarction due to thrombosis (225). Nonbacterial thrombotic endocarditis is a rare cause of cerebral infarction seen in HSCT that is related to disseminated intravascular coagulation or hypercoagulable state (226). The development of CVA is associated with poor outcome, and in a large study of CVA after HSCT the hospital mortality was 69.4% (225). Age, oncologic diagnosis, type of HSCT, and time of CVA did not predict poor outcome. The management of CVA following HSCT is similar to that of nontransplantation patients. However, special attention should be made to correct thrombocytopenia and coagulopathy, and a careful evaluation should be made for an infectious pathogenesis. Surgical evaluation is necessary for prompt drainage of intracranial hematoma.

Central Nervous System Infections. Central nervous system infections account for 10% of neurologic complications following HSCT (221, 227). The causes and time patterns of these infections are similar to that of other organs (Fig. 1). The main causes of central nervous system infections are aspergillosis, which was found in 4.4% HSCT recipients who underwent *post mortem* examination (223). Central nervous system involvement by aspergillosis is usually part of disseminated disease, with other evidence of the infection (224). Prognosis of patients with central nervous system involvement is extremely poor (228). Other causes of central nervous system infection in this patient population are CMV, herpes zoster virus, toxoplasma, *Candida*, *Cryptococcus*, and bacterial meningitis (227, 229, 230).

Metabolic Encephalopathy. Metabolic encephalopathy is an important cause of neurologic symptoms in critically ill HSCT recipients. The prevalence of metabolic encephalopathy in HSCT recipients ranges between 3% and 13% and is more common following allogeneic transplantation (222, 223, 227). The condition usually develops in the first 2 months following transplantation and usually presents with change in mental status or seizures (221). Other patients may present with classic Wernicke encephalopathy, with altered mental status, ataxia, and ophthalmoplegia (231). The main causes of metabolic encephalopathy following HSCT are hypoxemia, electro-

lyte abnormalities, metabolic acidosis, sepsis, hepatic failure, and medications including sedatives and analgesics (223). Thiamine deficiency, secondary to malabsorption associated with acute GVHD, has been suggested as the cause of Wernicke encephalopathy (222, 231). Treatment of metabolic encephalopathy is supportive, including correction of electrolyte abnormalities and hypoxemia, withholding of offending medications, and treatment of the underlying problems.

Treatment-Related Neurologic Complications. Treatment-related neurologic complications might lead to serious neurologic side effects. Cyclosporine A may lead to encephalopathy, leukoencephalopathy, generalized cerebellar dysfunction, hemiparesis, quadriplegia, and seizures (232, 233). The risk of neurologic complications increases with history of cranial radiation, hypertension, uremia, hypomagnesemia, β -lactam antibiotics, and high-dose corticosteroids (224, 234). OKT3 treatment has been associated with aseptic meningitis that may develop 24–72 hrs after injection (235). Pretreatment with corticosteroids may reduce or prevent this syndrome (236). Antibiotics such as imipenem may be the cause of seizure activity. Corticosteroids are associated with myopathy, psychosis, and other problems resulting from withdrawal of this medication. Furthermore, the treatment of HSCT recipients in the ICU may lead to further neurologic complications, including critical care polyneuropathy and myopathy and prolonged effects of neuromuscular blocking agents and sedatives.

Acute GVHD. Acute GVHD is not specifically associated with neurologic complications, except for encephalopathy associated with other organ dysfunction. In contrast, chronic GVHD may be associated with polyneuropathy, polymyositis, and myasthenia gravis (232, 237, 238). Most of these syndromes respond to intensifying immunosuppressive therapy (239).

Hematologic Complications

HSCT is associated with several hematologic problems related to pancytopenia that lead to severe complications, including bleeding and infection. In this segment, we will concentrate on a specific complication related to HSCT, which is thrombotic thrombocytopenic purpura.

Thrombotic Thrombocytopenic Purpura. Thrombotic thrombocytopenic purpura

(TTP) is one of the most severe hematologic complications related to HSCT. It is more commonly identified in allogeneic HSCT recipients (prevalence, 5–15% (240–243)); however, TTP is also seen after autologous HSCT. The median time of onset of TTP is 44 days following HSCT (244). The pentad of classic TTP is thrombocytopenia, microangiopathic hemolytic anemia, fever, neurologic signs, and renal impairment. Hemolytic uremic syndrome, which has also been described following HSCT, is similar to TTP but differs in the severity of renal impairment. The main risk factors for TTP following HSCT are older age, female sex, human leukocyte antigen mismatching, high-grade acute GVHD, cyclosporine treatment, and history of severe infection (240, 245, 246). The proposed mechanisms of TTP following HSCT include endothelial damage due to chemotherapy or cyclosporine that led to release of cytokines, such as tumor necrosis factor- α , that precipitate a prothrombotic state (247). It is important to note that deficiency of von Willebrand factor-cleaving protein, which is implicated in the pathogenesis of classic TTP, does not play a role in TTP following HSCT (248). There are other fundamental differences between TTP related to HSCT and idiopathic TTP. TTP following HSCT is sometimes difficult to diagnose because some of the diagnostic criteria are lacking (244). For example, neurologic and renal signs are absent in 36% and 54% of HSCT recipients with TTP (243). Furthermore, some of the diagnostic criteria may be part of other syndromes; for example, thrombocytopenia could be due to lack of engraftment, infection, or medications. Similarly, fever, neurologic problems, and renal problems are precipitated by many other conditions. So practically, the presence of thrombocytopenia and microangiopathic hemolytic anemia, without an alternative explanation, is sufficient to make the diagnosis of TTP following HSCT (243). The most important differential diagnosis of TTP following HSCT is cyclosporine toxicity, which may lead to microangiopathic hemolytic anemia, renal impairment, and neurologic complications. There are even some reports that cyclosporine is one of the causes of TTP following HSCT (245, 246). The management of TTP following HSCT includes discontinuing cyclosporine or tacrolimus and avoiding platelet transfusion. The role of plasma exchange, which is the mainstay of treatment in idiopathic

TTP, is not clear (249–251). Furthermore, the response to plasma exchange in cases of TTP following HSCT is not as good as that with idiopathic TTP (25% vs. 90%, respectively (252)). The prognosis of TTP following HSCT is generally poor, and the mortality rate is around 70% (241, 242, 246, 248). Mortality is higher if the syndrome develops in the first 120 days following HSCT, after treatment with cyclosporine or tacrolimus, or if there is neurologic deficit (243). The only predictor of resolution of TTP is the absence of renal impairment (244).

ICU Outcome

Admission of the HSCT recipient to the ICU carries a very high mortality. Early reports describe the mortality to be >90%, especially in those who require mechanical ventilation. During the past two decades, the prognosis for these patients has significantly improved (Table 2). More recent reports show that ICU and hospital mortality rates are <33% and <56%, respectively (6, 253). Long-term survival, although improving, remains poor.

The improvement in survival is multifactorial and is probably related to the use of hematopoietic stem cells rather than bone marrow, nonmyeloablative regimens, shorter neutropenic phase, better antimicrobial prophylaxis, preemptive therapy of CMV infection, and improved antifungal therapy. In addition, improved intensive care, including lung protective ventilation strategies and the early use of noninvasive ventilation in these immunocompromised patients, have probably significantly contributed to the better ICU outcome (254, 255). Furthermore, the multidisciplinary approach to the management of these patients, with a leading role played by intensivists, plays a significant role in the improved outcome of critically ill HSCT recipients.

Survival studies attempted to identify the variables that predict the outcome of critically ill HSCT recipients. A few studies have suggested that clinical characteristics before the admission to the ICU, such as age, type of HSCT, conditioning regimen, presence of neutropenia or GVHD, and time from transplantation to the admission to ICU, were important predictors of poor outcome. However, most of the studies have shown that these pre-ICU variables are not reliable and should not be used to determine suitability for transfer to the ICU. Furthermore,

most studies show that measures of severity of illness such as the Acute Physiology and Chronic Health Evaluation (APACHE) II and Simplified Acute Physiology Score II have failed to predict the outcome of HSCT patients admitted to the ICU and consistently underestimate mortality in this patient population (5, 6). It is important to mention, however, that a recent study suggested that APACHE III was a reasonable prognostic tool in predicting hospital mortality in critically ill HSCT recipients (253). Another recent study showed that high serum lactate level at admission to the ICU was a significant predictor of poor outcome (6). The outcome predictors that consistently predicted poor outcome of HSCT recipients admitted to the ICU were the need for mechanical ventilation and the presence of MOSF (Table 2). Acute respiratory failure requiring mechanical ventilation increased the odds of death in the ICU by 55.6 times (6). The presence of more than two organ system failures, regardless of the type of organ failure, significantly increased the mortality in this patient population (6). It is important to mention in this context that there are no absolute predictors of mortality. Only one study showed that all patients who had acute lung injury (Fio₂ of >0.6 or positive end-expiratory pressure of >5), hepatic and renal failure, and who required vasopressors for >4 hrs died (256).

In addition to the improvement in ICU outcome reflected by recent reports studying HSCT recipients, there are few observations that warrant mentioning. The survival rate of HSCT recipients admitted to the ICU is similar to that of other critically ill patient populations, such as patients with sepsis or acute respiratory distress syndrome, and survival is directly related to the number of MOSF. This suggests that the outcome of HSCT recipients admitted to the ICU is more dependent on the underlying critical illness rather than the fact that they are transplant recipients. Consequently, these patients should be managed aggressively in a manner similar to that of other patient groups. However, it should be kept in mind that HSCT recipients are prone to unique infectious and noninfectious complications that warrant special consideration. Another observation is that the knowledge about the poor ICU outcome of HSCT recipients and the predictors of outcome mentioned above do not seem to change physicians' attitudes toward admitting these patients to the

ICU and administering mechanical ventilation if necessary. The third observation is that long-term survival (>6 months) of HSCT recipients treated in the ICU remains poor; however, those who do achieve long-term survival (>6 months) tend to have normal organ function, and their prognosis is similar to that of those who did not require ICU admission (15).

In summary, HSCT is an important treatment for a wide variety of malignant and nonmalignant conditions. A significant number of patients who have had HSCT develop serious complications that involve almost any organ system and commonly lead to critical illness. Intensivists play a central role in the management of these critically ill patients. Although the mortality rate of critically ill HSCT recipients is high, survival is steadily improving. There are no definite predictors of survival in these patients; however, the presence of more than two organ system failures and the need for mechanical ventilation are especially associated with poor outcome. In general, critically ill HSCT recipients should be offered aggressive critical care therapy, including mechanical ventilation; however, these patients and their families should be counseled in advance about the outcome of such care.

REFERENCES

1. Loberiza F: IBMTR/ABMTR data management updates. *IBMTR/ABMTR Newslett* 2004; 10:6–11
2. Storb R, Yu C, Wagner JL, et al: Stable mixed hematopoietic chimerism in DLA-identical littermate dogs given sublethal total body irradiation before and pharmacological immunosuppression after marrow transplantation. *Blood* 1997; 89:3048–3054
3. McSweeney PA, Niederwieser D, Shizuru JA, et al: Hematopoietic cell transplantation in older patients with hematologic malignancies: Replacing high-dose cytotoxic therapy with graft-versus-tumor effects. *Blood* 2001; 97:3390–3400
4. Slavin S, Nagler A, Nappastek E, et al: Nonmyeloablative stem cell transplantation and cell therapy as an alternative to conventional bone marrow transplantation with lethal cytoreduction for the treatment of malignant and nonmalignant hematologic diseases. *Blood* 1998; 91:756–763
5. Afessa B, Tefferi A, Hoagland HC, et al: Outcome of recipients of bone marrow transplants who require intensive-care unit support. *Mayo Clin Proc* 1992; 67:117–122
6. Soubani AO, Kseibi E, Bander JJ, et al: Outcome and prognostic factors of hematopoietic stem cell transplantation recipients admitted to a medical ICU. *Chest* 2004; 126:1604–1611
7. Kress JP, Christenson J, Pohlman AS, et al: Outcomes of critically ill cancer patients in a university hospital setting. *Am J Respir Crit Care Med* 1999; 160:1957–1961
8. Ewig S, Torres A, Riquelme R, et al: Pulmonary complications in patients with haematological malignancies treated at a respiratory ICU. *Eur Respir J* 1998; 12:116–122
9. Crawford SW, Schwartz DA, Petersen FB, et al: Mechanical ventilation after marrow transplantation: Risk factors and clinical outcome. *Am Rev Respir Dis* 1988; 137:682–687
10. Torrecilla C, Cortes JL, Chamorro C, et al: Prognostic assessment of the acute complications of bone marrow transplantation requiring intensive therapy. *Intensive Care Med* 1988; 14:393–398
11. Denardo SJ, Oye RK, Bellamy PE: Efficacy of intensive care for bone marrow transplant patients with respiratory failure. *Crit Care Med* 1989; 17:4–6
12. Martin C, Maraninchi D, Saux P, et al: Need for mechanical ventilation in the treatment of acute infections complicating bone marrow transplantation. *Crit Care Med* 1990; 18:120–121
13. Dees A, Lighthart JL, van Putten WL, et al: Mechanical ventilation in cancer patients: Analysis of clinical data and outcome. *Neth J Med* 1990; 37:183–188
14. Crawford SW, Petersen FB: Long-term survival from respiratory failure after marrow transplantation for malignancy. *Am Rev Respir Dis* 1992; 145:510–514
15. Paz HL, Crilley P, Weinar M, et al: Outcome of patients requiring medical ICU admission following bone marrow transplantation. *Chest* 1993; 104:527–531
16. Faber-Langendoen K, Caplan AL, McGlave PB: Survival of adult bone marrow transplant patients receiving mechanical ventilation: A case for restricted use. *Bone Marrow Transplant* 1993; 12:501–507
17. Jackson SR, Tweeddale MG, Barnett MJ, et al: Admission of bone marrow transplant recipients to the intensive care unit: Outcome, survival and prognostic factors. *Bone Marrow Transplant* 1998; 21:697–704
18. Price KJ, Thall PF, Kish SK, et al: Prognostic indicators for blood and marrow transplant patients admitted to an intensive care unit. *Am J Respir Crit Care Med* 1998; 158:876–884
19. Shorr AF, Moores LK, Edenfield WJ, et al: Mechanical ventilation in hematopoietic stem cell transplantation: Can we effectively predict outcomes? *Chest* 1999; 116:1012–1018
20. Huaranga AJ, Leyva FJ, Giralt SA, et al: Outcome of bone marrow transplantation patients requiring mechanical ventilation. *Crit Care Med* 2000; 28:1014–1017
21. Staudinger T, Stoiser B, Mullner M, et al: Outcome and prognostic factors in critically ill cancer patients admitted to the intensive

- care unit. *Crit Care Med* 2000; 28: 1322-1328
22. Khassawneh BY, White P Jr, Anaissie EJ, et al: Outcome from mechanical ventilation after autologous peripheral blood stem cell transplantation. *Chest* 2002; 121:185-188
 23. Scott PH, Morgan TJ, Durrant S, et al: Survival following mechanical ventilation of recipients of bone marrow transplants and peripheral blood stem cell transplants. *Anaesth Intensive Care* 2002; 30:289-294
 24. Spitzer TR: Engraftment syndrome following hematopoietic stem cell transplantation. *Bone Marrow Transplant* 2001; 27: 893-898
 25. Lee CK, Gingrich RD, Hohl RJ, et al: Engraftment syndrome in autologous bone marrow and peripheral stem cell transplantation. *Bone Marrow Transplant* 1995; 16: 175-182
 26. Ravoet C, Feremans W, Husson B, et al: Clinical evidence for an engraftment syndrome associated with early and steep neutrophil recovery after autologous blood stem cell transplantation. *Bone Marrow Transplant* 1996; 18:943-947
 27. Kawano C, Muroi K, Kuribara R, et al: Engraftment syndrome after autologous peripheral blood stem cell transplantation with high numbers of peripheral blood stem cells followed by granulocyte colony-stimulating factor administration. *Bone Marrow Transplant* 2000; 25:228-229
 28. Cahill RA, Spitzer TR, Mazumder A: Marrow engraftment and clinical manifestations of capillary leak syndrome. *Bone Marrow Transplant* 1996; 18:177-184
 29. Nurnberger W, Willers R, Burdach S, et al: Risk factors for capillary leakage syndrome after bone marrow transplantation. *Ann Hematol* 1997; 74:221-224
 30. Moreb JS, Kubilis PS, Mullins DL, et al: Increased frequency of autoaggression syndrome associated with autologous stem cell transplantation in breast cancer patients. *Bone Marrow Transplant* 1997; 19:101-106
 31. Azoulay E, Attalah H, Harf A, et al: Granulocyte colony-stimulating factor or neutrophil-induced pulmonary toxicity: Myth or reality? Systematic review of clinical case reports and experimental data. *Chest* 2001; 120:1695-1701
 32. Azoulay E, Attalah H, Yang K, et al: Exacerbation with granulocyte colony-stimulating factor of prior acute lung injury during neutropenia recovery in rats. *Crit Care Med* 2003; 31:157-165
 33. Karlin L, Darmon M, Thiery G, et al: Respiratory status deterioration during G-CSF-induced neutropenia recovery. *Bone Marrow Transplant* 2005; 36:245-250
 34. Metcalf JP, Rennard SI, Reed EC, et al: Corticosteroids as adjunctive therapy for diffuse alveolar hemorrhage associated with bone marrow transplantation: University of Nebraska Medical Center Bone Marrow Transplant Group. *Am J Med* 1994; 96: 327-334
 35. Lewis ID, DeFor T, Weisdorf DJ: Increasing incidence of diffuse alveolar hemorrhage following allogeneic bone marrow transplantation: Cryptic etiology and uncertain therapy. *Bone Marrow Transplant* 2000; 26: 539-543
 36. Ho VT, Weller E, Lee SJ, et al: Prognostic factors for early severe pulmonary complications after hematopoietic stem cell transplantation. *Biol Blood Marrow Transplant* 2001; 7:223-229
 37. Nevo S, Swan V, Enger C, et al: Acute bleeding after bone marrow transplantation (BMT)- incidence and effect on survival: A quantitative analysis in 1,402 patients. *Blood* 1998; 91:1469-1477
 38. Witte RJ, Gurney JW, Robbins RA, et al: Diffuse pulmonary alveolar hemorrhage after bone marrow transplantation: Radiographic findings in 39 patients. *AJR Am J Roentgenol* 1991; 157:461-464
 39. Afessa B, Tefferi A, Litzow MR, et al: Diffuse alveolar hemorrhage in hematopoietic stem cell transplant recipients. *Am J Respir Crit Care Med* 2002; 166:641-645
 40. Cordonnier C, Bernaudin JF, Bierling P, et al: Pulmonary complications occurring after allogeneic bone marrow transplantation: A study of 130 consecutive transplanted patients. *Cancer* 1986; 58:1047-1054
 41. Jules-Elysee K, Stover DE, Yahalom J, et al: Pulmonary complications in lymphoma patients treated with high-dose therapy autologous bone marrow transplantation. *Am Rev Respir Dis* 1992; 146:485-491
 42. Robbins RA, Linder J, Stahl MG, et al: Diffuse alveolar hemorrhage in autologous bone marrow transplant recipients. *Am J Med* 1989; 87:511-518
 43. Chao NJ, Duncan SR, Long GD, et al: Corticosteroid therapy for diffuse alveolar hemorrhage in autologous bone marrow transplant recipients. *Ann Intern Med* 1991; 114: 145-146
 44. Frankovich J, Donaldson SS, Lee Y, et al: High-dose therapy and autologous hematopoietic cell transplantation in children with primary refractory and relapsed Hodgkin's disease: Atopy predicts idiopathic diffuse lung injury syndromes. *Biol Blood Marrow Transplant* 2001; 7:49-57
 45. Mulder PO, Meinesz AF, de Vries EG, et al: Diffuse alveolar hemorrhage in autologous bone marrow transplant recipients. *Am J Med* 1991; 90:278-281
 46. Raptis A, Mavroudis D, Suffredini A, et al: High-dose corticosteroid therapy for diffuse alveolar hemorrhage in allogeneic bone marrow stem cell transplant recipients. *Bone Marrow Transplant* 1999; 24: 879-883
 47. Bojko T, Notterman DA, Greenwald BM, et al: Acute hypoxemic respiratory failure in children following bone marrow transplantation: an outcome and pathologic study. *Crit Care Med* 1995; 23:755-759
 48. Afessa B, Tefferi A, Litzow MR, et al: Outcome of diffuse alveolar hemorrhage in hematopoietic stem cell transplant recipients. *Am J Respir Crit Care Med* 2002; 166: 1364-1368
 49. Afessa B, Litzow MR, Tefferi A: Bronchiolitis obliterans and other late onset non-infectious pulmonary complications in hematopoietic stem cell transplantation. *Bone Marrow Transplant* 2001; 28:425-434
 50. Piguet PF, Grau GE, Collart MA, et al: Pneumopathies of the graft-versus-host reaction: Alveolitis associated with an increased level of tumor necrosis factor mRNA and chronic interstitial pneumonitis. *Lab Invest* 1989; 61:37-45
 51. Wojno KJ, Vogelsang GB, Beschoner WE, et al: Pulmonary hemorrhage as a cause of death in allogeneic bone marrow recipients with severe acute graft-versus-host disease. *Transplantation* 1994; 57:88-92
 52. Worthy SA, Flint JD, Muller NL: Pulmonary complications after bone marrow transplantation: High-resolution CT and pathologic findings. *Radiographics* 1997; 17:1359-1371
 53. Meyers JD, Flournoy N, Thomas ED: Nonbacterial pneumonia after allogeneic marrow transplantation: A review of ten years' experience. *Rev Infect Dis* 1982; 4:1119-1132
 54. Griese M, Rampf U, Hofmann D, et al: Pulmonary complications after bone marrow transplantation in children: Twenty-four years of experience in a single pediatric center. *Pediatr Pulmonol* 2000; 30:393-401
 55. Atkinson K, Nivison-Smith I, Dodds A, et al: A comparison of the pattern of interstitial pneumonitis following allogeneic bone marrow transplantation before and after the introduction of prophylactic ganciclovir therapy in 1989. *Bone Marrow Transplant* 1998; 21:691-695
 56. Cooke KR, Yanik G: Acute lung injury after allogeneic stem cell transplantation: Is the lung a target of acute graft-versus-host disease? *Bone Marrow Transplant* 2004; 34: 753-765
 57. Wingard JR, Mellits ED, Sostrin MB, et al: Interstitial pneumonitis after allogeneic bone marrow transplantation: Nine-year experience at a single institution. *Medicine (Baltimore)* 1988; 67:175-186
 58. Kantrow SP, Hackman RC, Boeckh M, et al: Idiopathic pneumonia syndrome: changing spectrum of lung injury after marrow transplantation. *Transplantation* 1997; 63:1079-1086
 59. Wingard JR, Sostrin MB, Vriesendorp HM, et al: Interstitial pneumonitis following autologous bone marrow transplantation. *Transplantation* 1988; 46:61-65
 60. Crawford SW, Hackman RC: Clinical course of idiopathic pneumonia after bone marrow transplantation. *Am Rev Respir Dis* 1993; 147:1393-1400
 61. Crawford SW, Longton G, Storb R: Acute graft-versus-host disease and the risks for idiopathic pneumonia after marrow transplantation for severe aplastic anemia. *Bone Marrow Transplant* 1993; 12:225-231

62. Fukuda T, Hackman RC, Guthrie KA, et al: Risks and outcomes of idiopathic pneumonia syndrome after nonmyeloablative and conventional conditioning regimens for allogeneic hematopoietic stem cell transplantation. *Blood* 2003; 102:2777-2785
63. Clark JG, Hansen JA, Hertz MI, et al: NHLBI workshop summary: Idiopathic pneumonia syndrome after bone marrow transplantation. *Am Rev Respir Dis* 1993; 147:1601-1606
64. Qureshi MA, Girgis RE, Dandapanula HK, et al: Increased exhaled nitric oxide following autologous peripheral hematopoietic stem-cell transplantation: A potential marker of idiopathic pneumonia syndrome. *Chest* 2004; 125:281-287
65. Panoskaltis-Mortari A, Taylor PA, Yaeger TM, et al: The critical early proinflammatory events associated with idiopathic pneumonia syndrome in irradiated murine allogeneic recipients are due to donor T cell infusion and potentiated by cyclophosphamide. *J Clin Invest* 1997; 100:1015-1027
66. Clark JG, Madtes DK, Hackman RC, et al: Lung injury induced by alloreactive Th1 cells is characterized by host-derived mononuclear cell inflammation and activation of alveolar macrophages. *J Immunol* 1998; 161:1913-1920
67. Clark JG, Madtes DK, Martin TR, et al: Idiopathic pneumonia after bone marrow transplantation: Cytokine activation and lipopolysaccharide amplification in the bronchoalveolar compartment. *Crit Care Med* 1999; 27:1800-1806
68. Shankar G, Cohen DA: Idiopathic pneumonia syndrome after bone marrow transplantation: The role of pre-transplant radiation conditioning and local cytokine dysregulation in promoting lung inflammation and fibrosis. *Int J Exp Pathol* 2001; 82:101-113
69. Lund MB, Kongerud J, Brinch L, et al: Decreased lung function in one year survivors of allogeneic bone marrow transplantation conditioned with high-dose busulphan and cyclophosphamide. *Eur Respir J* 1995; 8:1269-1274
70. Thirman MJ, Devine SM, O'Toole K, et al: Bronchiolitis obliterans organizing pneumonia as a complication of allogeneic bone marrow transplantation. *Bone Marrow Transplant* 1992; 10:307-311
71. Mathew P, Bozeman P, Krance RA, et al: Bronchiolitis obliterans organizing pneumonia (BOOP) in children after allogeneic bone marrow transplantation. *Bone Marrow Transplant* 1994; 13:221-223
72. Kanda Y, Takahashi T, Imai Y, et al: Bronchiolitis obliterans organizing pneumonia after syngeneic bone marrow transplantation for acute lymphoblastic leukemia. *Bone Marrow Transplant* 1997; 19:1251-1253
73. Ishii T, Manabe A, Ebihara Y, et al: Improvement in bronchiolitis obliterans organizing pneumonia in a child after allogeneic bone marrow transplantation by a combination of oral prednisolone and low dose erythromycin. *Bone Marrow Transplant* 2000; 26:907-910
74. Graham NJ, Muller NL, Miller RR, et al: Intrathoracic complications following allogeneic bone marrow transplantation: CT findings. *Radiology* 1991; 181:153-156
75. Cordier JF: Organising pneumonia. *Thorax* 2000; 55:318-328
76. Yoshihara S, Tateishi U, Ando T, et al: Lower incidence of Bronchiolitis obliterans in allogeneic hematopoietic stem cell transplantation with reduced-intensity conditioning compared with myeloablative conditioning. *Bone Marrow Transplant* 2005; 35:1195-1200
77. Chien JW, Martin PJ, Gooley TA, et al: Air-flow obstruction after myeloablative allogeneic hematopoietic stem cell transplantation. *Am J Respir Crit Care Med* 2003; 168:208-214
78. Paz HL, Crilly P, Topolsky DL, et al: Bronchiolitis obliterans after bone marrow transplantation: The effect of preconditioning. *Respiration* 1993; 60:109-114
79. Clark JG, Crawford SW, Madtes DK, et al: Obstructive lung disease after allogeneic marrow transplantation: Clinical presentation and course. *Ann Intern Med* 1989; 111:368-376
80. Philit F, Wiesendanger T, Archimbaud E, et al: Post-transplant obstructive lung disease ("bronchiolitis obliterans"): A clinical comparative study of bone marrow and lung transplant patients. *Eur Respir J* 1995; 8:551-558
81. Palmas A, Tefferi A, Myers JL, et al: Late-onset noninfectious pulmonary complications after allogeneic bone marrow transplantation. *Br J Haematol* 1998; 100:680-687
82. Kudoh S, Azuma A, Yamamoto M, et al: Improvement of survival in patients with diffuse panbronchiolitis treated with low-dose erythromycin. *Am J Respir Crit Care Med* 1998; 157:1829-1832
83. Gerhardt SG, McDyer JF, Girgis RE, et al: Maintenance azithromycin therapy for bronchiolitis obliterans syndrome: Results of a pilot study. *Am J Respir Crit Care Med* 2003; 168:121-125
84. Almyroudis NG, Fuller A, Jakubowski A, et al: Pre- and post-engraftment bloodstream infection rates and associated mortality in allogeneic hematopoietic stem cell transplant recipients. *Transpl Infect Dis* 2005; 7:11-17
85. Chizuka A, Kami M, Kanda Y, et al: Value of surveillance blood culture for early diagnosis of occult bacteremia in patients on corticosteroid therapy following allogeneic hematopoietic stem cell transplantation. *Bone Marrow Transplant* 2005; 35:577-582
86. Kapur D, Dorsky D, Feingold JM, et al: Incidence and outcome of vancomycin-resistant enterococcal bacteremia following autologous peripheral blood stem cell transplantation. *Bone Marrow Transplant* 2000; 25:147-152
87. Bilgrami S, Feingold JM, Dorsky D, et al: Streptococcus viridans bacteremia following autologous peripheral blood stem cell transplantation. *Bone Marrow Transplant* 1998; 21:591-595
88. Runde V, Ross S, Trenchel R, et al: Adenoviral infection after allogeneic stem cell transplantation (SCT): Report on 130 patients from a single SCT unit involved in a prospective multi center surveillance study. *Bone Marrow Transplant* 2001; 28:51-57
89. Nichols WG: Management of infectious complications in the hematopoietic stem cell transplant recipient. *J Intensive Care Med* 2003; 18:295-312
90. Boeckh M, Hoy C, Torok-Storb B: Occult cytomegalovirus infection of marrow stroma. *Clin Infect Dis* 1998; 26:209-210
91. Soubani AO, Miller KB, Hassoun PM: Pulmonary complications of bone marrow transplantation. *Chest* 1996; 109:1066-1077
92. Burns LJ, Miller W, Kandaswamy C, et al: Randomized clinical trial of ganciclovir vs acyclovir for prevention of cytomegalovirus antigenemia after allogeneic transplantation. *Bone Marrow Transplant* 2002; 30:945-951
93. Holmberg LA, Boeckh M, Hooper H, et al: Increased incidence of cytomegalovirus disease after autologous CD34-selected peripheral blood stem cell transplantation. *Blood* 1999; 94:4029-4035
94. Boeckh M: Current antiviral strategies for controlling cytomegalovirus in hematopoietic stem cell transplant recipients: Prevention and therapy. *Transpl Infect Dis* 1999; 1:165-178
95. Vij R, Khoury H, Brown R, et al: Low-dose short-course intravenous ganciclovir as pre-emptive therapy for CMV viremia post allo-PBSC transplantation. *Bone Marrow Transplant* 2003; 32:703-707
96. Boeckh M, Bowden RA, Gooley T, et al: Successful modification of a pp65 antigenemia-based early treatment strategy for prevention of cytomegalovirus disease in allogeneic marrow transplant recipients. *Blood* 1999; 93:1781-1782
97. Humar A, Lipton J, Welsh S, et al: A randomized trial comparing cytomegalovirus antigenemia assay vs screening bronchoscopy for the early detection and prevention of disease in allogeneic bone marrow and peripheral blood stem cell transplant recipients. *Bone Marrow Transplant* 2001; 28:485-490
98. Osarogiagbon RU, Defor TE, Weisdorf MA, et al: CMV antigenemia following bone marrow transplantation: Risk factors and outcomes. *Biol Blood Marrow Transplant* 2000; 6:280-288
99. Coy DL, Ormazabal A, Godwin JD, et al: Imaging evaluation of pulmonary and abdominal complications following hematopoietic stem cell transplantation. *Radiographics* 2005; 25:305-317
100. Ljungman P, Engelhard D, Link H, et al: Treatment of interstitial pneumonitis due

- to cytomegalovirus with ganciclovir and intravenous immune globulin: Experience of European Bone Marrow Transplant Group. *Clin Infect Dis* 1992; 14:831–835
101. Reed EC, Bowden RA, Dandliker PS, et al: Treatment of cytomegalovirus pneumonia with ganciclovir and intravenous cytomegalovirus immunoglobulin in patients with bone marrow transplants. *Ann Intern Med* 1988; 109:783–788
 102. Small TN, Casson A, Malak SF, et al: Respiratory syncytial virus infection following hematopoietic stem cell transplantation. *Bone Marrow Transplant* 2002; 29:321–327
 103. Harrington RD, Hooton TM, Hackman RC, et al: An outbreak of respiratory syncytial virus in a bone marrow transplant center. *J Infect Dis* 1992; 165:987–993
 104. Boeckh M, Berrey MM, Bowden RA, et al: Phase I evaluation of the respiratory syncytial virus-specific monoclonal antibody palivizumab in recipients of hematopoietic stem cell transplants. *J Infect Dis* 2001; 184:350–354
 105. DeVincenzo JP, Hirsch RL, Fuentes RJ, et al: Respiratory syncytial virus immune globulin treatment of lower respiratory tract infection in pediatric patients undergoing bone marrow transplantation: A compassionate use experience. *Bone Marrow Transplant* 2000; 25:161–165
 106. Morishita K, Kodo H, Asano S, et al: Fulminant varicella hepatitis following bone marrow transplantation. *JAMA* 1985; 253:511
 107. Verdonck LF, Cornelissen JJ, Dekker AW, et al: Acute abdominal pain as a presenting symptom of varicella-zoster virus infection in recipients of bone marrow transplants. *Clin Infect Dis* 1993; 16:190–191
 108. Steer CB, Szer J, Sasadeusz J, et al: Varicella-zoster infection after allogeneic bone marrow transplantation: Incidence, risk factors and prevention with low-dose acyclovir and ganciclovir. *Bone Marrow Transplant* 2000; 25:657–664
 109. Goodrich JM, Reed EC, Mori M, et al: Clinical features and analysis of risk factors for invasive candidal infection after marrow transplantation. *J Infect Dis* 1991; 164:731–740
 110. Asciglu S, Rex JH, de Pauw B, et al: Defining opportunistic invasive fungal infections in immunocompromised patients with cancer and hematopoietic stem cell transplants: An international consensus. *Clin Infect Dis* 2002; 34:7–14
 111. Safdar A, van Rhee F, Henslee-Downey JP, et al: *Candida glabrata* and *Candida krusei* fungemia after high-risk allogeneic marrow transplantation: No adverse effect of low-dose fluconazole prophylaxis on incidence and outcome. *Bone Marrow Transplant* 2001; 28:873–878
 112. Jantunen E, Nihtinen A, Volin L, et al: Candidaemia in allogeneic stem cell transplant recipients: Low risk without fluconazole prophylaxis. *Bone Marrow Transplant* 2004; 34:891–895
 113. Wingard JR: Fungal infections after bone marrow transplant. *Biol Blood Marrow Transplant* 1999; 5:55–68
 114. De La Rosa GR, Champlin RE, Kontoyiannis DP: Risk factors for the development of invasive fungal infections in allogeneic blood and marrow transplant recipients. *Transpl Infect Dis* 2002; 4:3–9
 115. Marr KA, Seidel K, White TC, et al: Candidemia in allogeneic blood and marrow transplant recipients: Evolution of risk factors after the adoption of prophylactic fluconazole. *J Infect Dis* 2000; 181:309–316
 116. Mora-Duarte J, Betts R, Rotstein C, et al: Comparison of caspofungin and amphotericin B for invasive candidiasis. *N Engl J Med* 2002; 347:2020–2029
 117. Kruger W, Stockschrader M, Russmann B, et al: Experience with liposomal Amphotericin-B in 60 patients undergoing high-dose therapy and bone marrow or peripheral blood stem cell transplantation. *Br J Haematol* 1995; 91:684–690
 118. Morrison VA, Haake RJ, Weisdorf DJ: Non-*Candida* fungal infections after bone marrow transplantation: Risk factors and outcome. *Am J Med* 1994; 96:497–503
 119. Wald A, Leisenring W, van Burik JA, et al: Epidemiology of *Aspergillus* infections in a large cohort of patients undergoing bone marrow transplantation. *J Infect Dis* 1997; 175:1459–1466
 120. Paterson DL, Singh N: Invasive aspergillosis in transplant recipients. *Medicine (Baltimore)* 1999; 78:123–138
 121. Marr KA, Carter RA, Boeckh M, et al: Invasive aspergillosis in allogeneic stem cell transplant recipients: Changes in epidemiology and risk factors. *Blood* 2002; 100:4358–4366
 122. Singh N, Paterson DL: *Aspergillus* infections in transplant recipients. *Clin Microbiol Rev* 2005; 18:44–69
 123. Marr KA, Carter RA, Crippa F, et al: Epidemiology and outcome of mould infections in hematopoietic stem cell transplant recipients. *Clin Infect Dis* 2002; 34:909–917
 124. Caillot D, Couaillier JF, Bernard A, et al: Increasing volume and changing characteristics of invasive pulmonary aspergillosis on sequential thoracic computed tomography scans in patients with neutropenia. *J Clin Oncol* 2001; 19:253–259
 125. Soubani AO, Chandrasekar PH: The clinical spectrum of pulmonary aspergillosis. *Chest* 2002; 121:1988–1999
 126. Soubani AO, Qureshi MA: Invasive pulmonary aspergillosis following bone marrow transplantation: risk factors and diagnostic aspect. *Haematologia (Budap)* 2002; 32:427–437
 127. Horvath JA, Dummer S: The use of respiratory-tract cultures in the diagnosis of invasive pulmonary aspergillosis. *Am J Med* 1996; 100:171–178
 128. Soubani AO, Khanchandani G, Ahmed HP: Clinical significance of lower respiratory tract *Aspergillus* culture in elderly hospitalized patients. *Eur J Clin Microbiol Infect Dis* 2004; 23:491–494
 129. Zihlif M, Khanchandani G, Ahmed HP, et al: Surgical lung biopsy in patients with hematological malignancy or hematopoietic stem cell transplantation and unexplained pulmonary infiltrates: Improved outcome with specific diagnosis. *Am J Hematol* 2005; 78:94–99
 130. Maertens J, Verhaegen J, Demuyneck H, et al: Autopsy-controlled prospective evaluation of serial screening for circulating galactomannan by a sandwich enzyme-linked immunosorbent assay for hematological patients at risk for invasive aspergillosis. *J Clin Microbiol* 1999; 37:3223–3228
 131. Maertens J, Verhaegen J, Lagrou K, et al: Screening for circulating galactomannan as a noninvasive diagnostic tool for invasive aspergillosis in prolonged neutropenic patients and stem cell transplantation recipients: A prospective validation. *Blood* 2001; 97:1604–1610
 132. Machetti M, Feasi M, Mordini N, et al: Comparison of an enzyme immunoassay and a latex agglutination system for the diagnosis of invasive aspergillosis in bone marrow transplant recipients. *Bone Marrow Transplant* 1998; 21:917–921
 133. Maertens J, Raad I, Petrikos G, et al: Efficacy and safety of caspofungin for treatment of invasive aspergillosis in patients refractory to or intolerant of conventional antifungal therapy. *Clin Infect Dis* 2004; 39:1563–1571
 134. Maertens J, Van Eldere J, Verhaegen J, et al: Use of circulating galactomannan screening for early diagnosis of invasive aspergillosis in allogeneic stem cell transplant recipients. *J Infect Dis* 2002; 186:1297–1306
 135. Herbrecht R, Denning DW, Patterson TF, et al: Voriconazole versus amphotericin B for primary therapy of invasive aspergillosis. *N Engl J Med* 2002; 347:408–415
 136. Yeghen T, Kibbler CC, Prentice HG, et al: Management of invasive pulmonary aspergillosis in hematology patients: A review of 87 consecutive cases at a single institution. *Clin Infect Dis* 2000; 31:859–868
 137. Lupinetti FM, Behrendt DM, Giller RH, et al: Pulmonary resection for fungal infection in children undergoing bone marrow transplantation. *J Thorac Cardiovasc Surg* 1992; 104:684–687
 138. Dykewicz CA: Summary of the Guidelines for Preventing Opportunistic Infections among Hematopoietic Stem Cell Transplant Recipients. *Clin Infect Dis* 2001; 33:139–144
 139. Centers for Disease Control: Guidelines for preventing opportunistic infections among hematopoietic stem cell transplant recipients. *MMWR Recomm Rep* 2000; 49:1–125, CE121–CE127
 140. Hughes WT, Kuhn S, Chaudhary S, et al: Successful chemoprophylaxis for *Pneumocystis carinii* pneumonitis. *N Engl J Med* 1977; 297:1419–1426

141. Souza JP, Boeckh M, Gooley TA, et al: High rates of *Pneumocystis carinii* pneumonia in allogeneic blood and marrow transplant recipients receiving dapsone prophylaxis. *Clin Infect Dis* 1999; 29:1467-1471
142. Tuan IZ, Dennison D, Weisdorf DJ: *Pneumocystis carinii* pneumonitis following bone marrow transplantation. *Bone Marrow Transplant* 1992; 10:267-272
143. Goldberg MA, Antin JH, Guinan EC, et al: Cyclophosphamide cardiotoxicity: An analysis of dosing as a risk factor. *Blood* 1986; 68:1114-1118
144. Cazin B, Gorin NC, Laporte JP, et al: Cardiac complications after bone marrow transplantation: A report on a series of 63 consecutive transplantations. *Cancer* 1986; 57:2061-2069
145. Hertenstein B, Stefanic M, Schmeiser T, et al: Cardiac toxicity of bone marrow transplantation: predictive value of cardiologic evaluation before transplant. *J Clin Oncol* 1994; 12:998-1004
146. Bearman SI, Petersen FB, Schor RA, et al: Radionuclide ejection fractions in the evaluation of patients being considered for bone marrow transplantation: Risk for cardiac toxicity. *Bone Marrow Transplant* 1990; 5:173-177
147. Akahori M, Nakamae H, Hino M, et al: Electrocardiogram is very useful for predicting acute heart failure following myeloablative chemotherapy with hematopoietic stem cell transplantation rescue. *Bone Marrow Transplant* 2003; 31:585-590
148. Zenhausem R, Tobler A, Leoncini L, et al: Fatal cardiac arrhythmia after infusion of dimethyl sulfoxide-cryopreserved hematopoietic stem cells in a patient with severe primary cardiac amyloidosis and end-stage renal failure. *Ann Hematol* 2000; 79:523-526
149. Alessandrino P, Bernasconi P, Caldera D, et al: Adverse events occurring during bone marrow or peripheral blood progenitor cell infusion: Analysis of 126 cases. *Bone Marrow Transplant* 1999; 23:533-537
150. Auner HW, Tinchon C, Brezinschek RI, et al: Monitoring of cardiac function by serum cardiac troponin T levels, ventricular repolarisation indices, and echocardiography after conditioning with fractionated total body irradiation and high-dose cyclophosphamide. *Eur J Haematol* 2002; 69:1-6
151. Mori T, Yanagi N, Maruyama T, et al: Left ventricular diastolic dysfunction induced by cyclophosphamide in blood stem cell transplantation. *Jpn Heart J* 2002; 43:249-261
152. Gardner SF, Lazarus HM, Bednarczyk EM, et al: High-dose cyclophosphamide-induced myocardial damage during BMT: Assessment by positron emission tomography. *Bone Marrow Transplant* 1993; 12:139-144
153. Buja LM, Ferrans VJ, Graw RG Jr: Cardiac pathologic findings in patients treated with bone marrow transplantation. *Hum Pathol* 1976; 7:17-45
154. Tarella C, Zallio F, Caracciolo D, et al: High-dose mitoxantrone + melphalan (MITO/L-PAM) as conditioning regimen supported by peripheral blood progenitor cell (PBPC) autograft in 113 lymphoma patients: High tolerability with reversible cardiotoxicity. *Leukemia* 2001; 15:256-263
155. Braverman AC, Antin JH, Plappert MT, et al: Cyclophosphamide cardiotoxicity in bone marrow transplantation: A prospective evaluation of new dosing regimens. *J Clin Oncol* 1991; 9:1215-1223
156. Seber A, Khan SP, Kersey JH: Unexplained effusions: Association with allogeneic bone marrow transplantation and acute or chronic graft-versus-host disease. *Bone Marrow Transplant* 1996; 17:207-211
157. Kuruvilla J, Forrest DL, Lavoie JC, et al: Characteristics and outcome of patients developing endocarditis following hematopoietic stem cell transplantation. *Bone Marrow Transplant* 2004; 34:969-973
158. Le Moing V, Lortholary O, Timsit JF, et al: *Aspergillus* pericarditis with tamponade: Report of a successfully treated case and review. *Clin Infect Dis* 1998; 26:451-460
159. Perez Retortillo JA, Marco F, Richard C, et al: Pneumococcal pericarditis with cardiac tamponade in a patient with chronic graft-versus-host disease. *Bone Marrow Transplant* 1998; 21:299-300
160. Rao K, Saha V: Medical management of *Aspergillus flavus* endocarditis. *Pediatr Hematol Oncol* 2000; 17:425-427
161. Safdar A, Childs BH, Keefe D, et al: Acute bacterial endocarditis during granulocytopenia in an allogeneic marrow transplant recipient. *Am J Med* 2000; 109:514-515
162. Vukelja SJ, Baker WJ, Jeffreys P, et al: Non-bacterial thrombotic endocarditis clinically mimicking veno-occlusive disease of the liver complicating autologous bone marrow transplantation. *Am J Clin Oncol* 1992; 15:500-502
163. Gordon BG, Haire WD, Patton DF, et al: Thrombotic complications of BMT: Association with protein C deficiency. *Bone Marrow Transplant* 1993; 11:61-65
164. Hidalgo JD, Krone R, Rich MW, et al: Supraventricular tachyarrhythmias after hematopoietic stem cell transplantation: Incidence, risk factors and outcomes. *Bone Marrow Transplant* 2004; 34:615-619
165. Kupari M, Volin L, Suokas A, et al: Cardiac involvement in bone marrow transplantation: Electrocardiographic changes, arrhythmias, heart failure and autopsy findings. *Bone Marrow Transplant* 1990; 5:91-98
166. McDonald GB, Shulman HM, Sullivan KM, et al: Intestinal and hepatic complications of human bone marrow transplantation: Part II. *Gastroenterology* 1986; 90:770-784
167. Wu D, Hockenberry DM, Brentnall TA, et al: Persistent nausea and anorexia after marrow transplantation: A prospective study of 78 patients. *Transplantation* 1998; 66:1319-1324
168. Ponc R, Hackman RC, McDonald GB: Endoscopic and histologic diagnosis of intestinal graft-versus-host disease after marrow transplantation. *Gastrointest Endosc* 1999; 49:612-621
169. Hutchinson R: Pharmacologic treatment of colonic pseudo-obstruction. *Dis Colon Rectum* 1993; 36:781-783
170. Stephenson BM, Morgan AR, Drake N, et al: Parasympathomimetic decompression of acute colonic pseudo-obstruction. *Lancet* 1993; 342:1181-1182
171. Ko CW, Gooley T, Schoch HG, et al: Acute pancreatitis in marrow transplant patients: Prevalence at autopsy and risk factor analysis. *Bone Marrow Transplant* 1997; 20:1081-1086
172. Adolph MD, Bass SN, Lee SK, et al: Cytomegaloviral acalculous cholecystitis in acquired immunodeficiency syndrome patients. *Am Surg* 1993; 59:679-684
173. Shore T, Bow E, Greenberg H, et al: Pancreatitis post-bone marrow transplantation. *Bone Marrow Transplant* 1996; 17:1181-1184
174. Cox GJ, Matsui SM, Lo RS, et al: Etiology and outcome of diarrhea after marrow transplantation: A prospective study. *Gastroenterology* 1994; 107:1398-1407
175. Chakrabarti S, Lees A, Jones SG, et al: *Clostridium difficile* infection in allogeneic stem cell transplant recipients is associated with severe graft-versus-host disease and non-relapse mortality. *Bone Marrow Transplant* 2000; 26:871-876
176. Bilgrami S, Feingold JM, Dorsky D, et al: Incidence and outcome of *Clostridium difficile* infection following autologous peripheral blood stem cell transplantation. *Bone Marrow Transplant* 1999; 23:1039-1042
177. Wade DS, Nava HR, Douglass HO Jr: Neutropenic enterocolitis: Clinical diagnosis and treatment. *Cancer* 1992; 69:17-23
178. Spencer GD, Shulman HM, Myerson D, et al: Diffuse intestinal ulceration after marrow transplantation: A clinicopathologic study of 13 patients. *Hum Pathol* 1986; 17:621-633
179. Wasserman E, Hidalgo M, Hornedo J, et al: Octreotide (SMS 201-995) for hematopoietic support-dependent high-dose chemotherapy (HSD-HDC)-related diarrhoea: Dose finding study and evaluation of efficacy. *Bone Marrow Transplant* 1997; 20:711-714
180. Kanfer EJ, Abrahamson G, Taylor J, et al: Severe rotavirus-associated diarrhoea following bone marrow transplantation: Treatment with oral immunoglobulin. *Bone Marrow Transplant* 1994; 14:651-652
181. Kaur S, Cooper G, Fakult S, et al: Incidence and outcome of overt gastrointestinal bleeding in patients undergoing bone marrow transplantation. *Dig Dis Sci* 1996; 41:598-603
182. Vishny ML, Blades EW, Creger RJ, et al: Role of upper endoscopy in evaluation of upper gastrointestinal symptoms in patients undergoing bone marrow transplantation. *Cancer Invest* 1994; 12:384-389

183. Wolford JL, McDonald GB: A problem-oriented approach to intestinal and liver disease after marrow transplantation. *J Clin Gastroenterol* 1988; 10:419–433
184. Fallows G, Rubinger M, Bernstein CN: Does gastroenterology consultation change management of patients receiving hematopoietic stem cell transplantation? *Bone Marrow Transplant* 2001; 28:289–294
185. McDonald GB, Sharma P, Matthews DE, et al: The clinical course of 53 patients with venoocclusive disease of the liver after marrow transplantation. *Transplantation* 1985; 39:603–608
186. Bearman SI: The syndrome of hepatic venoocclusive disease after marrow transplantation. *Blood* 1995; 85:3005–3020
187. McDonald GB, Hinds MS, Fisher LD, et al: Veno-occlusive disease of the liver and multiorgan failure after bone marrow transplantation: A cohort study of 355 patients. *Ann Intern Med* 1993; 118:255–267
188. Kalayoglu-Besisik S, Yenerel MN, Caliskan Y, et al: Time-related changes in the incidence, severity, and clinical outcome of hepatic veno-occlusive disease in hematopoietic stem cell transplantation patients during the past 10 years. *Transplant Proc* 2005; 37:2285–2289
189. McDonald GB, Shulman HM, Wolford JL, et al: Liver disease after human marrow transplantation. *Semin Liver Dis* 1987; 7:210–229
190. Lee JH, Lee KH, Kim S, et al: Relevance of proteins C and S, antithrombin III, von Willebrand factor, and factor VIII for the development of hepatic veno-occlusive disease in patients undergoing allogeneic bone marrow transplantation: A prospective study. *Bone Marrow Transplant* 1998; 22:883–888
191. Shulman HM, Gooley T, Dudley MD, et al: Utility of transvenous liver biopsies and wedged hepatic venous pressure measurements in sixty marrow transplant recipients. *Transplantation* 1995; 59:1015–1022
192. Carreras E, Granena A, Navasa M, et al: Transjugular liver biopsy in BMT. *Bone Marrow Transplant* 1993; 11:21–26
193. Bearman SI, Lee JL, Baron AE, et al: Treatment of hepatic venoocclusive disease with recombinant human tissue plasminogen activator and heparin in 42 marrow transplant patients. *Blood* 1997; 89:1501–1506
194. Attal M, Huguet F, Rubie H, et al: Prevention of hepatic veno-occlusive disease after bone marrow transplantation by continuous infusion of low-dose heparin: A prospective, randomized trial. *Blood* 1992; 79:2834–2840
195. Essell JH, Thompson JM, Harman GS, et al: Pilot trial of prophylactic ursodiol to decrease the incidence of veno-occlusive disease of the liver in allogeneic bone marrow transplant patients. *Bone Marrow Transplant* 1992; 10:367–372
196. Richardson P, Bearman SI: Prevention and treatment of hepatic venoocclusive disease after high-dose cytoreductive therapy. *Leuk Lymphoma* 1998; 31:267–277
197. Johnson JR, Egaas S, Gleaves CA, et al: Hepatitis due to herpes simplex virus in marrow-transplant recipients. *Clin Infect Dis* 1992; 14:38–45
198. Mertens T, Kock J, Hampl W, et al: Reactivated fulminant hepatitis B virus replication after bone marrow transplantation: Clinical course and possible treatment with ganciclovir. *J Hepatol* 1996; 25:968–971
199. Hamaguchi M, Yamada H, Gondo H, et al: Retrospective study on the impact of hepatitis B and hepatitis C virus infection on hematopoietic stem cell transplantation in Japan. *Int J Hematol* 2002; 75:324–331
200. Rossetti F, Brawner DL, Bowden R, et al: Fungal liver infection in marrow transplant recipients: Prevalence at autopsy, predisposing factors, and clinical features. *Clin Infect Dis* 1995; 20:801–811
201. Herget-Rosenthal S, Uppenkamp M, Beelen D, et al: Renal complications of high-dose chemotherapy and peripheral blood stem cell transplantation. *Nephron* 2000; 84:136–141
202. Patzer L, Kentouche K, Ringelmann F, et al: Renal function following hematological stem cell transplantation in childhood. *Pediatr Nephrol* 2003; 18:623–635
203. Zager RA: Acute renal failure in the setting of bone marrow transplantation. *Kidney Int* 1994; 46:1443–1458
204. Pulla B, Barri YM, Anaissie E: Acute renal failure following bone marrow transplantation. *Ren Fail* 1998; 20:421–435
205. Zager RA, O'Quigley J, Zager BK, et al: Acute renal failure following bone marrow transplantation: A retrospective study of 272 patients. *Am J Kidney Dis* 1989; 13:210–216
206. Gruss E, Bernis C, Tomas JF, et al: Acute renal failure in patients following bone marrow transplantation: Prevalence, risk factors and outcome. *Am J Nephrol* 1995; 15:473–479
207. Parikh CR, McSweeney PA, Korular D, et al: Renal dysfunction in allogeneic hematopoietic cell transplantation. *Kidney Int* 2002; 62:566–573
208. Kessinger A, Schmit-Pokorny K, Smith D, et al: Cryopreservation and infusion of autologous peripheral blood stem cells. *Bone Marrow Transplant* 1990; 5(Suppl 1):25–27
209. Hale GA, Rochester RJ, Heslop HE, et al: Hemorrhagic cystitis after allogeneic bone marrow transplantation in children: Characteristics and outcome. *Biol Blood Marrow Transplant* 2003; 9:698–705
210. Bielorai B, Shulman LM, Rechavi G, et al: CMV reactivation induced BK virus-associated late onset hemorrhagic cystitis after peripheral blood stem cell transplantation. *Bone Marrow Transplant* 2001; 28:613–614
211. Peinemann F, de Villiers EM, Dorries K, et al: Clinical course and treatment of haemorrhagic cystitis associated with BK type of human polyomavirus in nine paediatric recipients of allogeneic bone marrow transplants. *Eur J Pediatr* 2000; 159:182–188
212. Ambinder RF, Burns W, Forman M, et al: Hemorrhagic cystitis associated with adenovirus infection in bone marrow transplantation. *Arch Intern Med* 1986; 146:1400–1401
213. Miyamura K, Minami S, Matsuyama T, et al: Adenovirus-induced late onset hemorrhagic cystitis following allogeneic bone marrow transplantation. *Bone Marrow Transplant* 1987; 2:109–110
214. Yamamoto R, Kusumi E, Kami M, et al: Late hemorrhagic cystitis after reduced-intensity hematopoietic stem cell transplantation (RIST). *Bone Marrow Transplant* 2003; 32:1089–1095
215. Ribaud P, Gluckman E: Hepatic veno-occlusive disease. *Pediatr Transplant* 1999; 3(Suppl 1):41–44
216. Hingorani SR, Guthrie K, Batchelder A, et al: Acute renal failure after myeloablative hematopoietic cell transplant: Incidence and risk factors. *Kidney Int* 2005; 67:272–277
217. Hahn T, Rondeau C, Shaukat A, et al: Acute renal failure requiring dialysis after allogeneic blood and marrow transplantation identifies very poor prognosis patients. *Bone Marrow Transplant* 2003; 32:405–410
218. Ferra C, de Sanjose S, Lastra CF, et al: Pentoxifylline, ciprofloxacin and prednisone failed to prevent transplant-related toxicities in bone marrow transplant recipients and were associated with an increased incidence of infectious complications. *Bone Marrow Transplant* 1997; 20:1075–1080
219. Woo M, Przepiorka D, Ippoliti C, et al: Toxicities of tacrolimus and cyclosporin A after allogeneic blood stem cell transplantation. *Bone Marrow Transplant* 1997; 20:1095–1098
220. Kobayashi R, Iguchi A, Nakajima M, et al: Hyponatremia and syndrome of inappropriate antidiuretic hormone secretion complicating stem cell transplantation. *Bone Marrow Transplant* 2004; 34:975–979
221. Graus F, Saiz A, Sierra J, et al: Neurologic complications of autologous and allogeneic bone marrow transplantation in patients with leukemia: A comparative study. *Neurology* 1996; 46:1004–1009
222. Sostak P, Padovan CS, Yousry TA, et al: Prospective evaluation of neurological complications after allogeneic bone marrow transplantation. *Neurology* 2003; 60:842–848
223. Bleggi-Torres LF, de Medeiros BC, Werner B, et al: Neuropathological findings after bone marrow transplantation: An autopsy study of 180 cases. *Bone Marrow Transplant* 2000; 25:301–307
224. Gallardo D, Ferra C, Berlanga JJ, et al: Neurologic complications after allogeneic bone marrow transplantation. *Bone Marrow Transplant* 1996; 18:1135–1139
225. Coplin WM, Cochran MS, Levine SR, et al: Stroke after bone marrow transplantation: Frequency, aetiology and outcome. *Brain* 2001; 124:1043–1051

226. Rogers LR, Cho ES, Kempin S, et al: Cerebral infarction from non-bacterial thrombotic endocarditis: Clinical and pathological study including the effects of anticoagulation. *Am J Med* 1987; 83:746–756
227. Mohrmann RL, Mah V, Vinters HV: Neuropathologic findings after bone marrow transplantation: An autopsy study. *Hum Pathol* 1990; 21:630–639
228. Maschke M, Dietrich U, Prumbaum M, et al: Opportunistic CNS infection after bone marrow transplantation. *Bone Marrow Transplant* 1999; 23:1167–1176
229. Derouin F, Gluckman E, Beauvais B, et al: Toxoplasma infection after human allogeneic bone marrow transplantation: Clinical and serological study of 80 patients. *Bone Marrow Transplant* 1986; 1:67–73
230. D'Antonio D, Di Bartolomeo P, Iacone A, et al: Meningitis due to penicillin-resistant *Streptococcus pneumoniae* in patients with chronic graft-versus-host disease. *Bone Marrow Transplant* 1992; 9:299–300
231. Bleggi-Torres LF, de Medeiros BC, Ogasawara VS, et al: Iatrogenic Wernicke's encephalopathy in allogeneic bone marrow transplantation: A study of eight cases. *Bone Marrow Transplant* 1997; 20:391–395
232. Patchell RA: Neurological complications of organ transplantation. *Ann Neurol* 1994; 36:688–703
233. Hauben M: Cyclosporine neurotoxicity. *Pharmacotherapy* 1996; 16:576–583
234. Thompson CB, June CH, Sullivan KM, et al: Association between cyclosporin neurotoxicity and hypomagnesaemia. *Lancet* 1984; 2:1116–1120
235. Adair JC, Woodley SL, O'Connell JB, et al: Aseptic meningitis following cardiac transplantation: Clinical characteristics and relationship to immunosuppressive regimen. *Neurology* 1991; 41:249–252
236. Chatenoud L, Legendre C, Ferran C, et al: Corticosteroid inhibition of the OKT3-induced cytokine-related syndrome: Dosage and kinetics prerequisites. *Transplantation* 1991; 51:334–338
237. Openshaw H: Peripheral neuropathy after bone marrow transplantation. *Biol Blood Marrow Transplant* 1997; 3:202–209
238. Mackey JR, Desai S, Larratt L, et al: Myasthenia gravis in association with allogeneic bone marrow transplantation: Clinical observations, therapeutic implications and review of literature. *Bone Marrow Transplant* 1997; 19:939–942
239. Amato AA, Barohn RJ, Sahenk Z, et al: Polyneuropathy complicating bone marrow and solid organ transplantation. *Neurology* 1993; 43:1513–1518
240. Zeigler ZR, Shaddock RK, Nemunaitis J, et al: Bone marrow transplant-associated thrombotic microangiopathy: A case series. *Bone Marrow Transplant* 1995; 15:247–253
241. Fuge R, Bird JM, Fraser A, et al: The clinical features, risk factors and outcome of thrombotic thrombocytopenic purpura occurring after bone marrow transplantation. *Br J Haematol* 2001; 113:58–64
242. Roy V, Rizvi MA, Vesely SK, et al: Thrombotic thrombocytopenic purpura-like syndromes following bone marrow transplantation: An analysis of associated conditions and clinical outcomes. *Bone Marrow Transplant* 2001; 27:641–646
243. Allford SL, Bird JM, Marks DI: Thrombotic thrombocytopenic purpura following stem cell transplantation. *Leuk Lymphoma* 2002; 43:1921–1926
244. Ruutu T, Hermans J, Niederwieser D, et al: Thrombotic thrombocytopenic purpura after allogeneic stem cell transplantation: A survey of the European Group for Blood and Marrow Transplantation (EBMT). *Br J Haematol* 2002; 118:1112–1119
245. Pettitt AR, Clark RE: Thrombotic microangiopathy following bone marrow transplantation. *Bone Marrow Transplant* 1994; 14:495–504
246. Holler E, Kolb HJ, Hiller E, et al: Microangiopathy in patients on cyclosporine prophylaxis who developed acute graft-versus-host disease after HLA-identical bone marrow transplantation. *Blood* 1989; 73:2018–2024
247. Kanamori H, Maruta A, Sasaki S, et al: Diagnostic value of hemostatic parameters in bone marrow transplant-associated thrombotic microangiopathy. *Bone Marrow Transplant* 1998; 21:705–709
248. Arai S, Allan C, Streiff M, et al: von Willebrand factor-cleaving protease activity and proteolysis of von Willebrand factor in bone marrow transplant-associated thrombotic microangiopathy. *Hematol J* 2001; 2:292–299
249. Juckett M, Perry EH, Daniels BS, et al: Hemolytic uremic syndrome following bone marrow transplantation. *Bone Marrow Transplant* 1991; 7:405–409
250. Sarode R, McFarland JG, Flomenberg N, et al: Therapeutic plasma exchange does not appear to be effective in the management of thrombotic thrombocytopenic purpura/hemolytic uremic syndrome following bone marrow transplantation. *Bone Marrow Transplant* 1995; 16:271–275
251. Chown SR, Goulden N, Cornish JM, et al: The role of plasma exchange for TTP/HUS post-bone marrow transplant. *Bone Marrow Transplant* 1996; 17:898–899
252. Iacopino P, Pucci G, Arcese W, et al: Severe thrombotic microangiopathy: An infrequent complication of bone marrow transplantation. Gruppo Italiano Trapianto Midollo Osseo (GITMO). *Bone Marrow Transplant* 1999; 24:47–51
253. Afessa B, Tefferi A, Dunn WF, et al: Intensive care unit support and Acute Physiology and Chronic Health Evaluation III performance in hematopoietic stem cell transplant recipients. *Crit Care Med* 2003; 31:1715–1721
254. Ventilation with lower tidal volumes as compared with traditional tidal volumes for acute lung injury and the acute respiratory distress syndrome: The Acute Respiratory Distress Syndrome Network. *N Engl J Med* 2000; 342:1301–1308
255. Hilbert G, Gruson D, Vargas F, et al: Non-invasive ventilation in immunosuppressed patients with pulmonary infiltrates, fever, and acute respiratory failure. *N Engl J Med* 2001; 344:481–487
256. Rubenfeld GD, Crawford SW: Withdrawing life support from mechanically ventilated recipients of bone marrow transplants: Case for evidence-based guidelines. *Ann Intern Med* 1996; 125:625–633