

Sarcoidosis

T.J. Giuffrida, MD, Francisco A. Kerdel, BSc, MBBS*

*Department of Dermatology and Cutaneous Surgery, University of Miami School of Medicine,
1400 NW 12th Avenue, Miami, FL 33136, USA*

Sarcoidosis is a systemic disorder of unknown origin characterized histologically by noncaseating granulomas that can occur in any organ of the body. It most commonly involves the lungs, lymph nodes, skin, liver, spleen, eyes, bone, and glandular tissue. There is no consistent diagnostic laboratory test for sarcoidosis, although several laboratory abnormalities may be found. These include hypercalcemia, hypercalcuria, hypergammaglobulinemia, an elevated angiotensin-converting enzyme level, and in vitro evidence of depressed cellular immunity. When the diagnosis is suspected, characteristic histopathologic findings, although nonspecific, must be demonstrated and other granuloma-forming processes such as tuberculosis, fungal infection, and various foreign bodies must be excluded. Sarcoidosis has a highly variable course ranging from an acute self-limiting process to a chronic, debilitating systemic disease [1,2].

Clinical manifestations

Cutaneous manifestations

Cutaneous involvement occurs in ~25% of sarcoidosis and most often appears simultaneously with systemic disease [3–5]. Screening for systemic sarcoidosis is indicated in any granulomatous skin lesion without an apparent diagnosis [3,6]. Skin lesions may be classified as specific, which reveal granulomas on histology, or nonspecific, which are typically a reactive process [5]. The lesions generally have no prognostic significance or correlation with disease severity

or systemic involvement [2,3,6,7]. Exceptions to this include erythema nodosum and lupus pernio. Erythema nodosum, although nonspecific, is the hallmark of acute sarcoidosis and tends to have a good prognosis because of its association with spontaneously resolving disease [8–10]. Lupus pernio, which is sarcoid specific, has been associated with bone cysts, sarcoidosis of the upper respiratory tract, and pulmonary fibrosis [1,2,11].

Many morphologic skin lesion types have been described for sarcoidosis and, like syphilis, it is a great mimic of other diseases. Common specific or granulomatous skin lesions in sarcoidosis include macules, papules, nodules, plaques, subcutaneous nodules, lupus pernio, and infiltrative scars [5,6,12]. Papules are the most common of the specific cutaneous lesions (Fig. 1) [6,12]. These may be localized or generalized and are typically firm, red-brown to violaceous in color, and less than 1 cm in size. Diascopy (examination under a glass slide) of the lesions may give a characteristic “apple-jelly” color [13]. They are commonly found on the head, neck, and extremities but rarely in the oral cavity. The periorbital area and lips are frequently involved [5,6,12].

Plaques of sarcoidosis indicate deeper granulomatous involvement and can be found on any area of the body [1]. They are typically indurated, with prominent borders and a red-brown color [6,12]. When the lesions have large telangiectasias they are called angiolupoid [1,3]. Plaque lesions have been associated with chronic sarcoidosis. The lesions tend to resolve with scarring, and alopecia has been reported [6,14].

Lupus pernio (Fig. 2) is a chronic plaque-type lesion of sarcoidosis that progresses slowly, often causing significant disfigurement resulting from fibrosis and scarring [11]. Lesions are indurated, brown to purple, and appear on the nose, lips, cheeks, and

* Corresponding author.

E-mail address: fkerdel@med.miami.edu (F.A. Kerdel)

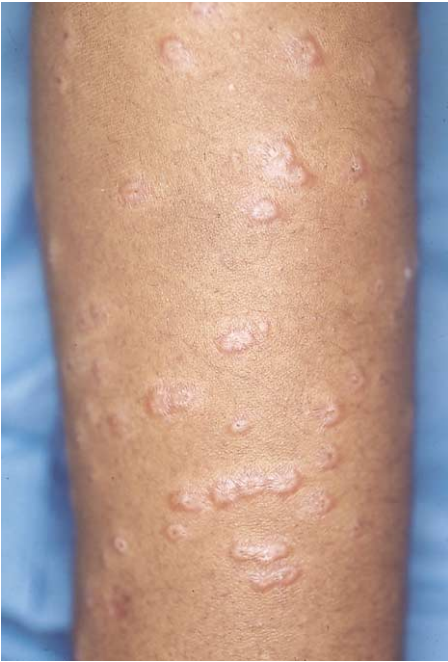

Fig. 1. Papular sarcoidosis on the arm.

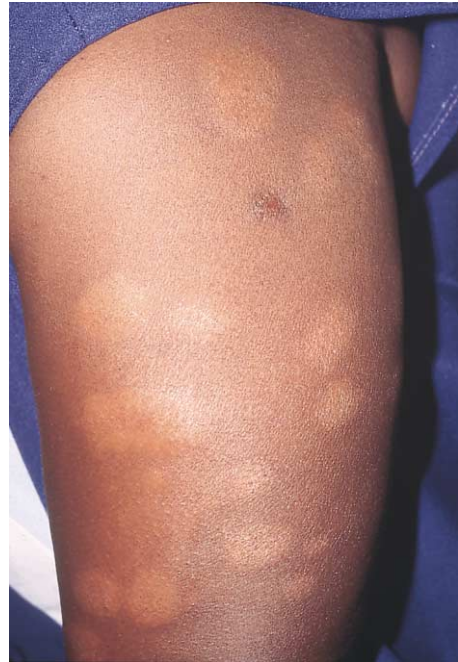

Fig. 3. Hypopigmented lesions in a patient with sarcoidosis.

ears [5,12,15]. The nose lesion can involve the nasal mucosa and underlying bone, leading to perforation [16]. It is the most characteristic skin lesion of sarcoidosis and is most common in African-American women [3,5,6,15]. The association of lupus pernio with upper respiratory tract involvement is well recognized, and includes the nasal and oral mucosa [17], larynx and pharynx [18], salivary glands [19], tonsil, and tongue [20]. It is often accompanied with pulmonary infiltration and fibrosis, chronic uveitis, and bone cysts [2,11]. Spontaneous remission of skin and systemic lesions is extremely rare [2].

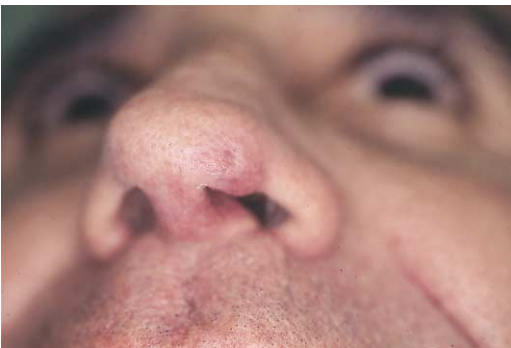

Fig. 2. Lupus pernio with a violaceous lesion on the nose.

Subcutaneous nodules, or Darier-Roussy sarcoidosis, are typically painless, firm, oval lesions that exhibit no signs of inflammation on the skin surface. They are typically found on the trunk and extremities [3,6,12,21]. This is a form of panniculitis that exclusively involves the subcutaneous tissue and does not extend into the dermis [22].

Scars or areas of skin chronically damaged by infection, radiation, or mechanical trauma may become infiltrated with sarcoidosis [2]. These lesions

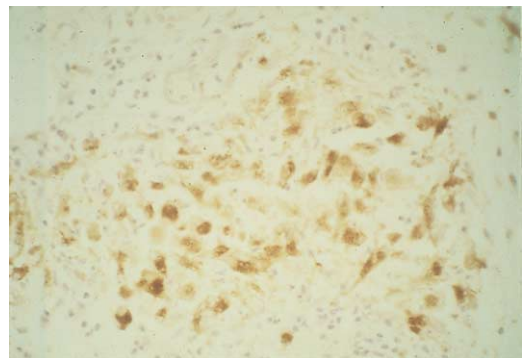


Fig. 4. Naked granuloma with macrophages stained for lysozyme from a patient with a positive Kviem test.

develop a red or purple discoloration with induration and can appear early in the disease, parallel chronic disease, or indicate possible reactivation of the disease [3,6,12,23].

Other less common specific presentations of sarcoidosis that have been reported include erythroderma [2,24], ulcerative [25,26], verrucous [25], ichthyosiform [24,27], psoriaform [25], hypopigmented (Fig. 3) [28], faint erythema [29], folliculitis [2], lichenoid [3], eruptive [3], red plaques of palm and soles [2], lower extremity edema [30], nodules of finger tips [31], penile and vulvar papules and plaques [32–34], chelitis [35], erythema annulare centrifugum [36], annular elastolytic [37], palmar erythema [38], rosacea-like [39], morpheaform [40], perforating [3], lupus erythematosus-like [11], umbilicated [41], and scarring and nonscarring alopecia [42]. Specific and nonspecific nail changes may also occur [12,43–46].

Erythema nodosum is a hypersensitivity reaction that can be caused by many different infections, inflammatory bowel disease, and medications. It is the most common nonspecific cutaneous lesion of sarcoidosis and has been reported to occur in up to 25% of cases [11,47]. Lesions are typically erythematous, firm, subcutaneous nodules most commonly found on the anterior shins. Young women are most frequently affected and lesions occur commonly in Caucasians and uncommonly in American blacks. Erythema nodosum is the hallmark of acute sarcoidosis and is accompanied by a good prognosis because of the associated high rate of spontaneous resolution [8–10]. In a review by Neville, Walker, and James of 251 cases of sarcoidosis presenting with erythema nodosum, 83% of patients had remission of their disease within 2 years [10]. Other reviews have also found that the absence of erythema nodosum is a risk for persistent disease [9]. Skin lesions of sarcoidosis other than erythema nodosum were more commonly associated with lymphadenopathy and hepatosplenomegaly [47]. Lofgren's syndrome is the combination of erythema nodosum with fever, polyarthralgias or polyarthritis, uveitis, and bilateral hilar lymphadenopathy [2]. It is an acute form of sarcoidosis and typically resolves without treatment. Other nonspecific cutaneous lesions of sarcoidosis reported include erythema multiforme, erythroderma, pruritus, and calcifications [12]. Sarcoidosis presenting with leonine facies has also been reported [48].

Pulmonary manifestations

Pulmonary disease is the most common clinical manifestation of sarcoidosis [1]. Lung manifestations are found in 90% of cases of sarcoidosis and patients

may be asymptomatic or present with dyspnea, cough, chest pain, and in rare cases hemoptysis [3,15]. Sarcoidosis of the lung can be staged radiographically with prognostic implications [49]. Stage 0 shows no changes on radiograph; stage I consists of bilateral hilar and/or paratracheal adenopathy without parenchymal disease; stage II is bilateral hilar adenopathy with pulmonary infiltrates; stage III is pulmonary infiltrates without adenopathy; stage IV is irreversible fibrosis and bullae formation. Bilateral hilar adenopathy is the earliest and most common intrathoracic manifestation of sarcoidosis [11]. The majority of patients with stage I disease have spontaneous resolution and patients may not need histologic confirmation by biopsy if asymptomatic or displaying signs of Lofgren's syndrome [11]. Chronic pulmonary disease is much more common with stages II and III [11]. Up to 15% of patients with sarcoidosis have irreversible fibrosis and severe disability [21]. Less common intrathoracic findings include bronchial stenosis with obstruction, pleural thickening, pleural effusion, and calcification [2].

Ocular manifestations

Ocular disease occurs in 25% to 50% of patients with sarcoidosis and is the second most common manifestation of sarcoidosis [11]. Sarcoidosis can affect any structure of the eye but most commonly presents as acute anterior uveitis [50]. Other forms of ocular disease include iris nodules, conjunctival granulomas, corneal and lacrimal gland involvement, scleral plaques, and posterior uveitis [2,11,50]. Conjunctival granulomas are present in up to one third of patients, and positive biopsy results are often obtained in this area even if they are not clinically suspected [2]. Involvement of the posterior chamber of the eye most commonly presents as chorioretinitis [2,11].

Lymphadenopathy, splenomegaly, and bone marrow involvement

When hilar nodes are included, lymphadenopathy has an incidence of 90% in patients with sarcoidosis [2,11] and is associated with both acute and chronic disease. Enlarged nodes are usually asymptomatic and nontender when palpated. Splenic involvement is present in up to 25% of patients [2] and is associated with diffuse fibrotic changes in other organs [51].

Bone marrow and hematologic changes of sarcoidosis such as leukopenia, lymphocytopenia, and an ele-

vated erythrocyte sedimentation rate can be seen in up to 40% of patients [3].

Endocrine manifestations

The incidence of endocrine gland disease is typically low in sarcoidosis. When involved, the hypothalamic and pituitary areas are the most frequently affected, and can manifest as diabetes insipidus and panhypopituitarism [2]. Sarcoidosis has also been reported to involve the thyroid, parathyroid, adrenal glands, and pancreas. Mikulicz's syndrome is bilateral sarcoidal involvement of the parotid, submandibular, sublingual, and lacrimal glands [3]. Lacrimal and salivary gland involvement may clinically produce a Sjogrens's-like syndrome [11].

Hypercalcemia can be seen in sarcoidosis and is caused by alveolar macrophage secretion of 1,25 dihydroxyvitamin D3 that is independent of feedback mechanisms [52]. Granuloma production of vitamin D3 is not suppressed with supplemental oral calcium [53].

Hepatic manifestations

Sarcoidal involvement of the liver is not uncommon and blind liver biopsy can give a positive result in up to 60% of patients [2,11]. Obstructive jaundice can be a manifestation of hepatic granulomas [54], and liver function tests, such as alkaline phosphatase, may be abnormally elevated [21].

Cardiac manifestations

Autopsy studies have shown 10% to 20% of sarcoidosis cases in the United States and 67% in Japan to have cardiac muscle granulomas [55]. Clinically, however, only 5% of cases have cardiac manifestations [56]. Roberts et al found conduction defects and ventricular arrhythmias to be the most common manifestations in symptomatic patients [2]. Cardiac findings include electrocardiographic abnormalities such as complete heart block and arrhythmias, papillary muscle dysfunction, infiltrative cardiomyopathy with congestive heart failure, and pericarditis. In 5% to 10% of cases of cardiac sarcoidosis, sudden cardiac death can be the initial manifestation. Roberts et al found that symptomatic disease was associated with sudden death in 60 of 89 patients [2]. Cardiac disease should be evaluated using myocardial scintigraphy with thallium 201, echocardiography, 24-hour Holter monitor, and gallium 67 scan [3,15].

Musculoskeletal manifestations

Up to 39% of patients with sarcoidosis have musculoskeletal involvement [57]. Muscle disease is typically asymptomatic [2], but random tissue biopsy often gives a positive result [2]. Muscle disease, though rare, can present as acute and chronic myositis, secondary atrophy, hypertrophy, contracture [11], myopathy [58], muscle nodules [59], and tumor-like lesions [60]. Clinical presentations include weakness, pain, tenderness, and erythema and warmth of the overlying skin [49].

Bone lesions occur in up to 20% of sarcoidosis patients and are usually asymptomatic [11]. Lesions tend to be cystic and favor the terminal phalanges of the hands and feet [11]. Bone involvement often indicates chronic, progressive disease and is seen with pulmonary changes and lupus pernio [11].

Acute and chronic arthralgias and arthritis have been reported in sarcoidosis [61,62]. Acute lesions are often seen in Lofgren's syndrome, while chronic lesions are rare [11]. The wrists, knees, and ankles are the most commonly affected joints.

Neurologic manifestations

Neurosarcoidosis affects 5% to 10% of sarcoid patients [4,63,64]. Half of these patients have central nervous system involvement [11]. All cranial nerves may be involved, with the most common presentation being cranial nerve VII as a self-limited palsy [63,64]. Other manifestations of neurologic sarcoidosis include peripheral nerve involvement [65], psychiatric changes [63,64], aseptic meningitis [66], space-occupying masses [65], sudden hearing loss [67], seizures [63,64], stroke [68], and arachnoiditis/perivasculitis [69]. Heerfordt's syndrome or uveoparotid fever consists of uveitis, facial nerve palsy, fever, and parotid gland enlargement, and is frequently associated with central nervous system involvement [11].

Other clinical manifestations

Sarcoidal granulomas can affect almost any body organ. Renal involvement may present as nephritis, with or without identifiable renal granulomas [49], and nephrolithiasis and nephrocalcinosis [70]. Urethral obstruction [71] and hydronephrosis [72] have also been reported.

In uncommon cases, sarcoidosis affects the gastrointestinal system. Presentations include a stomach ulcer or mass [73], dysphagia [74], pancreatitis [75], appendicitis [76], and small bowel obstruction [77].

Other sites of sarcoidosis involvement reported include the breasts, uterus, fallopian tubes, ovaries, testicles, epididymis, and prostate gland [3,33,78–81].

Childhood sarcoidosis

There are two types of sarcoidosis in children: late onset (ages 8 to 15) and early onset (age 4 or less). Late onset disease has similar clinical manifestations to adult sarcoidosis. Arthritis, uveitis, and skin lesions without bilateral hilar lymphadenopathy are the classic triad of early onset childhood sarcoidosis and this can mimic juvenile rheumatoid arthritis [82]. Skin lesions are usually macular and papular, with erythema nodosum being unusual [83]. The typical lung disease of sarcoidosis is not usually present initially [84]. Almost all children have complaints of fever, weight loss, and fatigue [85]. Peripheral adenopathy is present in approximately two thirds of patients [83], and when skin lesions are not present, lymph nodes are the best site for biopsy [84]. There is a significant morbidity in childhood sarcoidosis even though most patients have spontaneous resolution [84]. Glucocorticoids are the treatment of choice [85].

Blau syndrome, a rare autosomal dominant granulomatous disease, is similar to childhood sarcoidosis in that it presents with arthritis, uveitis, and skin lesions [86]. It has been linked to chromosome 16p12-q21 and, unlike sarcoidosis, lacks pulmonary involvement [87]. Skin lesions have similar histology to sarcoidosis and can appear as red macules [86].

Incidence and epidemiology

Sarcoidosis primarily affects young adults between 25 and 35 years of age. It also affects women between the ages of 45 and 65 years [3,88]. In the United States, sarcoidosis affects women approximately 10 times more frequently than men [11]. African Americans are also more frequently affected than whites, have more severe and prolonged disease, and have more atypical cutaneous expressions [11,49,89].

The incidence of sarcoidosis is recorded as follows [3]: Sweden, 64/100,000; United Kingdom, 20/100,000; France 10/100,000; Germany, 9/100,000; Greece 7/100,000; Spain, 1.4/100,000; and Japan 1.4/100,000 [21,90,91]. In the United States, the incidence in the white population is 10/ to 14/100,000 and 35.5/ to 64/100,000 for African Americans [92].

Etiology

The cause of sarcoidosis is unknown. Immunologic mechanisms, genetic susceptibility, and infectious and environmental agents have all been implicated as possible factors. There is much speculation as to whether the cause is multifactorial or caused by an antigen(s) that has not yet been identified [3].

Immunology

Immunologic abnormalities found in sarcoidosis include polyclonal hyperglobulinemia [11,21], circulating immune complexes, a depressed cell-mediated immunity often manifested by skin anergy, and decreased peripheral lymphocytic blastogenesis [11]. Noncaseating granulomas are thought to form through antigenic stimulation of CD4 T lymphocytes/TH1 phenotype through macrophage presentation [93,94]. The T cells in sarcoidosis predominantly express α/β T-cell receptors, are major histocompatibility complex (HLA) class II restricted [4,95], and depend on the B7:CD28/CTLA-4 costimulatory pathway for activation [96].

There is a highly focused, antigen-driven immune response within tissue affected by sarcoidosis [97]. The CD4 T cells redistribute from the peripheral blood, manifesting as anergy [98], and localize in tissues involved in the inflammatory process [3,99]. Once localized, lymphocytes proliferate and induce granuloma formation through production of cytokines (interleukin 2, interferon- γ , IL-8, and tumor necrosis factor- α). Other immunomodulatory cells including macrophages, natural killer cells, and mast cells are believed to be involved [100]; subsequently, there is shift in the cytokine profile to that of TH2 CD4 T cells which has been demonstrated during the fibroproliferative phase of the granuloma and is believed to result in tissue scarring [100].

T-helper lymphocytes of sarcoid alveolitis have been shown to stimulate B-lymphocytes in vitro to produce immunoglobulin [11]. This may account for the presence of a polyclonal hyperglobulinemia and immune complex formation.

Genetics

No consistent inheritance pattern has been established for sarcoidosis, but support for a certain genetic makeup is evident by the presence of positive familial clusters [101,102]. Certain HLA typing has been associated with sarcoidosis. A positive association with sarcoidosis has been reported with HLA-A1, -B8, and -DR3, and a negative association

has been reported with HLA-B12 and DR-4. Other HLA associations include disease limited to the lungs and HLA-B21; early disease onset and HLA-B13 and -B35; and good outcome of disease and HLA-DR3 [103]. The HLA-DRB1 locus has also been used to determine susceptibility to sarcoidosis [104]. Possible evidence for genetics playing a role in sarcoidosis has been found involving angiotensin-converting enzyme (ACE) polymorphism [105], the presence of GLU residue at position 69 of HLA-DPB1 [106], and the increased expression of the acute-phase reactant genes ORM1 (orosomucoid) and HP1 (haptoglobin) [107]. Erythema nodosum associated with sarcoidosis may be pathogenically linked to altered tumor necrosis factor- α (TNF- α) production caused by a genetic promoter polymorphism [108].

Infectious and environmental agents

Fungal, viral, and bacterial agents have all been implicated as possible causative factors in sarcoidosis despite lack of definitive identification or proof. The association of tuberculosis and sarcoidosis is controversial. Despite being inconclusive, polymerase chain reaction (PCR) studies have caused mycobacterium tuberculosis to re-emerge as a possible causative agent in sarcoidosis [3]. Many studies support this association [109], while numerous others give evidence against any relationship [110]. Unfortunately, PCR does not discriminate between living or dead mycobacteria and is fragile and easily contaminated, therefore rendering it a poor method of evaluation for the etiology of sarcoidosis [111,112]. Further evidence against a mycobacterial cause includes studies in which these organisms have not been demonstrated in the lesions or successfully grown in appropriate culture media, a lack of fulminant mycobacterial disease with the use of immunosuppressives in patients with sarcoidosis, the fact that Bacille Calmette Guerin vaccination does not reduce the incidence of sarcoidosis, and the fact that antituberculosis medications are ineffective in treating sarcoidosis [111,113,114]. Occasional elevation of fungal and viral antibody titers in patients with sarcoidosis is likely caused by a nonspecific polyclonal elevation of immunoglobulins [11].

Environmental antigens implicated but not proven in the etiology of sarcoidosis include clay, talc, pine pollen, oxalosis, beryllium, and zirconium [115,116]. Nonsmokers have been found to have sarcoidosis more often than smokers [3]. Seasonal clustering of sarcoidosis lesions also suggests an environmental factor [117].

Associated disorders

Autoimmune disease, neoplasia, and medications have all been associated in sarcoidosis, and this may be related to the overall immune system disturbance of this condition. Many autoimmune diseases have been reported to occur with sarcoidosis, which may result from the immunologic dysfunction and polyclonal gammopathy [3]. Lymphoproliferative disease, most commonly Hodgkin's lymphoma, has been reported with sarcoidosis [118]. Medications reported to induce sarcoidosis include interferon- α , particularly in the treatment of hepatitis C [119,120] and chronic myelogenous leukemia [3], and interferon- β treatment for multiple myeloma [121]. Ulcerative sarcoidosis has been induced in previous cutaneous lesions with therapy using the flashlamp-pumped pulsed dye laser [122].

Histopathology

The classic histologic finding in sarcoidosis is that of a noncaseating granuloma composed of epithelioid cells and occasional Langhans giant cells. Inclusion bodies (asteroid bodies/entrapped collagen or Schaumann bodies/altered lysosomes [13]) are frequently observed in giant cells but are nonspecific. Lymphocytes, macrophages, and fibroblasts may surround the granulomas, but there are typically few inflammatory cells, the so-called "naked" tubercles [11]. Similar histologic findings are present in other conditions. It is therefore important to perform special stains and cultures to rule out an infectious granuloma, polarize the specimen to examine for foreign bodies, and to rule out an underlying neoplasm exhibiting an associated sarcoidal reaction [11]. Marcoval et al [123] concluded that foreign body material is not uncommon in cutaneous lesions of sarcoidosis patients after finding polarizable foreign particles in 14 of 65 cutaneous biopsy specimens from patients with sarcoidosis.

Diagnosis and evaluation

Evaluation of a patient with suspected sarcoidosis involves a combination of clinical, radiologic, and laboratory findings along with histologic examination of affected tissue. A diagnostic test for sarcoidosis does not exist, and physical examination should focus on the skin, lungs, eyes, nerves, and the heart [3]. Tissue biopsy of any abnormalities

should show evidence of noncaseating granulomas, while polarization for foreign bodies and cultures and stains for infectious causes should be negative. Several satisfactory biopsy sites exist to confirm a diagnosis of sarcoidosis. The skin is very accessible and any suspicious skin lesions should be biopsied [2,124]. Other valuable biopsy sites include the conjunctiva, which is positive in one third of patients even when ocular lesions are not present [2]; peripheral nodes, which may be positive in up to 75% of patients [11]; minor salivary glands of the lower lip, which are positive in greater than half of the patients [2]; and muscle biopsy, which shows positive results in ~50% of patients [2]. Lung biopsy with a fiberoptic bronchoscope is sometimes indicated [21]. Bronchoscopy with transbronchial lymph node biopsy can be performed, at which time bronchoalveolar lavage may also be evaluated for leukocyte differential counts. A diagnosis is suggested when the CD4/CD8 ratio is greater than 3.5 [125]. Mediastinoscopy and biopsies of the liver, spleen, and bone marrow are less commonly performed because of low yield or high incidence of morbidity.

Chest radiography is helpful in the diagnosis and evaluation of sarcoidosis; however, this cannot be used as the sole diagnostic procedure. Gallium scans can be helpful when used as a complement to other diagnostic tools [126], while computed tomography of the chest is often overused and does not affect therapeutic treatment [49]. Ga gallium scans may demonstrate panda and/or lambda appearance, which are gallium uptake by parotid and lacrimal gland sarcoidosis (panda) and by the bilateral hilar lymph node (lambda) [126,127]. Gallium scanning may identify lesions of nodular cutaneous sarcoidosis [128]. Technetium-74m-tetrofosmin scintigraphy and somatostatin analogue scintigraphy may also be useful in suspected sarcoidosis evaluation [129,130].

Laboratory evaluation for sarcoidosis includes complete blood count, liver and renal function tests, protein electrophoresis, serum and urine Ca, ACE level, and erythrocyte sedimentation rate [3,11]. Additional evaluation should include ophthalmologic evaluation including slit lamp examination and electrocardiography, tuberculin/anergy testing, and pulmonary function tests [4,6,21,131]. The Kviem test involves intradermal injection of spleen or lymph node homogenate from a patient with sarcoidosis into another patient with suspected sarcoidosis, whose skin is later biopsied for evidence of sarcoid granuloma (Fig. 4) [114,132]. This test may be an interesting immunologic phenomenon but is of very

limited practical use and is not approved by the Food and Drug Administration [1,3].

Measurement of disease progression

Pulmonary function tests are useful for monitoring the respiratory status of a patient but may not correlate with disease progression or activity [11,21]. Gallium scans and bronchoalveolar lavage are also not typically used to monitor disease progression [21].

The angiotensin-converting enzyme (ACE) level is elevated in about 60% of patients with sarcoidosis [5]. This enzyme is derived from the epithelioid cells of the granuloma and reflects the granuloma load in the body, but is not specific for sarcoidosis and can be elevated in other conditions [49,133]. ACE levels may be used as an adjunct for diagnosis of sarcoidosis but not for the specific diagnosis because of the high false-negative (10%) and false-positive (40%) rates when used for diagnosis [3,88]. It is generally not a useful method for determining disease progression or response to therapy [2,3,88,114].

Numerous experimental methods have been reported to evaluate disease progression in sarcoidosis. These include TNF- α and serum IL-2 [134]; serum IL-2 receptors [135]; serum TNF-receptor II levels [136]; serum IL-8 [137]; locally derived IL-6 and IL-8 [138]; serum procollagen I and III [139]; serum vitamin D₃, IL-10, and CD23 [98]; CD26 [140]; T-cell receptor γ/δ expression in the peripheral circulation [141]; circulation E-selectin [99]; serum intercellular adhesion molecule-1 [142]; and serum copper [143].

Treatment

Cutaneous involvement of sarcoidosis is typically asymptomatic and is not life threatening. The major indication for treating these lesions is disfigurement [49]. Glucocorticoids are the mainstay of treatment and lesions can be treated with oral, intralesional, or topical therapy. Limited cutaneous disease may respond to superpotent topical corticosteroids [144], topical steroid with occlusive dressing [145], hydrocortisone 5% powder in hydrophilic ointment with phonophoresis [146], and intralesional triamcinolone repeated monthly [147]. Other effective nonoral therapies reported include intralesional choroquine [148], carbon dioxide or pulsed dye laser for lupus pernio [149,150], dermabrasion, surgical excision with grafting, and plastic surgery [3].

Lesions resistant to topical therapy and large or diffuse lesions may require systemic therapy. Many

therapies have been reported to have some success, including prednisone [21,25,147,153], hydroxychloroquine [147,154,155], chloroquine [151], methotrexate [152,153,156], allopurinol [158,159], thalidomide [160–162], isotretinoin [3,163], PUVA [3,153], UVA 1 [164], tranilast [165], melatonin [166], propidine [167], and minocin [168]. Prednisone therapy has been used successfully both as a tapered daily dose [3] and alternate-day dose [147]. Hydroxychloroquine is administered with a daily or alternate-day dose of 200 to 400 mg [147,154,155]. Chloroquine is typically given at 250 mg/d for long-term suppression; Zic et al [151] recommend an initial 14-day course of 500 mg. Methotrexate has been effective in both chronic cutaneous disease and lung disease [152, 153,156]. Typical dosage is 15 to 25 mg/wk in three divided doses at 11-hour intervals [147]. Baughman and Lower noted 94% of 17 patients noted improvement in cutaneous lesions treated with methotrexate [169]. Allopurinol has been effective for cutaneous sarcoidosis at doses of 100 to 300 mg/d for several months [157–159]. Thalidomide works by inhibiting cytokines, especially TNF- α , and has been reported to be effective in doses up to 200 mg/d [160–162,170]. PUVA has been reported to be successful in erythrodermic and hypopigmented lesions [3,153]. Isotretinoin, usually in doses of 0.5 to 1.0 mg/kg/d, has shown resolution of lesions after six or more weeks [3,163]. Eight of eleven patients showed complete remission of their skin lesions after treatment with minocin (200 mg/d) for a median of 11 months [168].

Determining when to treat systemic sarcoidosis depends on the extent and activity of the inflammatory lesions and the organs at greatest risk. Evaluation of the lungs, eyes, heart, and central nervous system are essential. Glucocorticoids are the therapy of choice [4], and the suggested dosage of prednisone for systemic sarcoidosis is 1 mg/kg for 4 to 6 weeks and then a slow taper over 2 to 3 months [21]. The action mechanism of steroids in sarcoidosis is unknown, but it has been reported that a normal TH1/TH2 balance is re-established between the locally produced cytokines and immunoglobulin isotypes in the sarcoid lung [171]. To avoid long-term steroid-induced morbidity in chronic disease, non-steroidal immunosuppressive medications are used despite only anecdotal data for efficacy [4,121,154]. Some of the more common agents used are antimetabolites, methotrexate, azathioprine, chlorambucil, cyclophosphamide, and cyclosporine [15,154,169]. Infliximab, an anti-human TNF- α monoclonal antibody, recently has been reported to have promising results in complicated sarcoidosis [172,173].

Prognosis/mortality

Sarcoidosis has spontaneous remission in up to 60% of cases. Corticosteroids increase this rate by 10 to 20% [89]. Acute sarcoidosis consisting of bilateral hilar adenopathy alone or in combination with erythema nodosum and other inflammatory manifestations is typically self-limited and may resolve spontaneously in more than 80% of the cases [9,10]. Ten percent to twenty percent of patients have chronic, progressive disease and mortality is ~1% to 5% [15]. Causes of death are most commonly caused by cardiac and pulmonary complications and include pneumonia, pulmonary fibrosis, chronic obstructive pulmonary disease, cardiac arrhythmias, and sudden cardiac death [133,174,175]. Mortality rates have been found to be higher in age-adjusted African American patients compared to white patients and in females compared to males within racial strata [176].

Morbidity of sarcoidosis includes ocular disease causing scarring and blindness, pulmonary disease causing shortness of breath and fatigue, and cutaneous disfigurement. Granulomatous involvement of the kidneys, calcium deposits, and kidney stones can cause renal failure.

References

- [1] Callen JP, Jorizzo JL, Greer KE, et al. Sarcoidosis. In: Callen JP, editor. *Dermatological signs of internal disease*. 2nd edition. Philadelphia: WB Saunders; 1995. p. 293–300.
- [2] Zax RH, Callen JP. Sarcoidosis. In: *Skin sign of internal disease*. *Dermatol Clin* 1989;7:505–15.
- [3] English JC, Patel PJ, Greer KE. Sarcoidosis. *J Am Acad Dermatol* 2001;44:725–43.
- [4] Newman LS, Rose CS, Maier LA. Sarcoidosis. *N Engl J Med* 1997;336:1224–34.
- [5] Sharma OP. Sarcoidosis of the skin. In: Freedberg IM, Eisen AZ, Wolff K, et al. *Fitzpatrick's dermatology in general medicine*, vol II. New York: McGraw-Hill; 1999. p. 2099–106.
- [6] Mana J, Marcoval J, Graells J, et al. Cutaneous involvement in sarcoidosis: relationship to systemic disease. *Arch Dermatol* 1997;133:882–8.
- [7] Veien NK, Stahl D, Brodthagen H. Cutaneous sarcoidosis in Caucasians. *J Am Acad Dermatol* 1987;16: 534–40.
- [8] Cancrini C, Angelini F, Colavita M, et al. Erythema nodosum: a presenting sign of early onset sarcoidosis. *Clin Exp Rheumatol* 1998;16:337–9.
- [9] Mana J, Salazar A, Manresa F. Clinical factors predicting persistence of activity in sarcoidosis: a multivariate analysis of 193 cases. *Respiration* 1994;61: 219–25.

- [10] Neville E, Walker AN, James DG. Prognostic factors predicting the outcome of sarcoidosis: an analysis of 818 patients. *Q J Med* 1983;52:525–33.
- [11] Kerdel FA, Moschella SL. Sarcoidosis: an updated review. *J Am Acad Dermatol* 1984;11:1–19.
- [12] Elgart ML. Cutaneous sarcoidosis: definitions and types of lesions. *Clin Dermatol* 1986;4:35–45.
- [13] Rabinowitz OL, Zaim MT. A clinicopathologic approach to granulomatous dermatoses. *J Am Acad Dermatol* 1996;35:588–600.
- [14] Takahashi H, Mori M, Muraoka S, et al. Sarcoidosis presenting as a scarring alopecia: report of a rare cutaneous manifestation of systemic sarcoidosis. *Dermatology* 1996;193:144–6.
- [15] Anonymous. Statement of sarcoidosis: joint statement of the American Thoracic Society (ATS), the European Respiratory Society (ERS) and the World Association of Sarcoidosis and Other Granulomatous Disorders (WASOG) adopted by the ATS board of directors and by the ERS executive committee. *Am J Respir Crit Care Med* 1999;160:736–55.
- [16] Jorizzo JL, Koufman IA, Thompson JN, et al. Sarcoidosis of upper respiratory tract in patients with nasal rim lesions: a pilot study. *J Am Acad Dermatol* 1990;22:439–43.
- [17] Eveson JW. Granulomatous disorders of the oral mucosa. *Semin Diagn Pathol* 1996;13:118–27.
- [18] Sataloff RT, Spiegel JR, Heuer RJ. Laryngeal sarcoidosis and candidiasis. *Ear Nose Throat J* 1995;74:77.
- [19] Vijay V, Newman R, Bebawi MA, et al. Sarcoid nodule: its association with wide-spread sarcoidosis. *Oral Surg Oral Med Oral Pathol Oral Radiol Endodont* 1995;79:449–51.
- [20] Serrat SA, Lobo VP, Redondo GLM, et al. Oral sarcoidosis with tongue involvement. *Oral Surg Oral Med Oral Pathol Oral Radiol Endodont* 1997;83:668–71.
- [21] Crystal RG. Sarcoidosis. In: Fauci AS, Braunwald E, Isselbacher KJ, et al. *Harrison's principles of internal medicine*. New York: McGraw-Hill; 1998. p. 1922–8.
- [22] Requena L, Sanchez Yus E. Panniculitis: part II: mostly lobular panniculitis. *J Am Acad Dermatol* 2001;45:342–3.
- [23] Manz LA, Rodman OG. Reappearance of quiescent scars: sarcoidosis. *Arch Dermatol* 1993;129:105,108.
- [24] Feind-Koopmans AG, Lucker GP, van de Kerkhof PC. Acquired ichthyosiform erythroderma and sarcoidosis. *J Am Acad Dermatol* 1996;35:826–8.
- [25] Albertini JG, Tyler W, Miller OF. Ulcerative sarcoidosis: case report and review of literature. *Arch Dermatol* 1997;133:215–9.
- [26] Hruza GJ, Kerdel FA. Generalized atrophic sarcoidosis with ulcerations. *Arch Dermatol* 1986;122:320–2.
- [27] Cather JC, Cohen PR. Ichthyosiform sarcoidosis. *J Am Acad Dermatol* 1999;40:862–5.
- [28] Handa S, Handa U. Sarcoidosis presenting as cutaneous hypopigmentation. *Int J Dermatol* 1995;34:824.
- [29] Okano M, Nisimura H, Morimoto Y, et al. Faint erythema: another manifestation of cutaneous sarcoidosis? *Int J Dermatol* 1997;36:681–4.
- [30] Hoover Jr RD, Stricklin G, Curry TW, et al. Unilateral lower extremity edema caused by infiltrative sarcoidosis. *J Am Acad Dermatol* 1994;30:498–500.
- [31] Di Landro A, Naldi L, Locati F, et al. Nodular lesions on fingertips. *Arch Dermatol* 1996;132:460,463.
- [32] Klein PA, Appel J, Callen JP. Sarcoidosis of the vulva: a rare cutaneous manifestation. *J Am Acad Dermatol* 1998;39:281–3.
- [33] Mahmood N, Afzail N, Joyce A. Sarcoidosis of the penis. *Br J Urol* 1997;80:155.
- [34] Wei H, Friedman KA, Rudikoff D. Multiple indurated papules on the penis and scrotum. *J Cut Med Surg* 2000;4:202–4.
- [35] Bourgeois-Droin C, Havard S, Granier F, et al. Granulomatous cheilitis in two children with sarcoidosis. *J Am Acad Dermatol* 1993;29:822–4.
- [36] Altomare GF, Capella GL, Grigerio E. Sarcoidosis presenting as erythema annulare centrifugum. *Clin Exp Dermatol* 1995;20:502–3.
- [37] Terui T, Tagami H. Annular elastolytic sarcoidosis of the face. *Eur J Dermatol* 1998;8:127–30.
- [38] Cliff S, Hart Y, Knowles G, Misch K. Sarcoidosis presenting as palmar erythema. *Clin Exp Dermatol* 1998;23:123–4.
- [39] Simonart T, Lowy M, Rasquin R, et al. Overlap of sarcoidosis and rosacea. *Dermatology* 1997;194:416–8.
- [40] Burov EA, Kantor GR, Isaac M. Morpheaform sarcoidosis: report of three cases. *J Am Acad Dermatol* 1998;39:345–8.
- [41] Kashyap S, Kumar M, Thami GP, et al. Umbilicated papular sarcoidosis. *Clin Exp Dermatol* 1996;21:395–6.
- [42] Katta R, Nelson B, Chen D, et al. Sarcoidosis of the scalp: a case series and review of the literature. *J Am Acad Dermatol* 2000;42:690–2.
- [43] Davies MG, McGavin CR. Onycholysis in sarcoidosis: a previously undescribed association. *Br J Dermatol* 1996;135:340.
- [44] Fujii K, Kanno Y, Ohgo N. Subungual hyperkeratosis due to sarcoidosis. *Int J Dermatol* 1997;36:125–7.
- [45] Losada-Campa A, De La Torre-Fraga C, Gomez de Liano A, et al. Histopathology of nail sarcoidosis. *Acta Derm Venereol* 1995;75:404–5.
- [46] Wakelin SH, James MP. Sarcoidosis: nail dystrophy without underlying bone changes. *Cutis* 1995;55:344–6.
- [47] Olive KE, Kataria YP. Cutaneous manifestations of sarcoidosis: relationships to other organ system involvement, abnormal laboratory measurements, and disease course. *Arch Intern Med* 1985;145:1811–4.
- [48] Ford PG, Jorizzo JL, Hitchcock MG. Previously undiagnosed sarcoidosis in a patient presenting with leonine facies and complete heart block. *Arch Dermatol* 2000;136:712–4.
- [49] Johns CJ, Michelle TM. The clinical management of sarcoidosis: a 50-year experience at the Johns Hopkins Hospital. *Medicine (Baltimore)* 1999;78:65–111.

- [50] Ghabrial R, McCluskey FJ, Wakefield D. Spectrum of sarcoidosis involving the eye and brain. *Aust N Z J Ophthalmol* 1997;25:221–4.
- [51] Salazar A, Mana J, Corbella X, et al. Splenomegaly in sarcoidosis: a report of 16 cases. *Sarcoidosis* 1995; 12:131–4.
- [52] Sharma OP. Vitamin D, calcium, and sarcoidosis. *Chest* 1996;109:535–9.
- [53] Basile JN, Liel Y, Shary J, et al. Increased calcium intake does not suppress circulating 1,25-dihydroxyvitamin D in normocalcemic patients with sarcoidosis. *J Clin Invest* 1993;91:1396–8.
- [54] Rezeig MA, Fahir BM. Biliary tract obstruction due to sarcoidosis. *Am J Gastroenterol* 1997;92:527–8.
- [55] Iwai K, Sekiguti M, Hosoda Y, et al. Racial difference in cardiac sarcoidosis incidence observed at autopsy. *Sarcoidosis* 1994;11:26–31.
- [56] Fields CL, Ossoria MA, Roy TM, et al. Thallium 201 scintigraphy in the diagnosis and management of myocardial sarcoidosis. *South Med J* 1990;83:339–42.
- [57] Johnson DL, Yamakido M, Sharma OP. Musculoskeletal involvement in sarcoidosis. *Semin Res Med* 1992;13:515–9.
- [58] Matsuo M, Ehara S, Tamakawa Y, et al. Muscular sarcoidosis. *Skeletal Radiol* 1995;24:535–7.
- [59] Otake S. Sarcoidosis involving skeletal muscle: imaging findings and relative value of imaging procedures. *Am J Roentgenol* 1994;162:369–75.
- [60] Zisman DA, Biermann JS, Martinez F, et al. Sarcoidosis presenting as a tumorlike muscular lesion: case report and review of the literature. *Medicine (Baltimore)* 1999;78:112–22.
- [61] Glennas A, Kvien TK, Melby K, et al. Acute sarcoid arthritis: occurrence, seasonal onset, clinical features and outcome. *Br J Rheumatol* 1995;34:45–50.
- [62] Larsen TK. Tenosynovitis as initial diagnosis of sarcoidosis: case report. *Scand J Plast Reconstr Surg Hand Surg* 1996;30:257–9.
- [63] Chapelon C, Ziza JM, Piette JC, Levy Y, et al. Neurosarcoidosis: signs, course and treatment in 35 confirmed cases. *Medicine (Baltimore)* 1990;69:261–76.
- [64] Lower EE, Broderick JP, Brott TG, et al. Diagnosis and management of neurological sarcoidosis. *Arch Intern Med* 1997;157:1864–8.
- [65] Sharma OP. Neurosarcoidosis: a personal prospective based on the study of 37 patients. *Chest* 1997;112: 220–8.
- [66] James DG. A comparison of sarcoidosis and Behçet's disease. *Sarcoidosis* 1995;12:2–6.
- [67] Sugaya F, Shijubo N, Takahashi H, et al. Sudden hearing loss as the initial manifestation of neurosarcoidosis. *Sarcoidosis Vasc Diffuse Lung Dis* 1996;13: 54–6.
- [68] Duffey P, Bates K. Transient focal neurological deficit in sarcoidosis. *Sarcoidosis Vasc Diffuse Lung Dis* 1997;14:171–2.
- [69] Makarov AI, Turichin VI, Kostina ZI. The diagnosis and treatment of neurosarcoidosis. *Zh Nevropatel Psikhiatr Im S S Korsakova* 1995;95:90–3.
- [70] Rizzato G, Frialoi P, Montemurro L. Nephrolithiasis as a presenting feature of chronic sarcoidosis. *Thorax* 1995;50:555–9.
- [71] Carr LK, Honey RJ, Sugar L. Diagnosis and management of urethral sarcoidosis. *J Urol* 1995;153:1612–3.
- [72] Miyazaki E, Tsuda T, Mochizuki A, et al. Sarcoidosis presenting as a bilateral hydronephrosis. *Int Med* 1996;35:579–82.
- [73] Farman J, Ramirez G, Rybak B, et al. Gastric sarcoidosis. *Abdom Imaging* 1997;22:248–52.
- [74] Achermann E, Bingisser R, Krause M. A case of acute sarcoidosis. *Schweiz Rundsch Med Prax* 1996;85:632–5.
- [75] Lazaro AL, Morato AA, Teran SJ, et al. Acute pancreatitis and sarcoidosis: a case report and review of the literature. *Arch Bronconeumol* 1995;31:290–2.
- [76] Cullinane DC, Schultz SC, Zellos L, et al. Sarcoidosis manifesting as acute appendicitis: report of a case. *Dis Colon Rectum* 1997;41:109–11.
- [77] Noel JM, Katona IM, Pineiro-Carrero VM. Sarcoidosis resulting in duodenal obstruction in an adolescent. *J Pediatr Gastroenterol Nutr* 1997;24:594–8.
- [78] Carmody JP, Sharma OP. Intra-scrotal sarcoidosis: case reports and review. *Sarcoidosis Vasc Diffuse Lung Dis* 1996;13:129–34.
- [79] Kenzel PP, Hadijuana J, Hosten N, et al. Sarcoidosis of the breast: mammographic, ultrasound, and MR findings. *J Comput Assist Tomogr* 1997;21:439–41.
- [80] Martin B, Rutchik S, Rayford W, et al. Sarcoidosis presenting as bilateral testicular masses. *J Urol* 2001; 165:534.
- [81] Pearce KF, Nolan TE. Endometrial sarcoidosis as a cause of postmenopausal bleeding: a case report. *J Reprod Med* 1996;41:878–80.
- [82] Yotsumoto S, Takahashi Y, Takei S, et al. Early onset sarcoidosis masquerading as juvenile rheumatoid arthritis. *J Am Acad Dermatol* 2000;43:969–71.
- [83] James DG, Kendig Jr EL. Childhood sarcoidosis. *Sarcoidosis* 1988;5:57.
- [84] Pattishall EN, Kendig EL. Sarcoidosis in children. *Pediatr Pulmonol* 1996;22:195–203.
- [85] Shetty AK, Correa H, Galen W, et al. Childhood sarcoidosis. *Arch Pediatr Adolesc Med* 1997;151:955–6.
- [86] Manouvrier-Hanu S, Puech B, Piette F, et al. Blau syndrome of granulomatous arthritis, iritis, and skin rash: a new family and review of the literature. *Am J Med Genet* 1998;76:217–21.
- [87] Tromp G, Kuivaniemi H, Raphael S, et al. Genetic linkage of familial granulomatous inflammatory arthritis, skin rash, and uveitis to chromosome 16. *Am J Hum Genet* 1996;59:1097–107.
- [88] Chestnutt AN. Enigmas in sarcoidosis. *West J Med* 1995;162:519–26.
- [89] Peckham DG, Spiteri MA. Sarcoidosis. *Postgrad Med J* 1996;72:196–200.
- [90] Hosoda Y, Yamaguchi M, Hiraga Y. Global epidemiology of sarcoidosis: what story do prevalence and incidence tell us? *Clin Chest Med* 1997;18: 681–94.

- [91] James DG. Epidemiology of sarcoidosis. *Sarcoidosis* 1992;9:79–87.
- [92] Reich JM, Johnson R. Incidence of clinically identified sarcoidosis in a northwest United States population. *Sarcoidosis Vasc Diffuse Lung Dis* 1996;13:173–7.
- [93] Grunewald J, Olerup O, Persson U, Ohn MB, et al. T-cell receptor variable region gene usage by CD4+ and CD8- Tcells in bronchoalveolar lavage fluid and peripheral blood of sarcoidosis patients. *Proc Natl Acad Sci USA* 1994;91:4965–9.
- [94] Jones RE, Chatham WW. Update on sarcoidosis. *Curr Opin Rheumatol* 1999;11:83–7.
- [95] Eklund A, Grunewald J. The riddle of sarcoidosis: have novel techniques brought any new insights as to the causative agent? *J Intern Med* 1996;240:59–62.
- [96] Epstein WL, James DG. Multiple benign sarcoid of the skin. *Arch Dermatol* 1999;135:1450.
- [97] De Rose V, Trentin L, Crivellari MT, et al. Release of prostaglandin E2 and leukotriene B4 by alveolar macrophages from patients with sarcoidosis. *Thorax* 1997;52:76–83.
- [98] Bansal AS, Bruce J, Hogan PG, et al. An assessment of peripheral immunity in patients with sarcoidosis using measurement of serum vitamin D3, cytokines, and soluble CD 23. *Clin Exp Immunol* 1997;110:92–7.
- [99] Hamblin AS, Shakoor Z, Kapahi P, et al. Circulating adhesion molecules in sarcoidosis. *Clin Exp Immunol* 1994;96:335–8.
- [100] Agostini C, Costabel U, Semenzato G. Sarcoidosis news: immunologic frontiers for new immunosuppressive strategies. *Clin Immunol Immunopathol* 1998;88:199–204.
- [101] Rybicki BA, Harrington D, Major M, et al. Heterogeneity of familial risk in sarcoidosis. *Genet Epidemiol* 1996;13:23–33.
- [102] Rybicki BA, Malirik MJ, Major M, et al. Epidemiology, demographics and genetics of sarcoidosis. *Semin Respir Infect* 1998;13:166–73.
- [103] Martinetti M, Tinelli C, Kolek V, et al. The sarcoidosis map: a joint survey of clinical and immunogenetic findings in two European countries. *Am J Respir Crit Care Med* 1995;152:557–64.
- [104] Ishihara M, Inoko H, Suzuki K, et al. HLA class II genotyping of sarcoidosis patients in Hokkaido by PCR-RFLP. *Jpn J Ophthalmol* 1996;40:540–3.
- [105] Furuya K, Yamaguchi E, Itoh A, et al. Deletion polymorphism in angiotensin I converting enzyme (ACE) genes a genetic risk factor for sarcoidosis. *Thorax* 1996;51:777–80.
- [106] Lympany PA, Petrek M, Southcott AM, et al. HLA-DPB polymorphisms: Flu 69 association with sarcoidosis. *Eur J Immunogenet* 1996;23:353–9.
- [107] Fan C, Nylander PO, Sikstrom C, et al. Orosomucoid and haptoglobin types in patients with sarcoidosis. *Exp Clin Immunogenet* 1995;12:31–5.
- [108] Labunski S, Posern G, Ludwig S, et al. Tumor necrosis factor- α promoter polymorphism in erythema nodosum. *Acta Derm Venereol* 2001;81:18–21.
- [109] Popper HH, Clemens H, Hoefler G, et al. Presence of mycobacterial DNA in sarcoidosis. *Hum Pathol* 1997;28:796–800.
- [110] Vokura M, Lecossier D, du Bois RM, et al. Absence of DNA from mycobacteria of the *M. tuberculosis* complex in sarcoidosis. *Am J Respir Crit Care Med* 1997;156:1000–3.
- [111] Degitz K. Detection of mycobacterial DNA in the skin. *Arch Dermatol* 1996;132:71–5.
- [112] Mangiapan G, Hance AJ. Mycobacteria and sarcoidosis: an overview and summary of recent molecular biological data. *Sarcoidosis* 1995;12:20–37.
- [113] Sutherland I. Mycobacteria and sarcoidosis: BCG ineffective against sarcoidosis. *BMJ* 1993;306:1270.
- [114] Teirstein A, Padilla M, De Palo L, et al. Sarcoidosis mythology. *Mt Sinai J Med* 1996;53:335–41.
- [115] James DG. Sarcoidosis: part 8: granulomatous diseases of unproved etiology. In: Beeson PB, McDermott W, Wyngaarden JB, editors. *Textbook of medicine*. Philadelphia: WB Saunders; 1979. p. 209–16.
- [116] Kon OM, du Bois RM. Mycobacteria and sarcoidosis. *Thorax* 1997;52:S47–51.
- [117] Wilsher ML. Seasonal clustering of sarcoidosis presenting with erythema nodosum. *Eur Respir J* 1998;12:1997–9.
- [118] Karakantza M, Matutes E, MacLennan K, et al. Association between sarcoidosis and lymphoma revisited. *J Clin Pathol* 1996;49:208–12.
- [119] Nakajima M, Kubota Y, Miyahita N, et al. Recurrence of sarcoidosis following interferon alpha therapy for chronic hepatitis C. *Int Med* 1996;35:376–9.
- [120] Otte HG, Hartig C, Stadler R. Sarcoidosis in interferon-alpha therapy. *Hautarzt* 1997;48:482–7.
- [121] Bobbio-Pallavicini E, Valsecch C, Taaconi F, et al. Sarcoidosis following beta-interferon therapy for multiple myeloma. *Sarcoidosis* 1995;12:140–2.
- [122] Green JJ, Lawrence N, Heymann WR. Generalized ulcerative sarcoidosis induced by therapy with the flashlamp-pumped pulsed dye laser. *Arch Dermatol* 2001;137:507–8.
- [123] Marcoval J, Mana J, Moreno A, et al. Foreign bodies in granulomatous cutaneous lesions of patients with systemic sarcoidosis. *Arch Dermatol* 2001;137:427–30.
- [124] Callen JP. Sarcoidosis. In: Callen JP, editor. *Dermatological signs of internal disorders*. Chicago: Year Book Medical Publishers; 1980. p. 847–66.
- [125] Winterbauer RH, Lammert J, Selland M, et al. Bronchoalveolar lavage cell populations in the diagnosis of sarcoidosis. *Chest* 1993;104:352–61.
- [126] Sakurai Y, Nakajimi M, Kamisu S, et al. Preschool sarcoidosis mimicking juvenile rheumatoid arthritis: the significance of gallium scintigraphy and skin biopsy in the differential diagnosis. *Acta Paediatr* 1997;29:74–8.
- [127] Kurdziel KA. The panda sign. *Radiol* 2000;215:884–5.
- [128] Kalani G, Maled H. Extensive cutaneous sarcoidosis Ga-67 imaging. *Clin Nucl Med* 1996;21:489–90.

- [129] Eklund A, Jacobsson H, Larsson SA, et al. Detection of extrathoracic manifestations in sarcoidosis with somatostatin analogue scintigraphy. *Sarcoidosis Vasc Diffuse Lung Dis* 1997;14:146–51.
- [130] Tschabitscher D, Gallowitsch HJ, Mikosch P, et al. Technetium-99-tetrofosmin uptake in sarcoidosis stage I. *J Nucl Med* 1997;38:1776–7.
- [131] Mana J, Salazar A, Pujol R, et al. Are the pulmonary function tests and the markers of activity helpful to establish the prognosis of sarcoidosis? *Respiration* 1996;63:298–303.
- [132] Klein JT, Horn TD, Forman JD, et al. Selection of oligoclonal V beta specific T cells in the intradermal response to Kveim-Siltzbach reagent in individuals with sarcoidosis. *J Immunol* 1995;154:1450–60.
- [133] Puryear DW, Fowler III AA. Sarcoidosis: a clinical overview. *Compr Ther* 1996;22:649–53.
- [134] Ziegenhagen MW, Benner UK, Zissel G, et al. Sarcoidosis: TNF-alpha release from alveolar macrophages and serum level of IL-2R. *Am J Respir Crit Care Med* 1997;156:1586–92.
- [135] Muller-Quernheim J. Sarcoidosis: immunopathogenetic concepts and their clinical application. *Eur Respir J* 1998;12:716–38.
- [136] Nakayama T, Hashimoto S, Amemiya E, et al. Elevation of plasma-soluble tumor necrosis factor receptors (TNF-R) in sarcoidosis. *Clin Exp Immunol* 1996;104:318–24.
- [137] Yokoyama T, Kanda T, Kobayashi I, et al. Serum levels of interleukin-8 as a marker of disease activity in patients with chronic sarcoidosis. *J Med* 1995;26:209–19.
- [138] Takizawa H, Satoh M, Okazaki H, et al. Increased IL-6 and IL-8 in bronchoalveolar lavage fluids (BALF) from patients with sarcoidosis: correlation with the clinical parameters. *Clin Exp Immunol* 1997;107:175–81.
- [139] Bacchella L, Tinelli C, Gile LS, et al. Serum type I and type III procollagen peptide levels in sarcoidosis. *Eur Respir J* 1996;9:1648–51.
- [140] Scheel-Toellner D, Richter E, Toellner KM, et al. CD26 expression in leprosy and other granulomatous diseases correlates with the production of interferon-gamma. *Lab Invest* 1995;73:685–90.
- [141] Shigehara K, Shijubo N, Nakanishi F, et al. Circulating gamma delta-T-cell-receptor-positive lymphocytes in sarcoidosis. *Respiration* 1995;62:84–8.
- [142] Shijubo N, Imai K, Shigehara K, et al. Circulating soluble intercellular adhesion molecule-1(sICAM-1) in patients with sarcoidosis. *Clin Exp Immunol* 1996;106:549–54.
- [143] Donghi M, Giura R, Antonelli PI. Increase of serum copper concentration in Lofgren syndrome. *Sarcoidosis* 1995;12:147–9.
- [144] Khatri KA, Chotzen VA, Burrall BA. Lupus pernio: successful treatment with a potent topical corticosteroid. *Arch Dermatol* 1995;131:617–8.
- [145] Volden G. Successful treatment of chronic skin diseases with clobetasol propionate and a hydrocolloid occlusive dressing. *Acta Derm Venereol* 1992;72:69–71.
- [146] Gogstetter DS, Goldsmith LA. Treatment of cutaneous sarcoidosis using phonophoresis. *J Am Acad Dermatol* 1999;40:767–9.
- [147] Russo G, Millikan LE. Cutaneous sarcoidosis: diagnosis and treatment. *Comp Ther* 1994;29:418–21.
- [148] Liedtka JE. Intralesional chloroquine for the treatment of cutaneous sarcoidosis. *Int J Dermatol* 1996;35:682–3.
- [149] Cliff S, Felix RH, Singh L, et al. The successful treatment of lupus pernio with the flashlamp pulsed dye laser. *J Cutan Laser Ther* 1999;1:49–52.
- [150] Stack Jr BC, Hall PJ, Goodman AL, et al. CO2 laser excision of lupus pernio of the face. *Am J Otolaryngol* 1996;17:260–3.
- [151] Zic JA, Horowitz DH, Arzubiaiga C, et al. Treatment of cutaneous sarcoidosis with chloroquine. *Arch Dermatol* 1991;127:1034–40.
- [152] Lower EE, Baughman RP. Prolonged use of methotrexate for sarcoidosis. *Arch Intern Med* 1995;155:846–51.
- [153] Veien NK. Cutaneous sarcoidosis: prognosis and treatment. *Clin Dermatol* 1986;4:75–87.
- [154] Baughman RP, Lower EE. Alternatives to corticosteroids in the treatment of sarcoidosis. *Sarcoidosis Vasc Diffuse Lung Dis* 1997;14:12–30.
- [155] Jones E, Callen JP. Hydroxychloroquine is effective therapy for control of cutaneous sarcooidal granulomas. *J Am Acad Dermatol* 1990;23:487–9.
- [156] Webster GF, Razi LK, Sanches M, et al. Weekly low-dose methotrexate therapy for cutaneous sarcoidosis. *J Am Acad Dermatol* 1991;24:451–4.
- [157] Antony F, Layton AM. A case of cutaneous acral sarcoidosis with response to allopurinol. *Br J Dermatol* 2000;142:1052–3.
- [158] Brechtel B, Hass N, Henz BM, et al. Allopurinol: a therapeutic alternative for disseminated cutaneous sarcoidosis. *Br J Dermatol* 1996;135:307–9.
- [159] Voelter-Mahlknecht S, Benex A, Metzger S, et al. Treatment of subcutaneous sarcoidosis with allopurinol. *Arch Dermatol* 1999;135:1560–1.
- [160] Carlesimo M, Giustini S, Rossi A, et al. Treatment of cutaneous and pulmonary sarcoidosis with thalidomide. *J Am Acad Dermatol* 1995;32:866–9.
- [161] Lee JB, Koblenzer PS. Disfiguring cutaneous manifestation of sarcoidosis treated with thalidomide: a case report. *J Am Acad Dermatol* 1998;39:835–8.
- [162] Rousseau L, Beylot-Barry M, Doutre MS, et al. Cutaneous sarcoidosis successfully treated with low doses of thalidomide. *Arch Dermatol* 1998;134:1045–6.
- [163] Georgiou S, Monastirli A, Pasmatzis E, et al. Cutaneous sarcoidosis: complete remission after oral isotretinoin therapy. *Acta Derm Venereol* 1998;78:457–9.
- [164] Graefe T, Konrad H, Barta U, et al. Successful ultraviolet A1 treatment of cutaneous sarcoidosis. *Br J Dermatol* 2001;145:354–5.
- [165] Yamada H, Ide A, Sugiura M, et al. Treatment of cutaneous sarcoidosis with ultraviolet A1 and isotretinoin. *Acta Derm Venereol* 1998;78:457–9.

- neous sarcoidosis with tranilast. *J Dermatol* 1995; 22:149–52.
- [166] Cagnoni ML, Lombardi A, Cerinic MM, et al. Melatonin for treatment of chronic refractory sarcoidosis. *Lancet* 1995;346:1229–30.
- [167] Samstov AV. Cutaneous sarcoidosis. *Int J Dermatol* 1992;31:385–91.
- [168] Bachelez H, Senet P, Cadranet J, et al. The use of tetracyclines for the treatment of sarcoidosis. *Arch Dermatol* 2001;137:69–73.
- [169] Baughman RP, Lower EE. Steroid-sparing alternative treatments for sarcoidosis. *Clin Chest Med* 1997;18: 853–64.
- [170] Tseng S, Pak G, Washenik K, et al. Rediscovering thalidomide: a review of its mechanism of action, side effects, and potential uses. *J Am Acad Dermatol* 1996; 35:969–79.
- [171] Milburn HJ, Poulter LW, Dilmec A, et al. Corticosteroids restore the balance between locally produced Th1 and Th2 cytokines and immunoglobulin isotypes to normal in sarcoid lung. *Clin Exp Immunol* 1997; 108:105–13.
- [172] Baughman RP, Lower EE. Infliximab for refractory sarcoidosis. *Sarcoidosis Vasc Diffuse Lung Dis* 2001; 18:70–4.
- [173] Yee AM, Pochapin MB. Treatment of complicated sarcoidosis with infliximab anti-tumor necrosis factor-alpha therapy. *Ann Intern Med* 2001;135:27–31.
- [174] Perry A, Vuitch F. Causes of death in patients with sarcoidosis: a morphologic study of 38 autopsies with clinicopathologic correlations. *Arch Pathol Lab Med* 1995;119:167–72.
- [175] Sekiguchi M, Yazaki Y, Isobe M, et al. Cardiac sarcoidosis: diagnostic, prognostic, and therapeutic considerations. *Cardiovasc Drug Ther* 1996;10:495–510.
- [176] Gideon NM, Mannino DM. Sarcoidosis mortality in the United States 1979–1991: an analysis of multiple-cause mortality data. *Am J Med* 1996;100:423–7.