

## ORIGINAL ARTICLE

# Oral sarcoidosis: a review of literature

L Suresh, L Radfar

Department of Oral Diagnostic Sciences, School of Dental Medicine, State University of New York at Buffalo, Buffalo, NY, USA

**Sarcoidosis is a common systemic granulomatous disease affecting multiple organs. Oral involvement is relatively rare and, to our knowledge, there have been only 64 cases reported in the English literature. Most cases of oral sarcoidosis present with mobility of the teeth due to rapid alveolar bone loss. Other oral manifestations include asymptomatic swelling of the involved mucosa, gingivitis and ulcers. Diagnosis of sarcoidosis is by exclusion as no specific test is available. Radiographic, biochemical and histological findings are non-specific, but helpful. All cases of sarcoidosis do not require treatment. Corticosteroids are the treatment of choice in patients requiring treatment. Other drugs such as chloroquine, methotrexate, infliximab and thalidomide are also used in the treatment of sarcoidosis. In most of the oral cases reported, systemic steroids and surgery were the preferred treatment.**

*Oral Diseases* (2005) 11, 138–145

**Keywords:** oral; sarcoidosis

### Introduction

Sarcoidosis is a systemic non-caseating granulomatous disease of unknown etiology. Jonathan Hutchinson, an English surgeon-dermatologist, reported the first case of sarcoidosis in 1875, but the term sarcoidosis was introduced later by Boeck in 1899 (James, 1997), which in Greek means, 'flesh-like condition' (Chesnutt, 1995). Sarcoidosis affects all individuals regardless of race, sex or age. There is a worldwide difference in incidence rates of sarcoidosis. The reported incidence rate is 64 cases per 100 000 in the Sweden and 20 cases per 100 000 in the UK (James, 1992). In the USA, there is a wide racial variation in incidence rate, with 35.5–64 cases per 100 000 for African-Americans and 10–14 cases per

100 000 for Caucasians (Reich and Johnson, 1996). The disease exhibits a slight female predilection and a bimodal age distribution (Hillerdal *et al*, 1984; Hosoda *et al*, 1997). The first peak is between the ages of 25 and 35 years and the second peak is at 45 and 65 years (Hillerdal *et al*, 1984). Seasonal variations have been observed worldwide, with the peak incidence observed during late winter and early spring (Fite *et al*, 1996; Hosoda *et al*, 1997).

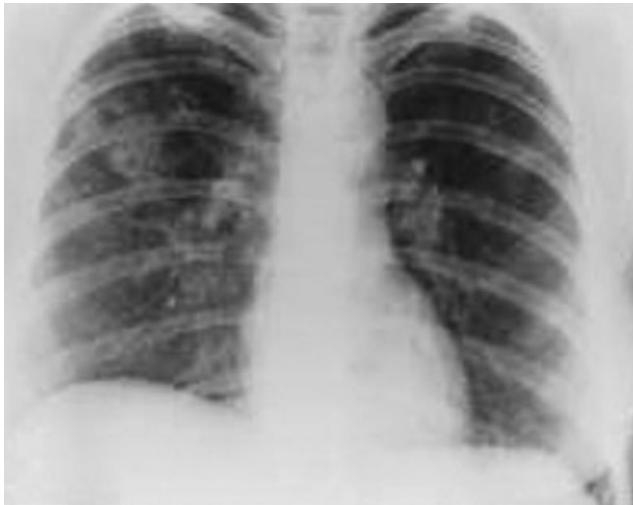### Etiology and pathogenesis

Although the etiology of sarcoidosis is unknown, genetic, infectious and environmental factors have been postulated as possible causes. The recent progress in epidemiological and laboratory studies in sarcoidosis has considerably narrowed down the field of probable causes (Moller and Chen, 2002). A putative genetic pathogenesis has been suggested due to the presence of familial clusters in sarcoidosis (Rybicki *et al*, 1996). In addition, positive association with HLA-A1, HLA-B8 and HLA-DR3 has been identified. Studies confirm a genetic predisposition for sarcoidosis and presents evidence for the allelic variation at the HLA-DRB1 locus as a major contributor (Rossman *et al*, 2003). The genetic variations that promote susceptibility to the disease may reside in loci that influence the immune response (English *et al*, 2001).

Infectious agents such as mycobacterium, propionobacteria, Epstein–Barr virus (EBV), and human herpes virus-8 (HHV-8) have been considered as possible etiological agents but so far the scientific results have been inconsistent and inconclusive (Richter *et al*, 1996; Kon and du Bois, 1997; Popper *et al*, 1997; Vokurka *et al*, 1997; English *et al*, 2001; Moller and Chen, 2002). Similarly, environmental factors (wood dust, pollen, clay, mold, silica) and occupational exposure (farmers, fire fighters, military) have been suggested as etiological agents. The possible role of these agents was explored in a randomized age, gender and race matched case–control study (Moller and Chen, 2002). Preliminary results from this study showed a positive association of sarcoidosis with environmental exposure to mold, musty odors and workers in agriculture,

insecticides and pesticides. There was a negative association with animal dusts and tobacco smoking, and no association with wood dust, pine pollen, silica, metals, and health care workers and the evidence was inconclusive in fire fighters and military personnel (ACCESS Research Group, 1999; Moller and Chen, 2002).

Reported evidence indicates an immunological response resulting from one or a combination of factors mentioned above. The T-helper 1 (Th1) lymphocytes play a central role (Moller and Chen, 2002) in granuloma formation, which is thought to be the result of deposition of poorly soluble antigenic material in the tissue. This antigenic material is taken up by antigen presenting cells such as macrophages or dendritic cells, which then expose it to T-lymphocytes. In response to these antigens, a local amplification of the cellular immune reaction takes place. In addition, mononuclear phagocytes and other inflammatory cells migrate to the site of the antigenic deposition under the influence of the chemokines and cytokines produced by Th1 cells. This results in the formation of a granuloma (English *et al*, 2001; Moller, 2003).



**Figure 1** Posterior–anterior view of the chest X-ray shows bilateral hilar lymphadenopathy and cavities in a patient with sarcoidosis

## Clinical features

Sarcoidosis is a multiorgan disorder. The clinical symptoms depend on the ethnicity, chronicity of illness, site and extent of involvement of the organ and activity of the granulomas (Wilcox *et al*, 2000). One-third of the patients with sarcoidosis can present with non-specific constitutional symptoms such as fever, fatigue, malaise or weight loss (English *et al*, 2001). The most common presentation of sarcoidosis consists of pulmonary infiltration and hilar lymphadenopathy (Figure 1), dermal, and ocular lesions (Hunninghake *et al*, 1999). The organ involvement and their clinical features are summarized in Table 1.

## Diagnosis

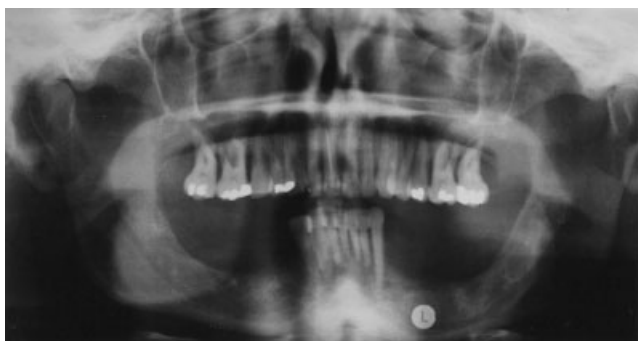Sarcoidosis is a diagnosis of exclusion. No diagnostic tests or specific markers have been established yet (Muller-Quernheim, 1998; Hunninghake *et al*, 1999). The diagnosis is based upon history (occupational or environmental exposure), pulmonary function tests (forced expiratory volume, vital capacity), haematology (complete blood count, erythrocyte sedimentation rate), biochemical investigations (liver and renal function tests, serum calcium, and serum angiotensin converting enzyme levels), chest radiograph, and histological studies.

Pulmonary function tests including forced expiratory volume, vital capacity and diffusing capacity are all diminished. Haematological and biochemical tests may show anemia, lymphocytopenia, elevated ESR, increased liver enzymes, hypercalcemia and hypercalcemic nephropathy (Rizzato, 1998; Johns and Michelle, 1999). The serum angiotensin converting enzyme (ACE) level is elevated in 50–80% of patients with sarcoidosis (Turton *et al*, 1979; Khan *et al*, 1998). It is useful in monitoring the disease progression and effectiveness of therapy (DeRemece and Rohrbach, 1980). When serum ACE is used to diagnose sarcoidosis, it has a 10% false positive and a 40% false negative rate. The ACE level is also elevated in diabetes mellitus, cirrhosis, leprosy and many other conditions. Therefore, ACE level has to be used as an adjunct, and a clinical correlation must be made for a specific diagnosis and disease progression or remission of sarcoidosis (English *et al*, 2001) (Figs 2 and 3).

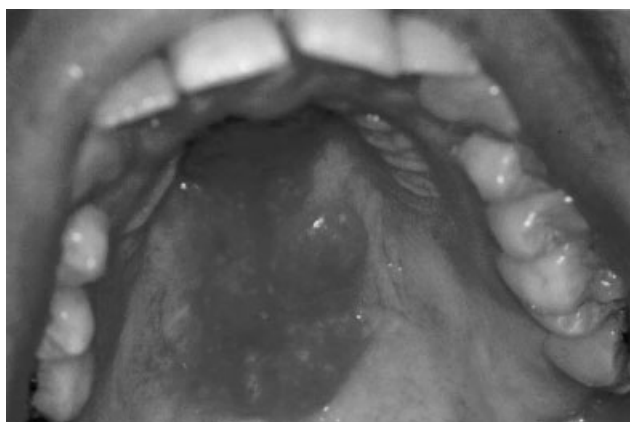
**Table 1** Organ involvement in sarcoidosis

Organs	Frequency (%)	Signs and symptoms
Lung/lymphnode	90	Dry cough, dyspnea, Lofgren syndrome
Liver/spleen	50–80	Hepatosplenomegaly, abnormal liver function
Eyes	50	Uveitis, iritis, photophobia, dry eyes
Bone and marrow	40	Osteolytic lesions
Skin	25	Indurated purple plaques (lupus pernio), erythema nodosum
Heart/nerves	5–10	Cardiac arrhythmias, congestive heart failure facial nerve palsy
Parotid gland	4–6	Parotitis, Herefordt syndrome

Lofgren syndrome: bilateral hilar lymphadenopathy with erythema nodosum; Herefordt syndrome: uveoparotitis and facial palsy.



**Figure 2** Panoramic radiograph showing generalized severe alveolar bone resorption in both maxilla and mandible of a patient with sarcoidosis



**Figure 3** Submucosal swelling on the palate in a patient with sarcoidosis

Depending on the involvement of the lungs and the lymph nodes, sarcoidosis in the chest radiographs may be staged as follows (Johns and Michelle, 1999):

Stage 0: Normal chest radiograph.

Stage I: Bilateral hilar lymphadenopathy without pulmonary infiltrates.

Stage II: Bilateral hilar lymphadenopathy with pulmonary infiltrates.

Stage III: Pulmonary infiltrates without hilar lymphadenopathy.

Stage IV: End-stage fibrosis, cystic cavities, and honeycombing.

Biopsy of the involved tissues is helpful in the diagnosis of sarcoidosis. The histology of sarcoidosis will show non-caseating granulomas (Figure 4A). The center of the granulomas usually contains epithelioid macrophages surrounded by a rim of lymphocytes (Gal and Koss, 2002). Occasional multinucleated Langhans type giant cells are also seen (Figure 4B). The giant cells result from the fusion of the epithelioid mononuclear cells and may occasionally contain many inclusion bodies such as Schumann bodies or stellate asteroid bodies (Black and Epstein, 1974; Elgart, 1986; Gal and Koss, 2002). Schumann bodies are basophilic, calcified, and laminated bodies derived from lysosomes found in

about 48–88% of sarcoidosis patients (Sheffield, 1997). Stellate or asteroid bodies are found in 2–9% of the cases. They are spiculated in shape and represent entrapped collagen (Elgart, 1986). Some lymph nodes may contain distinctive small yellow brown bodies measuring 1–15  $\mu\text{m}$  in the sub-capsular sinus called Hamazaki–Wessenberg bodies. They represent large lysosomes and stain black with methamine silver and red with periodic acid-Schiff stain (Gal and Koss, 2002). The histological findings are not specific to sarcoidosis and may be found in other infectious granulomatous disorders. Nevertheless, the findings should raise the suspicion of sarcoidosis.

Skeletal involvement shows lytic lesions with tunneling of the involved bone, which is best, assessed by gallium bone scan (Rizzato, 1998) and positron emission tomography (PET scan), but these tests are expensive.

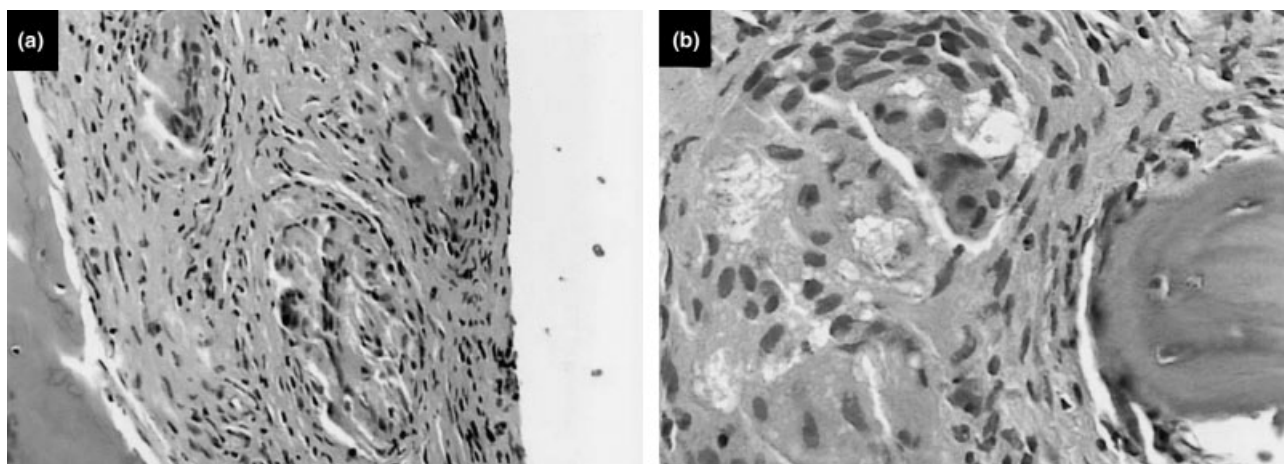
A test of historical value, but no longer used because of its low specificity and sensitivity, is the Kveim–Slitzbach test. This test involved the intradermal injection of a spleen extract from a known sarcoid lesion. Patient with sarcoidosis developed a nodule in 4–6 weeks. The biopsy of the nodule was done to confirm the diagnosis (Hong and Farish, 2000). This test is no longer employed due to the concerns regarding transmission of spongiform encephalopathy diseases (Ho and Blair, 2003).

## Treatment

Treatment is not required for all patients with sarcoidosis. The American Thoracic Society, European Respiratory Society and World Association of Sarcoidosis and Other Granulomatous Disorders (ATS/ERS/WASOG) have identified several specific conditions, which require treatment (Hunninghake *et al*, 1999). These include the sarcoidosis of the heart and nerves, hypercalcemia, and ocular involvement that do not respond to local therapy. Asymptomatic pulmonary involvement does not require treatment, while treatment is indicated in symptomatic pulmonary sarcoidosis with worsening pulmonary function tests (Baughman and Lynch, 2003).

Corticosteroids have remained as the mainstay in the treatment of sarcoidosis. Randomised controlled trials by the British Thoracic Society have found that corticosteroid therapy is superior to no treatment (Gibson *et al*, 1996) and a recent meta-analysis has confirmed these findings (Paramothayan and Jones, 2002). A major problem in treatment of sarcoidosis patients is relapse (Baughman and Lower, 1998). More than 70% of patients treated with corticosteroids relapsed within a 2 year period (Gottlieb *et al*, 1997).

Antimalarial drugs such as chloroquine and hydroxychloroquine have been particularly useful in the treatment of cutaneous and mucosal sarcoidosis, including sinus and laryngeal sarcoidosis (Johns and Michelle, 1999). They are used in combination with low dose corticosteroids. Ocular and hepatic toxicity is associated with chloroquine, therefore, periodic eye examination and monitoring liver function are recommended (Baughman and Lynch, 2003).



**Figure 4** Biopsy of a mandibular intraosseous lesion in a patient with sarcoidosis. (a) Three non-caseating granulomas with typical epithelioid macrophage and multinucleated giant cells are seen amidst a dense fibrous connective tissue stroma containing interspersed fibroblasts and scattered lymphocytes. In addition, a fragment of vital trabecular woven bone is seen (H & E stain, original magnification 200x). (b) Higher magnification of another microscopic field shows the presence of multinucleated giant cells exhibiting Schumann's bodies (altered lysosomes). This cluster of giant cells and epithelioid macrophages constitute the typical non-caseating granulomas observed in sarcoidosis (H& E stain, original magnification 400x)

Immunosuppressant drugs such as methotrexate, cyclophosphamide and azathioprine have been shown to be beneficial in the treatment of sarcoidosis. These drugs should be used with caution for their adverse side effects. Drugs inhibiting TNF-alpha such as etanercept, infliximab, pentoxifylline and thalidomide have also shown promise in the treatment of sarcoidosis, but more controlled clinical trials are necessary to show their effectiveness (Moller, 2003).

### Oral sarcoidosis

Oral involvement in sarcoidosis is uncommon. Schroff (1942) reported the first suspected case of sarcoid granulomas in the oral mucosa, but Poe (1943) reported the first confirmed case of sarcoidosis affecting the oral cavity in the mandible. Since then, to our knowledge, there have been only 68 well-documented cases of oral sarcoidosis reported in English literature (Table 4).

Most of the oral sarcoidosis cases reported in the English literature exist as single or multiple case reports. Only the cases from the English literature with confirmed histopathology from the oral lesions were included in this review. Cases without confirmed histopathology from the oral lesions and the cases involving the parotid glands and lymph nodes of the head and neck area were excluded. Cases showing sarcoid granulomas from lip or palatal biopsies from otherwise normal looking oral mucosa with no clinical manifestations in the oral cavity were also excluded.

Of the data available for the 68 cases reported in the literature, 39 cases were female, 25 were male (female to male ratio of 1.5/1), and no data was available for four cases. There was slight racial predilection to Caucasians (26 whites, 23 blacks, three Asian, one Hispanic and 15 no data available). The ages ranged from 5 to 72 years (median = 37 years).

**Table 2** Oral involvement in sarcoidosis

Location	Number of cases	Treatment
Jaw bones	21	Curettage, systemic steroids, surgery, splinting, no Tx,
Buccal mucosa	13	Surgical excision, irradiation
Gingiva	10	Systemic steroids
Lips	6	Surgical excision, steroids
Floor of the mouth/ sublingual gland	5	Surgical excision
Tongue	5	Surgical excision
Palate	3	Surgical excision, steroids
Multiple oral involvement	3	Steroids
Sub mandibular gland	2	Minocycline, no Tx

The soft tissues of the oral cavity were affected in 47 cases and the jaw bones in 21 cases (Table 2). In the soft tissues of the oral cavity buccal mucosa was the commonest site affected with 13 cases followed by gingiva (10), lips (six), floor of the mouth/sublingual gland (five), tongue (five), palate (three), submandibular gland (two) and multiple oral site involvement (two) (Table 2). The common clinical presentations were as localized swelling or nodules in (34 cases), ulcers (four cases), swelling with multiple ulcers (two cases), gingivitis (three cases), gingival hyperplasia (three cases) and gingival recession (one case) (Table 4).

The jaw bones were involved in 21 cases (nine maxilla and eight mandible and four in both maxilla and mandible). A slightly higher number of cases occurred in the anterior maxilla (seven of nine cases), and in the posterior mandible (six of eight cases) (Table 4). Clinical manifestations when jaw bone was involved were mainly due to the lytic and permeative lesions in the bone and included loose teeth (seven cases), pain radiating to the ears, (six cases), nasal obstruction (one case), swelling of

**Table 3** Intraosseous jaw sarcoidosis

<i>Author and year</i>	<i>Age</i>	<i>Race/sex</i>	<i>Chief complaint</i>	<i>Location</i>	<i>Management</i>
Poe (1943)	41	B/F	Pain of left ear	Posterior mandible	NA
Kalman and Mallett (1954)	54	W/F	Pain/lump	Anterior maxilla	Curettage
MacDonald <i>et al</i> (1985)	45	W/F	Pain	Anterior mandible	Exploration
Van Swol (1973)	22	B/F	Loose teeth	Maxilla/mandible	N/A
Thomas <i>et al</i> (1976)	30	B/M	Pain of TMJ	Right TMJ	Steroids
Hillerup (1976)	22	N/A	Mandibular lesion	Posterior mandible	Curettage
Betten and Koppang, 1976	49	W/M	None	Posterior mandible	Curettage
Schwartz (1981)	29	W/F	Pain of TMJ	Mandible condyle	Condylectomy
Cohen <i>et al</i> (1981)	35	W/F	Swelling mandible	Maxilla/mandible	Remission
Aragon <i>et al</i> (1982)	25	B/F	Pain of gums	Anterior maxilla	Extraction
Cohen and Reinhardt (1982)	59	W/F	Non-healing socket	Posterior mandible	Curettage
Makris and Stoller (1983)	27	B/F	None	Maxilla/mandible	N/A
Verheijen-Breemhaar <i>et al</i> (1987)	28	NA/F	Loose teeth	Anterior maxilla	Extraction
Hildebrand <i>et al</i> (1990)	41	B/M	Nasal obstruction	Anterior maxilla	Steroids
Rubin <i>et al</i> (1991)	25	B/F	None	Anterior maxilla	NA
Klesper <i>et al</i> (1994)	16	W/F	Loose teeth	Posterior maxilla	Steroids
Clayman <i>et al</i> (1998)	35	B/F	Loose teeth	Anterior maxilla	NA
Hong and Farish (2000)	40	B/M	Loose teeth	Anterior maxilla	Steroids
White and Crocker (2000)	37	W /M	Maxillary bone loss	Posterior maxilla	Remission
Krajekian <i>et al</i> (2002)	31	W/M	Loose teeth	Posterior mandible	Surgery and Steroids
Suresh <i>et al</i> (2003)	46	W/M	Loose teeth	Maxilla/mandible	Steroids

NA, not available; B, black; W, white; F, female; M, male.

the mandible (one case), maxillary bone loss (one case), and non-healing socket (one case). Three other cases did not report the symptoms (Table 3). Oral lesions were the first manifestation of the systemic sarcoidosis in 24 cases.

Parotid gland involvement occurs in 6% of patients with sarcoidosis. The gland involvement is usually bilateral and is slightly more common in women (James and Sharma, 2000). Submandibular and sublingual glands involvement is less common than parotid gland involvement (Narang and Dixon, 1975; Mandel and Kaynar, 1994). Clinical presentation of sarcoidosis in major salivary glands is usually as painless firm swellings, and fluctuation in the size does not occur during the meal time. Xerostomia may also be present (Mandel and Kaynar, 1994). Other rare but pathognomonic presentation of glandular involvement is Heerfordt syndrome. This syndrome is defined as systemic sarcoidosis characterized by parotitis (usually bilateral), uveitis, and facial nerve paralysis (James and Sharma, 2000).

The involvement of the minor salivary glands in the oral cavity in sarcoidosis may be much higher than previously reported. When palatal or labial salivary glands from clinically normal mucosa in sarcoidosis patients were biopsied, the rate of involvement ranged from 19% (Giotaki *et al*, 1986) to 58% (Nessan and Jacoway, 1979). It is possible that some of the swellings seen on the mucosa of patients with sarcoidosis, are actually expansions of localized involved minor salivary glands. The exact number of minor salivary gland involvement is not known, but it is possible that if it is extensive, it may contribute to xerostomia. In the presence of xerostomia, in a patient with sarcoidosis, minor salivary gland biopsy may be useful in differentiating sarcoidosis from Sjögren's syndrome (Drosos *et al*, 1989).

The differential diagnosis for oral sarcoidosis found on biopsy in the oral cavity is orofacial granulomatosis

(OFG) which encompasses a group of related conditions affecting the oral and maxillofacial region, characterized by the presence of non-specific granulomatous inflammation (Wiesenfeld *et al*, 1985; Sciubba and Said-Al-Naief, 2003). Orofacial granulomatosis includes bacterial infections (tuberculosis, syphilis, cat-scratch disease and leprosy), fungal infections (histoplasmosis, coccidioidomycosis), foreign body granulomas and Crohn's disease (Sciubba and Said-Al-Naief, 2003). Clinical history, additional haematology and biochemical tests in combination with specific histochemical stains will help in a precise diagnosis. Medical history has to be evaluated and the patient has to be referred to a physician for possible a systemic involvement.

In a literature search for treatment of oral sarcoidosis, we found data for only 49 of the patients (Tables 3 and 4). Multiple methods were employed in the treatment of oral sarcoidosis ranging from no treatment (Cohen *et al*, 1981; Hayter and Robertson, 1988) to radiation therapy (Hoggins and Allan, 1969). Surgical excision and curettage (Narang and Dixon, 1975; Betten and Koppang, 1976; Hillerup, 1976; Schwartz, 1981) was the most commonly employed treatment, followed by steroids (MacLeod *et al*, 1985; Nagata *et al*, 1999). Oxygen therapy (Orlean and O'Brien, 1966) was also reported. Corticosteroids and other drugs were needed in only 18 of the patients. From the review, we conclude that sarcoidosis presenting in oral cavity as localized swellings may be treated with simple surgical excisions. Presentations as gingival hyperplasia and gingivitis may be controlled by scaling, polishing and strict good oral hygiene. Jaw lesions should be curetted and the mobile tooth splinted. Corticosteroids should only be considered in the painful and progressive lesions in consultation with the patient's physician.

**Table 4** Sarcoidosis of the oral soft tissues

<i>Author and year</i>	<i>Age</i>	<i>Race/sex</i>	<i>Chief complaint</i>	<i>Management</i>
<i>Buccal mucosa</i>				
Schroff (1942)	48	W/F	Swelling	NA
Campbell (1944)	72	-/M	Loose denture	Biopsy and resolution
Kolas and Roche (1960)	15	W/M	Multiple lumps	Steroids
Hobkirk (1969)	30	-/M	Pain	NA
Hoggins and Allan (1969)	45	-/F	Swelling	Surgery/radiation
Gold and Sager (1976)	-	-	Pain	NA
Greet and Sanget (1977)	37	W/F	Swelling	No treatment
Orlian and Birnbaum (1980)	43	W/F	Swelling	Surgery
DeLuke and Scuibba (1985)	35	B/F	Swelling	Steroids
Klesper <i>et al</i> (1994)	16	W/F	Swelling	NA
Blinder <i>et al</i> (1997)	43	W/F	Swelling	No treatment
	62	W/F	Nodules	No treatment
Piatttelli <i>et al</i> (1998)	44	-	Ulcer	NA
<i>Gingiva</i>				
Tillman <i>et al</i> (1966)	18	W/F	Gingivitis	Died
Watts (1968)	42	-/F	Hyperplasia	Steroids
Hogan (1983)	37	-/F	Swollen gingival	Spontaneous remission
Sloan <i>et al</i> (1983)	16	W/M	Hyperplasia	Excision
Altman and Robinson (1984)	36	W/M	Hyperplasia	Steroids
Zakrzewska and Nally (1985) (two cases)	30	W/F	Gingivitis	NA
	33	W/M	Gingivitis	NA
Hayter and Robertson (1988)	34	-/M	Ulcers	No treatment
Caudill (1988)	57	W/F	Gingival recession	Surgery
<i>Palate</i>				
Cohen <i>et al</i> (1981)	40	B/F	Multiple nodules	No treatment
Van Maarsseveen <i>et al</i> (1982)	23	-/M	Multiple nodules	No treatment
Hildebrand <i>et al</i> (1990)	36	B/M	Papule	Steroids
Ho and Blair (2003)	58	B/F	Gingival redness	No treatment
<i>Labial mucosa</i>				
Calderon <i>et al</i> (1990)	28	W/F	Nodules	Steroids
Bourgeois-Droin <i>et al</i> (1993) (two cases)	10	B/F	Swelling	NA
	5	B/M	Swelling	NA
Steinberg and Mueller (1994) (two cases)	37	B/M	Nodules	Steroids
	28	B/F	Nodules	Surgery
Piatttelli <i>et al</i> (1998)	54	-/M	Ulcer and swelling	NA
<i>Tongue</i>				
Tillman <i>et al</i> (1966)	37	B/M	Swelling	Surgery
Van Maarsseveen <i>et al</i> (1982)	69	-/F	Nodule	No treatment
MacLeod <i>et al</i> (1985)	30	W/F	Swelling	Steroid
Mendelsohn <i>et al</i> (1992)	43	-/M	Swelling	NA
Soto <i>et al</i> (1997)	56	W/F	Swelling	Steroids
<i>Floor of mouth/sublingual gland</i>				
Orlean and O'Brien (1966)	33	B/M	Swelling	Oxygen
Roche <i>et al</i> (1967)	24	B/M	Swelling	NA
Narang and Dixon (1975)	26	B/M	Swelling	Surgical
Takimoto <i>et al</i> (1989)	26	A/F	Swelling	Surgery
Vijay <i>et al</i> (1995)	44	B/F	Swelling	Surgery/steroids
<i>Multiple sites</i>				
Covel (1954)	26	-/F	Multiple ulcers	NA
Zakrzewska and Nally (1985)	33	B/-	Multiple ulcers	NA
Nagata <i>et al</i> (1999)	32	A/F	Ulcers/swelling	Steroids
<i>Submandibular gland</i>				
Mandel and Kaynar (1994)	42	H/F	Bilateral swelling	No treatment
Ohtsuka <i>et al</i> (2001)	63	A/M	Bilateral swelling	Minocycline

F, female; M, male; W, white; B, black; A, Asian; H, Hispanic; NA, not available.

## Conclusion

Sarcoidosis is a relatively common disease but its oral manifestations are relatively uncommon. Oral lesions

may be the initial manifestation of the disease. Suspected cases of oral sarcoidosis should be biopsied and also be referred to a physician to rule out other systemic involvement.

## References

- ACCESS Research Group (1999). Design of a case control etiologic study of sarcoidosis (ACCESS). *J Clin Epidemiol* **52**: 1173–1186.
- Altman K, Robinson PD (1984). Sarcoidosis with oral involvement. *Br Dent J* **157**: 310–311.
- Aragon SB, Coke JM, Greer RO (1982). Sarcoidosis with involvement of maxilla. *J Oral Med* **37**: 52–57.
- Baughman RP, Lower EE (1998). Treatment of sarcoidosis with corticosteroids: who is going to relapse and why? *Sarcoidosis* **15**: 19–20.
- Baughman RP, Lynch JP (2003). Difficult treatment issues in sarcoidosis. *J Intern Med* **253**: 41–45.
- Betten B, Koppang HS (1976). Sarcoidosis with mandibular involvement: report of a case. *Oral Surg Oral Med Oral Pathol* **42**: 731–737.
- Black MM, Epstein WL (1974). Formation and properties of multinucleate giant cells in organized cell granulomas. *Am J Pathol* **74**: 263–270.
- Blinder D, Yahatom R, Taicher S (1997). Oral manifestations of sarcoidosis. *Oral Surg Oral Med Oral Pathol Oral Radiol Endod* **83**: 458–461.
- Bourgeois-Droin C, Havard S, Granier F *et al* (1993). Granulomatous cheilitis in two children with sarcoidosis by lip biopsy of minor salivary glands. *J Am Acad Dermatol* **29**: 822–824.
- Calderon S, Anavi Y, Mazar A *et al* (1990). Sarcoidosis with oral involvement. *Ann Dent* **49**: 21–24.
- Campbell J (1944). Sarcoidosis or tuberculosis. *Br Dent J* **77**: 159–163.
- Caudill RF (1988). Sarcoidosis of the gingiva: an elusive diagnosis. *J Periodont Rest Dent* **2**: 67–74.
- Chesnutt AN (1995). Enigmas in sarcoidosis. *West J Med* **162**: 519–526.
- Clayman L, MacLennan M, Dolan RL (1998). Nonpainful swelling of the palate and loosening of the maxillary incisors. *J Oral Maxillofac Surg* **56**: 1327–1335.
- Cohen DM, Reinhardt RA (1982). Systemic sarcoidosis presenting with horner's syndrome and mandibular paresthesia. *Oral Surg Oral Med Oral Pathol* **53**: 577–581.
- Cohen C, Krutchkoff D, Eisenberg E (1981). Systemic sarcoidosis: report of two cases with oral lesions. *J Oral Surg* **39**: 613–618.
- Covel E (1954). Boeck's sarcoid of the mucous membrane: report of a case. *Oral Surg Oral Med Oral Pathol* **7**: 1242–1244.
- DeLuke DM, Scuibba JJ (1985). Systemic sarcoidosis presenting with Horner's syndrome and mandibular paresthesia. *Oral Surg Oral Med Oral Pathol* **59**: 184–188.
- DeRemee RA, Rohrbach MS (1980). Serum angiotensin converting enzyme in evaluating the clinical course of sarcoidosis. *Ann Intern Med* **92**: 747–756.
- Drosos AA, Constantopoulos SH, Psychos *et al* (1989). The forgotten cause of sicca complex; sarcoidosis. *J Rheumatol* **16**: 1548–1551.
- Elgart ML (1986). Cutaneous sarcoidosis: definitions and types of lesions. *Clin Dermatol* **4**: 35–45.
- English JC, Patel P, Greer K (2001). Sarcoidosis. *J Am Acad Dermatol* **44**: 725–746.
- Fite E, Alsina JM, Mana J *et al* (1996). Epidemiology of sarcoidosis in catalonia: 1979–1989. *Sarcoidosis Vasc Diffuse Lung Dis* **13**: 153–158.
- Gal A, Koss MN (2002). The pathology of sarcoidosis. *Curr Opin Pulm Med* **8**: 445–451.
- Gibson GJ, Prescott RJ, Muers MF *et al* (1996). British Thoracic Society Sarcoidosis study: effects of long-term corticosteroid treatment. *Thorax* **51**: 238–247.
- Giotaki H, Constantopoulos SH, Papadimitriou CS *et al* (1986). Labial minor salivary gland biopsy: a highly discriminatory diagnostic method between sarcoidosis and Sjogrens syndrome. *Respiration* **50**: 102–107.
- Gold RS, Sager E (1976). Oral sarcoidosis: a review of literature. *J Oral Surg* **34**: 237–244.
- Gottlieb JE, Isreal HL, Steiner RM *et al* (1997). Outcome in sarcoidosis. The relationship of relapse to corticosteroid therapy. *Chest* **111**: 623–631.
- Greet RO Jr, Sanget RG (1977). Primary Intra oral sarcoidosis. *J Oral Surg* **35**: 507–509.
- Hayter JP, Robertson JM (1988). Sarcoidosis presenting as gingivitis. *Br Med J* **296**: 504.
- Hildebrand J, Plezia RA, Rao SB (1990). Sarcoidosis report of two cases with oral involvement. *Oral Surg Oral Med Oral Pathol* **69**: 217–222.
- Hillerdal G, Nou E, Osterman K *et al* (1984). Sarcoidosis: epidemiology and prognosis. A 15- year old European study. *Am Rev Respir Dis* **130**: 29–32.
- Hillerup S (1976). Diagnosis of sarcoidosis from oral manifestation. *Int J Oral Surg* **5**: 95–99.
- Ho K, Blair F (2003). Sarcoidosis of gingival – a case report. *Dent Update* **30**: 264–268.
- Hobkirk JA (1969). Sarcoidosis with oral lesions: report of a case. *J Oral Surg* **27**: 891–894.
- Hogan JJ (1983). Sarcoid gingivitis. *Br Dent J* **154**: 109–110.
- Hoggins GS, Allan D (1969). Sarcoidosis of the maxillary region. *Oral Surg Oral Med Oral Pathol* **28**: 623–627.
- Hong J, Farish SE (2000). Intraosseous sarcoidosis of maxilla: case report. *J Oral Maxillofac Surg* **58**: 435–439.
- Hosoda Y, Yamaguchi M, Hiraga Y (1997). Global epidemiology of sarcoidosis. What story do prevalence and incidence tell us. *Clin Chest Med* **18**: 681–694.
- Hunninghake GW, Costabel U, Ando M *et al* (1999). ATS/ERS/WASOG statement sarcoidosis. American thoracic society/European respiratory society/World association of sarcoidosis and other granulomatous disorders. *Sarcoidosis Vasc Diffuse Lung Dis* **16**: 149–173.
- James DG (1992). Epidemiology of sarcoidosis. *Sarcoidosis* **9**: 79–87.
- James DG (1997). Descriptive definition and historic aspects of sarcoidosis. *Clin Chest Med* **18**: 663–679.
- James DG, Sharma OP (2000). Parotid gland sarcoidosis. *Sarcoidosis Vasc Diffuse Lung Dis* **17**: 27–32.
- Johns CJ, Michelle TM (1999). The clinical management of sarcoidosis: a 50-year experience at Johns Hopkins hospital. *Medicine* **78**: 65–111.
- Kalman SI, Mallett SP (1954). Aberrant gland and sarcoidosis in the maxillae: report of case. *J Oral Surg* **12**: 63–66.
- Khan AH, Ghani F, Khan MA *et al* (1998). Role of serum angiotensin converting enzyme in sarcoidosis. *J PMA* **48**: 131–133.
- Klesper B, Schmelzle R, Donath K (1994). Cutaneous manifestation of sarcoidosis (Boeck) with severe osseous destruction of the midface. *J Craniomax Surg* **22**: 163–166.
- Kolas S, Roche WC (1960). Sarcoidosis lesions primary in the oral cavity: report of a case. *J Oral Surg* **18**: 169–172.
- Kon OM, du Bois RM (1997). Mycobacteria and sarcoidosis. *Thorax* **52**(Suppl. 3): S47–S51.
- Krajekian J, Goode R, Papageorge MB (2002). Mandibular sarcoidosis: case presentation. *J Mass Dent Soc* **51**: 52–55.
- MacDonald DG, Rowan RM, Blair GS (1985). Sarcoidosis involving the mandible a case report. *Br Dent J* **126**: 168–171.
- MacLeod RI, Snow MH, Hawkesford JE (1985). Sarcoidosis of the tongue: a case report. *Br J Oral Maxillofac Surg* **23**: 243–246.

- Makris GP, Stoller NH (1983). Rapidly advancing periodontitis in a patient with sarcoidosis a case report. *J Periodontol* **54**: 690–693.
- Mandel L, Kaynar A (1994). Sialadenopathy: a clinical herald of sarcoidosis. *J Oral Maxillofac Surg* **52**: 1208–1210.
- Mendelsohn SS, Field EA, Woolgar JA (1992). Sarcoidosis of the tongue. *Clin Exp Dermatol* **17**: 47–48.
- Moller DR (2003). Treatment of sarcoidosis—from a basic science point of view. *J Intern Med* **253**: 31–40.
- Moller DR, Chen ES (2002). What causes sarcoidosis. *Curr Opin Pulm Med* **8**: 429–434.
- Muller-Quernheim J (1998). Serum markers for the staging of the disease activity of sarcoidosis and other interstitial lung diseases of unknown etiology. *Sarcoidosis Vasc Diffuse Lung Dis* **15**: 22–37.
- Nagata Y, Kanekura T, Kawabata H *et al* (1999). A case of sarcoidosis involving the tongue. *J Dermatol* **26**: 666–670.
- Narang R, Dixon RA Jr (1975). Sarcoidosis and ranula of sublingual gland. *Oral Surg Oral Med Oral Pathol* **39**: 376–381.
- Nessan VJ, Jacoway JR (1979). Biopsy of minor salivary glands in the diagnosis of sarcoidosis. *N Engl J Med* **301**: 922–924.
- Ohtsuka S, Yanadori A, Tabata H *et al* (2001). Sarcoidosis with giant parotomegaly. *Cutis* **68**: 199–200.
- Orlean SL, O'Brien JJ (1966). Sarcoidosis manifesting a soft lesion in the floor of the mouth: a case report. *Oral Surg Oral Med Oral Pathol* **21**: 819–823.
- Orlian AI, Birnbaum M (1980). Intraoral localized sarcoid lesion. *Oral Surg Oral Med Oral Pathol* **49**: 341–343.
- Paramothayan S, Jones PW (2002). Corticosteroid therapy in pulmonary sarcoidosis: a systemic review. *JAMA* **287**: 1301–1307.
- Piattelli A, Favia GF, Di Alberti L (1998). Oral ulceration as a presenting sign of unknown sarcoidosis mimicking a tumour: report of 2 cases. *Oral Oncol* **34**: 427–430.
- Poe DL (1943). Sarcoidosis of the jaw – a new disease of the mandible. *Am J Orthod* **29**: 52–56.
- Popper HH, Klemen H, Hoefler G *et al* (1997). Presence of mycobacterial DNA in sarcoidosis. *Hum Pathol* **28**: 796–800.
- Reich JM, Johnson R (1996). Incidence of clinically identified sarcoidosis in a northwest United States population. *Sarcoidosis Vasc Diffuse Lung Dis* **13**: 173–177.
- Richter E, Greinert U, Kirsten D *et al* (1996). Assessment of mycobacterial DNA in cells and tissues of mycobacterial and sarcoid lesions. *Am J Respir Crit Care Med* **153**: 375–380.
- Rizzato G, Montemurro L, Colombo P (1998). The late follow-up of chronic sarcoid patients previously treated with corticosteroids. *Sarcoidosis* **15**: 52–58.
- Roche WC, Morris CR, Nemickas R (1967). Sarcoidosis of sublingual glands: a case report. *J Oral Surg* **25**: 77–79.
- Rossmann MD, Thompson B, Frederick M *et al* (2003). HLA-DRB1\*1101: a significant risk factor for sarcoidosis in blacks and whites. *Am J Hum Genet* **73**: 720–735.
- Rubin MM, Ross SJ, Pliskin A (1991). Maxillary alveolar bone loss in a patient with sarcoidosis. *J Oral Maxillofac Surg* **49**: 1351–1353.
- Rybicki BA, Harrington D, Major M *et al* (1996). Heterogeneity of familial risk in sarcoidosis. *Genet Epidemiol* **13**: 23–33.
- Schroff J (1942). Sarcoid of the face (Besnier–Boeck–Schumann) disease: report of a case. *JADA* **29**: 2208–2211.
- Schwartz HC (1981). Sarcoid temporomandibular arthritis. *Oral Surg Oral Med Oral Pathol* **52**: 588–590.
- Sciubba JJ, Said-Al-Naief N (2003). Orofacial granulomatosis: presentation, pathology and management of 13 cases. *J Oral Pathol Med* **32**: 576–585.
- Sheffield EA (1997). Pathology of sarcoidosis. *Clin Chest Med* **18**: 741–754.
- Sloan PJ, O'Neil TC, Smith CJ *et al* (1983). Multisystem sarcoid presenting with gingival hyperplasia. *Br J Oral Surg* **21**: 31–35.
- Soto AS, Lobo VP, Gonzalez RLM *et al* (1997). Oral sarcoidosis with tongue involvement. *Oral Surg Oral Med Oral Pathol* **83**: 668–671.
- Steinberg MJ, Mueller DP (1994). Treating oral sarcoidosis. *J Am Den Assoc* **125**: 76–79.
- Suresh L, Aguirre A, Buhite RJ, Radfar L (2003). Intraosseous sarcoidosis of the jaws mimicking aggressive periodontitis – a case report and literature review. *J Periodontol* **75**: 478–482.
- Takimoto T, Ishikawa S, Yoshizaki T *et al* (1989). Ranula and sarcoid granuloma of sublingual gland. *Auris Nasus Larynx* **16**: 39–42.
- Thomas RF, Merkow L, White NS (1976). Sarcoidosis with involvement of mandibular condyle. *J Oral Surg* **34**: 1026–1030.
- Tillman HH, Taylor RG, Carchidi JE (1966). Sarcoidosis of the tongue. *Oral Surg Oral Med Oral Pathol* **21**: 190–195.
- Turton CW, Grundy E, Firth G *et al* (1979). Value of measuring angiotensin I converting enzyme and serum lysozyme in the management of sarcoidosis. *Thorax* **34**: 57–62.
- Van Maarsseveen AC, Van der waal I, Stam J *et al* (1982). Oral involvement in sarcoidosis. *Int J Oral Surg* **11**: 21–29.
- Van Swol RL (1973). Periodontosis in a patient with previously diagnosed sarcoidosis. *J Periodontol* **44**: 697–704.
- Verheijen-Breemhaar L, De Man K, Zondervan PE *et al* (1987). Sarcoidosis with maxillary involvement. *Int J Oral Maxillofac Surg* **16**: 104–107.
- Vijay V, Newman R, Bedawi MA *et al* (1995). Sarcoid ranula: its association with wide spread sarcoidosis. *Oral Surg Oral Med Oral Pathol Oral Radiol Endod* **79**: 449–451.
- Vokurka M, Lecossier D, du Bois RM *et al* (1997). Absence of DNA from mycobacteria of the M tuberculosis complex in sarcoidosis. *Am J Respir Crit Care Med* **156**: 1000–1003.
- Watts KD (1968). Sarcoid of the gingival: a case report. *Br J Oral Surg* **6**: 108–113.
- White DR, Crocker DJ (2000). Persistent anterior maxillary bone loss. *J Oral Maxillofac Surg* **58**: 1145–1149.
- Wiesenfeld D, Ferguson MM, Mitchell DN *et al* (1985). Orofacial granulomatosis—a clinical and pathological analysis. *Q J Med* **54**: 101–113.
- Wilcox A, Bharadwaj P, Sharma OP (2000). Bone sarcoidosis. *Curr Opin Rheumatol* **12**: 321–330.
- Zakrzewska J, Nally FF (1985). Sarcoid with oral involvement. *Br Dent J* **158**: 3–4.